Beauthentic

The new language of the skin

Treatments and protocols in aesthetic medicine

PLAY SURE *doping free*

Document intended for specialists in the field

aesthetic GUNA

Global Aesthetic Medicine Market

- The **global aesthetic surgery market** is experiencing strong growth. Valued at USD 13.9 billion in 2022, it is expected to expand at an **annual compound growth rate of 11%** through 2027, reaching USD 23.4 billion.

- **Key drivers of this expansion include:** technological advancements, increased consumer spending power, more refined surgical techniques, evolving social norms with greater emphasis on aesthetics.

Aesthetic medicine treatments

Injectable treatments are the most frequent procedures in aesthetic medicine: Italy as an example

Injectables

- **Fillers:** 57-59% of women request this treatment
- **Botulinum toxin:** 44-48% of women and 39-48% of men request this treatment
- **Biorevitalization/Biostimulation (hyaluronic acid, amino acids, vitamins, polynucleotides, collagen):** 33-35% of women/men request this treatment
- **Mesotherapy:** 82.1% of women and 30% of men request this treatment
- **Chemical peels (topical use):** 22-23% of women/men request this treatment
- **PRP (Platelet-Rich Plasma)**
- **Microneedling**

Device-based

- **Fractional/ablative/diode laser:** 19% of women/men request this treatment
- **Carboxytherapy:** 73% of women and 56% of men request this treatment
- **Radiofrequency**
- **Magnetophoresis**

- **Thread lifting**

Monica Melotti. Medicina estetica, filler e botox i trattamenti più richiesti. Il Sole 24 ore. 12 October 2022. **Osservatorio Agorà 2024:** chi sono e cosa desiderano gli italiani che ricorrono alla medicina estetica - SkinChannel (Data collected from physicians registered in the Agorà Observatory across Italy; sample size varies by response domain and values are statistically adjusted). Report "Mercato dei trattamenti estetici in Italia 2025" (market value, growth rate, injectables incidence). Latest Italian market data on the boom in aesthetic medicine.

aesthetic GUNA

Hyaluronic acid-based fillers

Indications

Static wrinkles, lip volume enhancement, cheek and chin contouring, correction of nasolabial folds

Mechanism of action

Provides filling and hydration due to the hygroscopic properties of hyaluronic acid (HA)

Effect duration

6-18 months (depending on density and cross-linking degree)

Technical notes

Microcannula or needle techniques; use of cross-linked or non-cross-linked HA depending on injection depth

Hsin S, et al. Clinical Safety and Efficacy of Hyaluronic Acid-Niacinamide-Tranexamic Acid Injectable Hydrogel for Multifactorial Facial Skin Quality Enhancement with Dark Skin Lightening. Gels. 2025. **Pawar PP, et al.** Effect of hyaluronic acid dermal fillers for mid-face volume enhancement: A systematic review and meta-analysis. Bioinformation. 2025.

Botulinum toxin

Indications

Dynamic wrinkles (glabellar lines, forehead, periocular area), hyperhidrosis

Mechanism of action

Inhibits acetylcholine release at the neuromuscular junction (SNAP-25 block)

Effect duration

3-6 months

Common treatment areas

Upper third of the visage; axillary region for hyperhidrosis

Rahman E, et al. Intradermal Botulinum Toxin A on Skin Quality and Facial Rejuvenation: A Systematic Review and Meta-analysis. Plast Reconstr Surg Glob Open. 2024. **Hexsel D. et al.** Efficacy, Safety, and Subject Satisfaction After AbobotulinumtoxinA Treatment of Upper Facial Lines. Dermatol Surg. 2018.

Biorevitalization/Mesotherapy

Indications

Deep hydration, dull skin, irregular texture

Active ingredients

Lightly cross-linked or non-cross-linked hyaluronic acid, vitamins (A, C, E), amino acids, coenzymes, collagen

Protocol

2-3 initial sessions every 15-30 days + maintenance

Technique

Nappage injections, micro-wheals, or retrograde linear technique

Majewska L, et al. Facial Skin Density Enhancement Using Hyaluronic Acid-Based Bioactive Hydrogel: Cannula-Assisted Delivery and Ultrasound Evaluation in a Retrospective Controlled Study. Pharmaceutics. 2025. **Brandi C, et al.** Face Rejuvenation: a new combinated protocol for biorevitalization. Acta Biomed. 2018.

Collagen

Indications

Skin laxity, dull skin, irregular texture, skin biorevitalization, wrinkles (lips/cheeks/chin/nasolabial folds), cellulite, acne, scars, stretch marks, dark circles

Mechanism of action

Biorevitalizing, regenerative, and reparative activity; provides mechanical scaffold support to the extracellular matrix

Effect duration

6-18 months (variable depending on the initial skin condition)

Protocol

3-5 initial sessions every 15-30 days + maintenance

Technique

Nappage superficial injections, micro-wheals, mesotherapy, microcannula or needle

Gardeazabal L, Izeta A. Elastin and collagen fibres in cutaneous wound healing. Exp Dermatol. 2024. **Salvatore L, et al.** An Update on the Clinical Efficacy and Safety of Collagen Injectables for Aesthetic and Regenerative Medicine Applications. Polymers. 2023.

Chemical peels

Indications

Acne, dyschromia, superficial wrinkles, photoaging

Active ingredients

Glycolic acid, TCA, salicylic acid, mandelic acid

Depth of action

Superficial, medium, or deep (depending on concentration)

Contraindications

Sensitive skin; high phototype (increased risk of hyperpigmentation)

TCA: Trichloroacetic acid.

Soon SL. Et al. International Peeling Society; International Peeling Society. Phenol-Croton Oil Chemical Peeling Induces Durable Improvement of Constitutional Periorbital Dark Circles. Dermatol Surg. 2023. **Patel V. et al.** Role of Polyethylene Glycol in Dermatology. Indian Dermatol Online J. 2025.

PRP (Platelet-Rich Plasma)

Indications

Androgenetic alopecia, rejuvenation, scars

Technique

Blood draw followed by centrifugation → injection of platelet-rich plasma (protocols and authorizations established by each country)

Frequency

3 initial sessions + maintenance every 6 months

Mechanism of action

Release of growth factors (PDGF, TGF-β, VEGF)

PDGF: Platelet-Derived Growth Factor; TGF-β: Transforming Growth Factor Beta; VEGF: Vascular Endothelial Growth Factor.

Abedini R, et al. Randomized Controlled Trial Study to Evaluate the Efficacy of Combination Therapy with Diphenylcyclopropenone and Platelet-Rich Plasmain Alopecia Areaata. Int J Trichology. 2025.
Ahramiyanpour N, et al. Optimizing Post-Acne Scar Treatment: A Pilot Comparative Study of Endo-Radiofrequency Subcision With and Without Platelet-Rich Plasma. J Cosmet Dermatol. 2025.

Microneedling

Indications

Post-acne scars, enlarged pores, fine wrinkles, alopecia

Mechanism of action

Stimulation of neocollagenesis through controlled mechanical injury

Needle depth

0.5-2.5 mm (depending on indication)

Common associations

PRP, topical vitamins, collagen

PRP: Platelet-Rich Plasma.

Aust M, et al. Percutaneous collagen induction therapy for hand rejuvenation. Plast Reconstr Surg. 2010. **Fabbrocini G.** Microneedling: Current Applications. Dermatol Ther. 2014.

Fractional laser/IPL/RF microneedling

Indications

Resurfacing, acne scars, skin hyperpigmentation, hair removal, rosacea

Types

- Fractional CO_2 laser (ablative)
- Fractional Erbium-YAG laser
- Microneedling RF (for skin laxity and scars)
- IPL (non-ablative, polychromatic)

Treatment duration

1-4 sessions (fractional lasers); 4-8 sessions (IPL)

IPL: Intense Pulsed Light; RF: Radio Frequency.

Omi T, et al. The Role of the CO_2 Laser and Fractional CO_2 Laser in Dermatology. Laser Ther. 2014. **Sadick NS, et al.** Photorejuvenation with intense pulsed light: results of a multi-center study. J Drugs Dermatol. 2004.

Carboxytherapy

Indications

Cellulite (PEFS), localized adiposity, skin laxity, dark circles, stretch marks, venous insufficiency, and telangiectasias

Technique

Injection of CO_2 for medical purpose using very fine needles via subcutaneous or intradermal routes

Frequency

1-2 sessions per week for 6-12 sessions depending on indication (cellulite requires more sessions than dark circles)

Mechanism of action

Vasodilation and increased blood flow, lipolytic effect, collagen stimulation, and drainage effect

Shamban A, et al. Topical Carboxytherapy for Skin Rejuvenation. J Clin Aesthet Dermatol. 2025.

Thread lifting

Indications

Non-surgical facial lifting (cheeks, jawline, neck), nasolabial and marionette lines, jawline contouring

Technique

Insertion of threads using a needle-cannula into the subcutaneous layer, followed by tissue traction and anchoring of the thread (resorbable materials such as PDO, PLLA, PCL, or non-resorbable threads)

Frequency

Once every 12-18 months

Mechanism of action

Mechanical lifting combined with a biological effect: the thread material (e.g., PDO, PLLA, PCL) induces a controlled fibrotic response and stimulates the production of collagen, elastin, and hyaluronic acid

PDO: polydioxanone, PLLA: poly-L-lactic acid, PCL: polycaprolactone.

Hong GW, et al. Anatomical Consideration for Double Chin Thread Lifting. J Cosmet Dermatol. 2025.

Collagen overlapping with other active ingredients/therapies

FILLERS

1 filler injection, combined in the same session with MD-TISSUE. Continue with collagen for 2 additional sessions, once every 15 days

↓

Objective:

Improve skin quality through extracellular matrix remodeling and scaffold activity

BOTULINUM TOXIN

1 botulinum toxin session combined with 3 MD-TISSUE/MD-MATRIX injections (pre- and post-treatment)

↓

Objective:

Coadjuvant treatment to enhance skin quality

LASER

1 laser session, followed 15 days later by MD-TISSUE/MD-MATRIX injections,once every 15 days (3 injections)

↓

Objective:

Reduce inflammation and enhance tissue regeneration

Mechanism of action of MD-TISSUE

In vitro study conducted on human tenocytes obtained from fragments of the gluteus medius and gluteus minimus tendons, harvested from 8 patients undergoing total hip arthroplasty and cultured with MD-TISSUE.

MD-TISSUE collagen **stimulated tenocyte growth** at 72 hours and, **after 24 hours, demonstrated effectiveness in promoting wound healing by inducing cell migration toward the lesion site and repair of damaged tissue.**

Growth curve: Cell proliferation at **48-72 hours**, with a statistically significant increase at **72 hours** (*p < 0.05 vs 24 h).

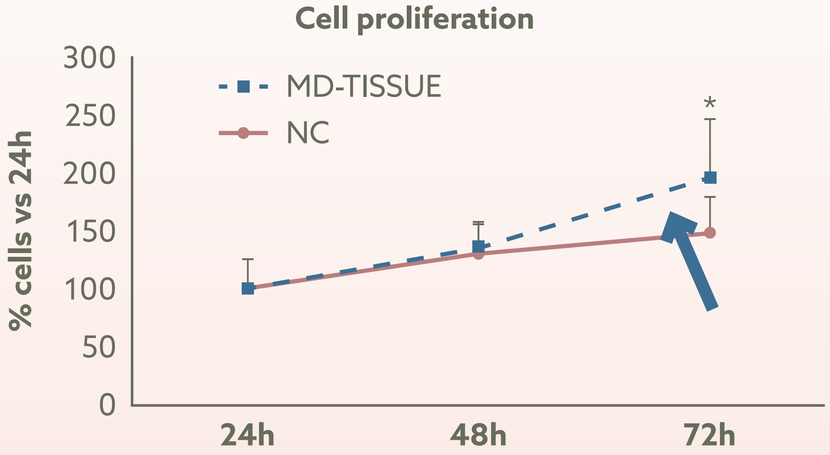

NC: negative control

Wound healing assay (scratch assay): Cell migration of tenocytes cultured on **MD-TISSUE** or control toward the injury site. Wound repair and closure were demonstrated at **24 hours**, as shown by the closure area and expressed as a percentage relative to the area at **0 h** (*p < 0.005 vs NC).

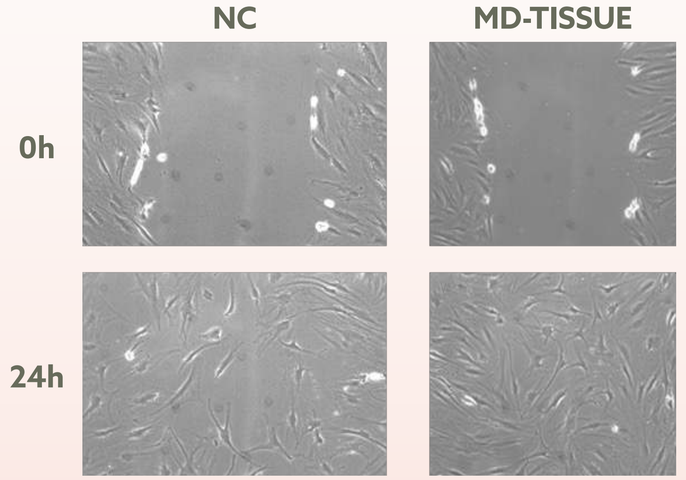

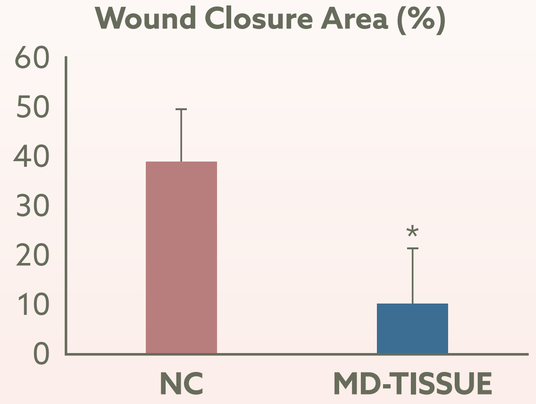

Conclusions: MD-TISSUE acts as a mechanical scaffold capable of promoting tendon homeostasis and repair.

READ THE STUDY

Randelli et al. Effect of a Collagen-Based Compound on Morpho-Functional Properties of Cultured Human Tenocytes. Cells 2018 Dec 6;7(12):246.

aesthetic GUNA

Mechanism of action of MD-TISSUE

In vitro study conducted on human tenocytes obtained from fragments of the gluteus minimus tendon, harvested from 4 patients undergoing total hip arthroplasty and cultured with MD-TISSUE.

MD-TISSUE collagen was analyzed as a biomaterial by radiation scattering. Thanks to adhesion plaques, it adheres to the tissue and promotes cell migration capacity.

- The **presence of the scaffold** was demonstrated using **spectroscopy techniques** (immunofluorescence) and **by dosing cytochalasin**, which deprives tenocytes of cytoskeleton-mediated mechanical stimulation.

- MD-TISSUE influences the ability of tenocytes to form **focal adhesions**, which are essential for cell migration.

Expression levels of mechanosensors FAK and PAX

Conclusions: By acting as a mechanical scaffold, MD-TISSUE:

1. Represents an effective medical device for a novel therapeutic, regenerative, and rehabilitative approach aimed at promoting tendon healing in tendinopathies;
2. Enhances focal adhesion formation and cell migration capacity;
3. Triggers a mechanotransduction mechanism, i.e., the ability of cells to convert mechanical stimuli into biochemical signals that can influence gene expression, cell morphology, and cell fate.

READ THE STUDY

Randelli et al. The Collagen-Based Medical Device MD-Tissue Acts as a Mechanical Scaffold Influencing Morpho-Functional Properties Cells 2020 Dec ;9(12): 2641.

aesthetic GUNA

Gene expression of the mechanosensors FAK and PAX is strongly influenced by MD-TISSUE

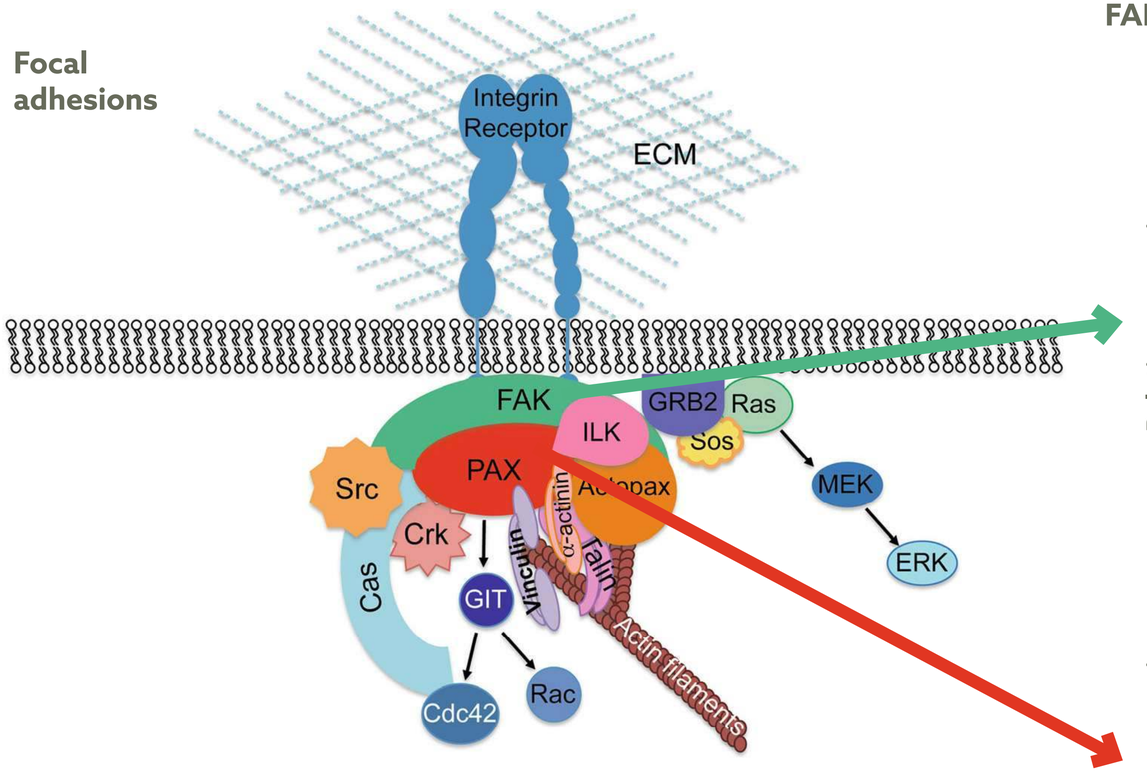

FAK and PAX mRNA expression levels after normalization to GAPDH gene expression (mean ± SD; n = 2)

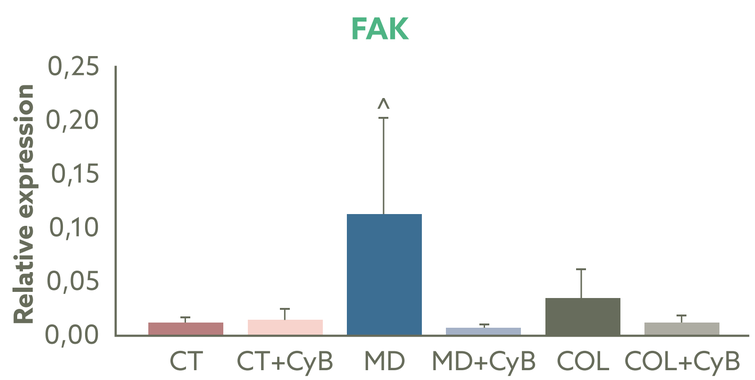

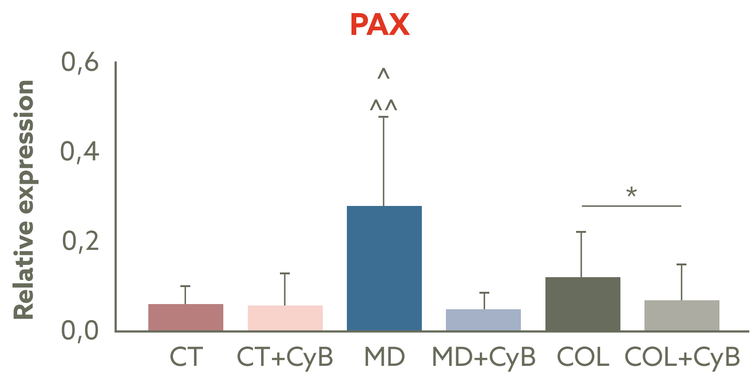

CT: Control; CyB: Cytochalasin B; MD: MD-TISSUE; COL: Collagen.
* p < 0,05 (t-test); ^ p < 0,05 vs. CT, CT+CyB, MD+CyB, COL+CyB;
^^ p < 0,01 vs. MD+CyB e COL+CyB (ANOVA)

Scanning electron microscopy (SEM) image of human tenocytes cultured on an MD-TISSUE-coated Petri dish. In the inset, thin, flattened cellular protrusions extending from the cell body are visible (arrows).

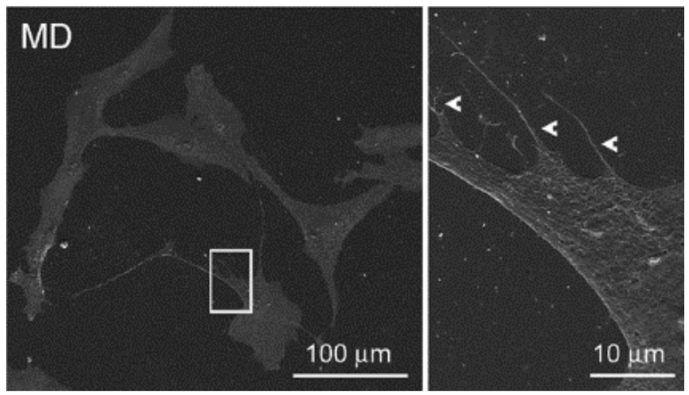

López-Colomé AM, Lee-Rivera I, Benavides-Hidalgo R, López E. Paxillin: a crossroad in pathological cell migration. J Hematol Oncol. 2017 Feb 18;10(1):50. **Randelli et al.** The Collagen-Based Medical Device MD-Tissue Acts as a Mechanical Scaffold Influencing Morpho-Functional Properties Cells 2020 Dec ;9 (12): 2641.

GUNA aesthetic portfolio - Value proposition

A bio-regenerative protocol for face and body designed to achieve a NATURAL-looking result

1. Collagen-based bio-scaffold

- Barrier effect against free radicals
- Mechanical support
- Extracellular matrix reinforcement
- Reparative and antioxidant action
- Injectable using retrograde linear and mesotherapy techniques
- Compatible with instrumental/pharmacological therapies/medical devices/fillers

2. GUNA supplements and cosmetics based on collagen/exosomes

Cost-effective

High safety profile

aesthetic GUNA

Beauthentic

The new language of the skin

Injection techniques in aesthetic medicine

A collagen-based therapeutic solution that can be administered using multiple injection techniques.

MESOTHERAPY using 2-13 mm needles (intradermal)

THERAPEUTIC SOLUTIONS AVAILABLE ON THE MARKET:

Fillers, biorevitalizing agents

RETROGRADE LINEAR AND WHEAL TECHNIQUES

THERAPEUTIC SOLUTIONS AVAILABLE ON THE MARKET:

- Hyaluronic acid
- Polypeptides
- PRP
- Botulinum toxin

Shen S, et al. Efficacy and Safety of Collagen Filler for Intradermal Injection: A Randomized Prospective Controlled Multicenter Study. Aesthetic Plast Surg. 2025 Oct;49(20):5683-5695.

aesthetic GUNA

MD-TISSUE positioning

MD-TISSUE

Collagen-based medical device
for the treatment of wrinkles, scars,
post-acne blemishes, skin laxity and loss of tone

SCAN ME

PLAY SURE
doping free

CE Medical Device (Class III).
Please read the instructions and warnings before use.

MEDICAL DEVICE	EXCIPIENTS	ACTIVITIES
MD-TISSUE	Vitamin C, Vitamins B1-B2-B6, Magnesium gluconate	Antioxidant action Protects cellular tissue from oxidative damage

READ THE TECHNICAL DATA SHEET

AREAS OF APPLICATION

MD-TISSUE is intended to limit the physiological deterioration of the skin and subcutaneous connective tissue and to counteract the effects due to chrono-ageing and photo-ageing, such as:

- topical anti-aging treatment
- facial and neck wrinkles
- firming of the subcutaneous and perivascular connective tissue layer of the face and neck
- impaired trophism of the connective tissue of the face and neck due to exogenous pollutants/dysmetabolism

Scientific evidence demonstrates the efficacy and safety of MD-TISSUE:

- in the treatment of scars and wounds

The treatment may be combined with other therapies.

THERAPEUTIC PROTOCOL

1 injection every 15 days to limit the physiological deterioration of the skin and subcutaneous connective tissue and to counteract the effects of chrono-ageing and photo-ageing. Visible results from the third injection; however, depending on the patient's aesthetic treatment plan, treatment may be continued up to the tenth week without risks.

1. Wrinkle biorevitalization (face, neck, décolleté) and scar treatment
2. Post-acne imperfections
3. Skin laxity and loss of tone

aesthetic GUNA

MD-TISSUE: Vitamin C and Vitamins B1 - B2 - B6

The excipients contained in **MD-TISSUE** create a **protective barrier against free radicals** and **counteract connective tissue aging**.

1. VITAMIN C (Ascorbic Acid)

- A reducing agent involved in the hydroxylation of proline to hydroxyproline. It is essential for amino acid and collagen biosynthesis and exerts **antioxidant and depigmenting activity**.
  - ✔ Hydroxyproline is an amino acid found almost exclusively in collagen. It confers structural stability to collagen through hydrogen bonding. Urinary hydroxyproline excretion (an index of collagen metabolism) represents a useful parameter for evaluating catabolic conditions affecting bone and connective tissue.
- Neutralizes free radicals.

2. **MAGNESIUM GLUCONATE: accelerates protein metabolism** and **new collagen synthesis**, enhances energy production, and exerts antioxidant activity.
3. **THIAMINE HYDROCHLORIDE (Vitamin B1):** converts glucose into energy and **supports cellular energy processes for ATP production**. Being water-soluble, it **facilitates metabolic cellular functions**. Acts as a coenzyme in several cellular processes (amino acid catabolism), and supports muscle trophism.
4. **RIBOFLAVIN (Vitamin B2):** one of the eight B-group vitamins, water-soluble (not stored by the human body). Plays a key role in energy metabolism, supports nerve function, and **protects cellular tissue from oxidative damage**.
5. **PYRIDOXINE (Vitamin B6):** a water-soluble vitamin involved in **energy balance and amino acid metabolism**. Deficiency may result in peripheral neuropathies, generalized weakness, and muscle spasms.

Indications for the use of MD-TISSUE

MD-TISSUE (for intradermal use via linear injections or wheals between wrinkles) is indicated for:

- Pronounced wrinkles
  - Face, neck, forehead, décolleté
  - "Barcode" lines (2 mm; 30G or 32G needle; repeated cycles every 2-3 weeks over 2-3 months)
- Fine and linear forehead wrinkles (where botulinum toxin is not indicated or as a complementary treatment)
- Mild, straight forehead wrinkles
- Scars
- Stretch marks
- Post-acne imperfections
- Skin laxity and loss of tone

Treatment cycle

3-5 injection sessions (first 3 sessions every 15 days, remaining 2 sessions after 30 days)

aesthetic GUNA

MD-MATRIX positioning

MD-MATRIX

Collagen-based medical device
for the treatment of localised adiposity and firming
of the subcutaneous connective tissue layer

SCAN ME

PLAY SURE
doping free

CE Medical Device (Class III).
Please read the instructions and warnings before use.

MEDICAL DEVICE	EXCIPIENTS	ACTIVITIES
MD-MATRIX	Citric acid, Nicotinamide	Cellular metabolism support Protective barrier against free radicals Anti-inflammatory action on localized cellulite

READ THE TECHNICAL DATA SHEET

AREAS OF APPLICATION

MD-MATRIX is intended to firm the subcutaneous and microvascular connective tissue layer in localised adiposity and in connective tissue fibroedematous gynoid excesses, particularly those located at the root of the thighs and the inner knee area.
Scientific evidence shows the efficacy and safety of MD-MATRIX in:

- in the treatment of localised adiposity of the knees and abdomen.

Treatment may be combined with other therapies.

THERAPEUTIC PROTOCOL

1 injection every 15 days to firm the subcutaneous and microvascular connective tissue layer in localised adiposity and in connective tissue fibroedematous gynoid excesses, particularly those located at the root of the thighs and the inner knee area. Visible results from the third injection; however, depending on the patient's aesthetic treatment plan, treatment may be continued up to the tenth week without risks.

1. Localized adiposity (thighs, gluteal region, submental area, arm laxity)
2. Skin hyperpigmentation (hands, face, neck, and décolleté)

aesthetic GUNA

MD-MATRIX: citric acid and nicotinamide

- MD-MATRIX contains **citric acid** and **nicotinamide** as excipients, both essential for **cellular metabolism**, electron transport, **antioxidant activity**, and **energy production**.
- These properties make MD-MATRIX particularly effective in strengthening the extracellular matrix, creating a defensive barrier against free radicals, and reducing dehydration.

✔ **CITRIC ACID**

Acts as a **pH regulator** and has **exfoliating properties**. It acts as a chelating agent (helping bind heavy metals) and plays a key role in **cell renewal**, counteracting skin imperfections. Citric acid also exhibits keratolytic activity, enhancing skin brightness and radiance.

✔ **NICOTINAMIDE (NIACINAMIDE)**

Proven to be an exceptional skin-active ingredient, particularly beneficial for tissues showing early signs of aging. It acts as an **effective moisturizer**, improving the **skin barrier function** and protecting the skin from pollution-related damage and UV radiation. Nicotinamide is also a potent **antioxidant** that positively affects both the function and appearance of the skin by enhancing dermal blood flow and microcirculation. In addition, it stimulates collagen and elastin production, brightens and evens skin tone, and **acts against skin hyperpigmentation**.

Indications for the use of MD-MATRIX

MD-MATRIX (for intradermal or subcutaneous use, including wheal injections) is indicated for:

- Localized adiposity (thighs, gluteal region, submental area, arm laxity
- Skin hyperpigmentation (hands, face, and décolleté)

Treatment Cycle

3-5 injection sessions (first 3 sessions every 15 days, remaining 2 sessions after 30 days)

Therapies & Protocols

Protocols < 40 years

- Facial area
- Periorbital area
- Neck
- Décolleté/breast area
- Hands
- Arms
- Abdomen
- Gluteus/thighs

Protocols > 40 years

- Facial area
- Periorbital area
- Neck
- Décolleté/breast area
- Arms
- Abdomen
- Gluteus/thighs
- Hands

aesthetic GUNA

Beauthentic

The new language of the skin

Treatments and protocols in aesthetic medicine

TARGET < 40 YEARS

PLAY SURE
doping free

SUMMARY
PROTOCOLS
<40 YEARS

aesthetic GUNA

Summary protocols < 40 years

Area	Indications	Number of sessions of collagen injections	Transcutaneous sessions with gunaphoresis (magnetophoresis)
Facial area	Wrinkles	3-5 (MD-TISSUE, 2-6 ml each)	5-8 (MD-TISSUE, 2-6 ml each)
	Skin hyperpigmentation	3-5 (MD-MATRIX, 2-6 ml each)	5-8 (MD-MATRIX, 2-6 ml each)
	Scars (post-acne, post-surgical)	3-5 (MD-TISSUE, 2-8 ml* each)	5-8 (MD-TISSUE, 2-8 ml* each)
Periorbital area	Wrinkles	3-5 (MD-TISSUE, 2-4 ml each)	5-8 (MD-TISSUE, 2-4 ml each)
	Marks and dark circles	3-5 (MD-MATRIX, 2 ml each)	5-8 (MD-MATRIX, 2 ml each)
	Under-eye bag	3-5 (MD-TISSUE, 2-4 ml each)	5-8 (MD-TISSUE, 2-4 ml each)
Neck	Wrinkles	3-5 (MD-TISSUE, 2-6 ml each)	5-8 (MD-TISSUE, 2-6 ml each)
	Skin hyperpigmentation	3-5 (MD-MATRIX, 2-6 ml each)	5-8 (MD-MATRIX, 2-6 ml each)
	Submental adiposity	3-5 (MD-MATRIX, 4-6 ml each)	5-8 (MD-MATRIX, 4-6 ml each)
	Scars	3-5 (MD-TISSUE, 2-8 ml each)	5-8 (MD-TISSUE, 2-8 ml each)
Décolleté/ breast area	Wrinkles	3-5 (MD-TISSUE, 2-8 ml each)	5-8 (MD-TISSUE, 2-8 ml each)
	Skin hyperpigmentation	3-5 (MD-MATRIX, 2-6 ml each)	5-8 (MD-MATRIX, 2-6 ml each)
	Scars	3-5 (MD-TISSUE, 2-8 ml* each)	5-8 (MD-TISSUE, 2-8 ml* each)
	Stretch marks	3-5 (MD-TISSUE, 6-10 ml* each)	5-8 (MD-TISSUE, 6-10 ml* each)
Arms	Skin laxity	3-5 (MD-TISSUE, 4-10 ml each)	5-8 (MD-TISSUE, 4-10 ml each)
	Localized adiposity	3-5 (MD-MATRIX, 4-10 ml each)	5-8 (MD-MATRIX, 4-10 ml each)
	Scars/Stretch marks	3-5 (MD-TISSUE, 8-10 ml* each)	5-8 (MD-TISSUE, 8-10 ml* each)
Hands	Skin laxity	3-5 (MD-TISSUE, 4-8 ml each)	5-8 (MD-TISSUE, 4-8 ml each)
	Skin hyperpigmentation	3-5 (MD-MATRIX, 2-6 ml each)	5-8 (MD-MATRIX, 2-6 ml each)
Abdomen	Skin laxity	3-5 (MD-TISSUE, 6-10 ml each)	5-8 (MD-TISSUE, 6-10 ml each)
	Localized adiposity/cellulite	3-5 (MD-MATRIX, 6-12 ml each)	5-8 (MD-MATRIX, 6-12 ml each)
	Scars	3-5 (MD-TISSUE, 6-12 ml* each)	5-8 (MD-TISSUE, 6-12 ml* each)
	Stretch marks	3-5 (MD-TISSUE, 8-10 ml* each)	5-8 (MD-TISSUE, 8-10 ml* each)
Gluteus/thighs	Skin laxity	3-5 (MD-TISSUE, 6-10 ml each)	5-8 (MD-TISSUE, 6-10 ml each)
	Localized adiposity/cellulite	3-5 (MD-MATRIX, 6-12 ml each)	5-8 (MD-MATRIX, 6-12 ml each)
	Stretch marks	3-5 (MD-TISSUE, 8-10 ml* each)	5-8 (MD-TISSUE, 8-10 ml* each)

*Depending on the extent and depth of the stretch marks.

Facial area: treatments

- **WRINKLES →** 3-5 MD-TISSUE injection sessions, 2-6 mL per session. The first three sessions every 15 days, followed by sessions every 30 days.
  - ✔ Microinjection/wheal technique: insert the needle to a depth of 1-3 mm and perform microinjections of 0.02-0.05 mL, placed adjacent to each other at 1-1.5 cm intervals and at a depth of 1-2 mm, up to a total volume of 8 mL over the treated area. Close micro-deposits can be performed along the main axis of static wrinkles.
  - ✔ Retrograde linear/fanning technique: insert the needle almost tangential to the skin across the entire treatment area. Inject using a retrograde technique while simultaneously withdrawing the needle or cannula. Release approximately 0.05 mL per injection point.
- **SKIN HYPERPIGMENTATION →** 3-5 MD-MATRIX injection sessions, 2-6 mL per session. The first three sessions every 15 days, followed by sessions every 30 days.
  - ✔ Intradermal and subcutaneous administration: insert the needle to a depth of 1-3 mm and perform microinjections of 0.02-0.05 mL per point, up to a maximum total volume of 6 mL over the treated area.
- **SCARS/ACNE →** 3-5 MD-TISSUE injection sessions, 2-8 mL per session, depending on scar extent and depth. The first three sessions at 15-day intervals, followed by sessions at 30-day intervals.
  - ✔ Step 1: using a 29G or 30G, 13 mm needle, insert tangentially into the scar to loosen the adhesion at its base (subcision or fibrotic release when feasible). Then inject 0.1 mL of product using a retrograde linear technique.
  - ✔ Step 2: using a 30G, 4 mm needle, inject 0.05 mL into the superficial dermis (approximately 1-2 mm depth). Cover the entire scar area with adjacent micro-wheals.

Facial area: target & protocol

Wrinkle treatment

- **TARGET:** MEN/WOMEN
- **PROTOCOL:**

1-2 tablets per day for 3 months

NEEDLE-BASED

3-5 injections of 2-6 mL (1-3 vials) at 15-30-day intervals, depending on the treatment performed and the extent of the area to be treated

NEEDLE-FREE

5-8 sessions using 2-6 mL (1-3 vials) at 10-day intervals, depending on the treatment performed and the extent of the area to be treated

Apply and massage daily on the treated areas

aesthetic GUNA

Facial area: target & protocol

Skin hyperpigmentation treatment

- **TARGET:** WOMEN
- **PROTOCOL:**

3 tablets per day for 3 months

NEEDLE-BASED

3-5 injections of 2-6 mL (1-3 vials) at 15-30-day intervals, depending on the treatment performed and the extent of the area to be treated

NEEDLE-FREE

5-8 sessions using 2-6 mL (1-3 vials) at 10-day intervals, depending on the treatment performed and the extent of the area to be treated

Apply and massage daily on the treated areas

aesthetic GUNA

Facial area: target & protocol

Scar/acne treatment

- **TARGET:** ADOLESCENTS/MEN/WOMEN
- **PROTOCOL:**

1 tablet per day for 3 months

NEEDLE-BASED

3-5 injections of 2-8 mL (1-4 vials) at 15-30-day intervals, depending on the treatment performed and the extent of the area to be treated

NEEDLE-FREE

5-8 sessions using 2-8 mL (1-4 vials) at 10-day intervals, depending on the treatment performed and the extent of the area to be treated

Apply and massage daily on the treated areas

aesthetic GUNA

Facial area: study

Biorevitalization with MD-TISSUE

OBJECTIVE

To evaluate the effectiveness of the medical device MD-TISSUE as a facial revitalizing treatment in improving skin elasticity and reducing wrinkles without altering facial expression.

MATERIALS AND METHODS

- 15 volunteers (33-50 years old) were treated with 6 weekly injection sessions into the nasolabial folds using a retrograde linear technique (27G needle).
- Outcomes were assessed using: photographic documentation (Visioface Quick), wrinkle volume calculation, elasticity measurement using an elastometer (at T0, T3, and T6), and patient satisfaction questionnaire.

MAIN RESULTS

- After 3 weeks of treatment, 11 out of 15 volunteers (73.33%) showed increased skin elasticity compared to baseline.
- Wrinkle volume was reduced by an average of 2.7% after 3 weeks and 13.4% after 6 weeks of treatment.

CONCLUSIONS

- MD-TISSUE demonstrated a good ability to improve skin elasticity and to reduce wrinkle volume.
- The fluid texture of the product is suitable for treatments of the neck, décolleté, and dorsal surface of the hands. Facial applications may include different techniques such as microinjections, injections at acupuncture points, and rejuvenation of the periocular and forehead areas.

READ THE STUDY

Falconi Klein E. Face Revitalization - Biolifting With MD-TISSUE. Physiological Regulating Medicine 2012.

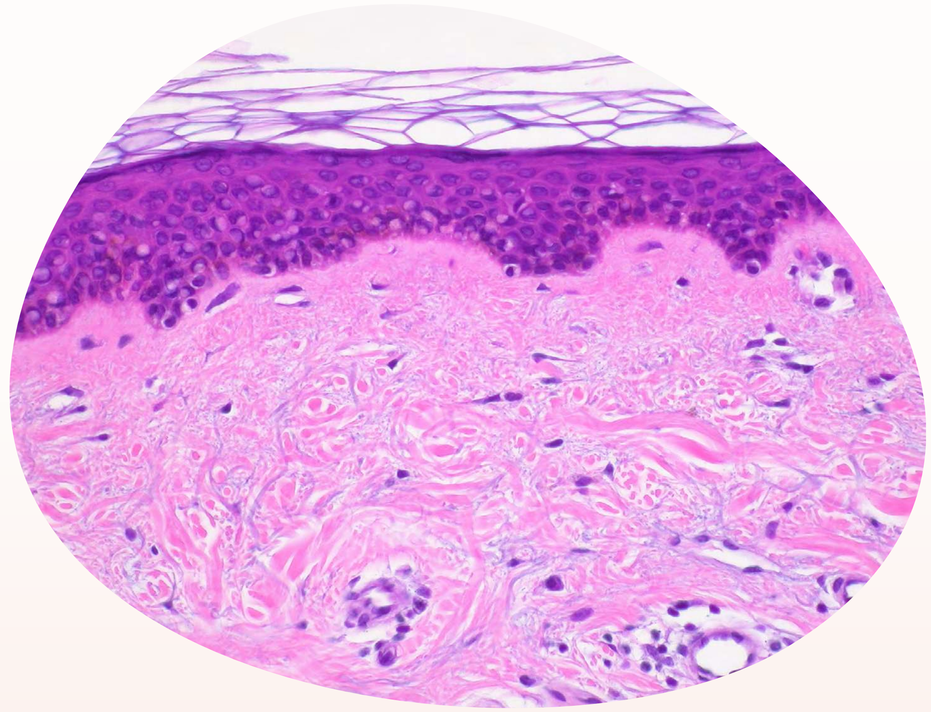

MD-TISSUE is a product designed for soft tissues, capable of creating a **protective barrier** against free radicals and **counteracting the physiological aging** of connective tissue. These properties are essential for an effective tissue **revitalizing treatment**.

aesthetic GUNA

Facial area: study

Facial dermo-aesthetic medicine: integrated therapy

OBJECTIVE

To evaluate the effectiveness of a multisystemic approach combining Bioregulatory Systems Medicine (BrSM) and nutraceuticals in the prevention and treatment of skin aging.

MATERIALS AND METHODS

20 women (35-70 years) were treated with multilevel protocols including **biodetoxification** (drainage, hydration, systemic anti-aging, body detox) and **biostimulation** (local injections, in selected cases microneedling radiofrequency, biorevitalizing acids, carboxytherapy), supported by BrSM and MADE, GUNA-Collagen, and MD-TISSUE preparations. Assessments were performed using questionnaires and photographic documentation.

MAIN RESULTS

A marked improvement in overall psychophysical well-being was observed, with no adverse reactions and excellent outpatient and home-treatment compliance.

CONCLUSIONS

The multisystemic approach combining BrSM and nutraceuticals proved to be safe and effective in the prevention and treatment of skin aging.

PRE-TREATMENT | POST-TREATMENT

Female, 53 years old. The patient underwent 5 sessions of carboxytherapy, followed by **weekly biostimulation**. A significant reduction in micro- and macro-wrinkles, particularly in the periocular area, was observed, along with an overall improvement in skin texture.

READ THE STUDY

Felloni G. Dermoaesthetic Facial Medicine - Integrated Therapy. Physiological Regulating Medicine 2023.

aesthetic GUNA

Facial area: study

Cervico-facial rejuvenation

OBJECTIVE

To evaluate the outcomes of injectable heterologous collagen treatment (MD-TISSUE) in improving wrinkles and skin quality of the face and neck.

MATERIALS AND METHODS

- 12 patients (45-70 years, mean age 53) were treated with MD-TISSUE (collagen combined with vitamins C, B1-B2-B6, and magnesium gluconate) using a retrograde linear technique (27-30G needles).
- 2-6 sessions per year (mean 3), spaced 3-8 weeks apart.

MAIN RESULTS

- Aesthetic improvement of wrinkles was observed in all cases, documented photographically.
- Mean patient satisfaction score: 8.5/10.

CONCLUSIONS

Biostimulation with MD-TISSUE helps counteract the physiological deterioration of the skin and subdermal connective tissue, offering an optimal cost-benefit profile with no clinically relevant product-related complications.

PRE-TREATMENT

POST-TREATMENT

READ THE STUDY

Riggio E. Medical device a base di collagene, MD-TISSUE, nel ringiovanimento cervico-facciale. Conference poster SIME 2025.

aesthetic GUNA

Facial area: study

Treatment of post-adolescence acne scarring

OBJECTIVE

To evaluate the efficacy and tolerability of MD-TISSUE in improving post-acne scars in adolescents.

MATERIALS AND METHODS

- 5 adolescents (15-17 years) received five weekly MD-TISSUE injections using a mesotherapy technique (13 mm, 30G needle), combined with oral and topical Dermoguna therapy.
- Assessment was performed through clinical and photographic evaluation, supported by patient satisfaction scales.

MAIN RESULTS

Patients showed a significant aesthetic improvement in scar depth, smoothness, and texture, confirmed by satisfaction scores (mean score: 9/10), with no allergic reactions or treatment-related discomfort.

CONCLUSIONS

MD-TISSUE injection, combined with antioxidant excipients (vitamins C, B1, B2, B6, and magnesium gluconate), represents a safe and effective therapy for the treatment of post-acne scarring in adolescents.

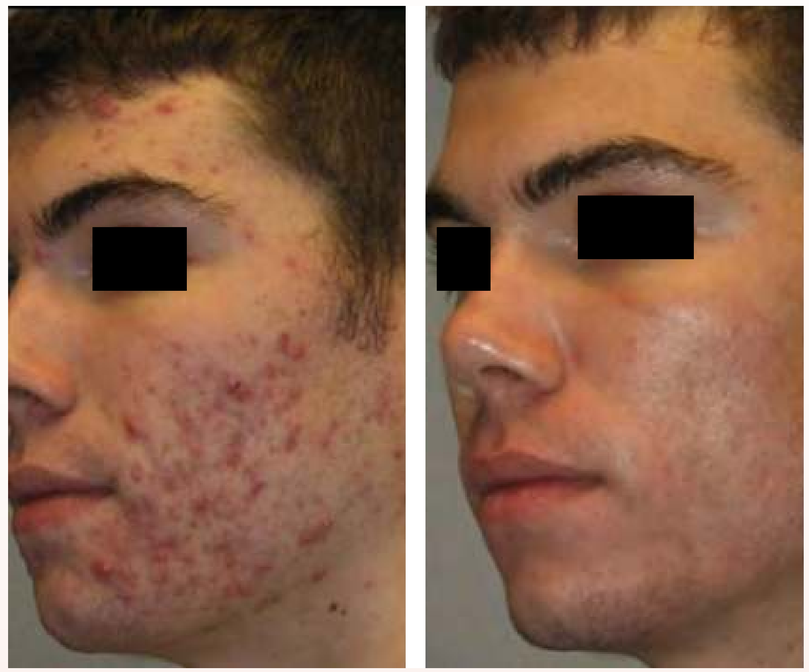

PRE-TREATMENT | POST-TREATMENT

READ THE STUDY

Squillante A. Trattamento con collagene infiltrativo suino in esiti cicatriziali post acne adolescenziale. Conference poster AGORÀ 2025.

aesthetic GUNA

Facial area: study

Biostimulation and dermal biorestructuring in skin aging

OBJECTIVE

To evaluate the effectiveness of collagen biostimulation in improving skin aging in patients over 35 years.

MATERIALS AND METHODS

- 10 patients received 4 biweekly injections of 2 mL of MD-TISSUE to the face, neck, and periocular area.
- Assessments were performed through photographic documentation and aesthetic satisfaction scales.

MAIN RESULTS

70% of patients showed functional and aesthetic improvement, with wrinkle smoothing, increased skin tone and elasticity, and improved extracellular matrix plasticity.

CONCLUSIONS

MD-TISSUE is effective in dermal biorestructuring in adults over 35 years, promoting neocollagenesis and improving skin tone, elasticity, and natural appearance.

PRE-TREATMENT | POST-TREATMENT

READ THE STUDY

Turchi A. Biostimolazione e bioristrutturazione dermica con collagene porcino nell'invecchiamento cutaneo. Conference poster AGORÀ 2025.

aesthetic GUNA

Periorbital area: treatments

- **WRINKLES →** 3-5 MD-TISSUE injection sessions, 2-4 mL per session. The first three sessions at 15-day intervals, followed by sessions at 30-day intervals.
  - ✔ Microinjection/wheal technique: insert the needle to a depth of 1-2 mm and perform microinjections of 0.02-0.05 mL, up to a total volume of 4 mL in the treated area.
  - ✔ Retrograde linear technique: using a 13 mm needle, insert almost tangentially to the skin across the entire treatment area. Inject using a retrograde technique while simultaneously withdrawing the needle or cannula. Release approximately 0.05 mL per injection point.
- **INFRAORBITAL HYPERPIGMENTATION (DARK CIRCLES) →** 3-5 MD-MATRIX injection sessions, 2 mL per session. The first three sessions at 15-day intervals, followed by sessions at 30-day intervals.
  - ✔ Intradermal and subcutaneous administration: insert the needle to a depth of 1-4 mm and perform microinjections of 0.05 mL per point. The total injected volume varies according to the extent of the pigmented area.
- **UNDER-EYE BAGS →** 3-5 MD-TISSUE injection sessions, 2-4 mL per session. The first three sessions at 15-day intervals, followed by sessions at 30-day intervals.
  - ✔ Microinjection/wheal technique: insert the needle to a depth of 1-3 mm and perform microinjections of 0.02-0.05 mL, up to a total volume of 4 mL in the treated area.

Periorbital area: target & protocol

Periorbital wrinkle treatment

- **TARGET:** MEN/WOMEN
- **PROTOCOL:**

1-2 tablets per day for 3 months

NEEDLE-BASED

3-5 injections of 2-4 mL (1-2 vials) at 15-30-day intervals, depending on the treatment performed and the extent of the area to be treated

NEEDLE-FREE

5-8 sessions using 2-4 mL (1-2 vials) at 10-day intervals, depending on the treatment performed and the extent of the area to be treated

Apply and massage daily on the treated areas

aesthetic GUNA

Periorbital area: target & protocol

Infraorbital hyperpigmentation and mark treatment (dark circles)

- **TARGET:** MEN/WOMEN
- **PROTOCOL:**

NEEDLE-BASED

NEEDLE-FREE

3 tablets per day for 3 months

3-5 injections of 2 mL (1 vial) at 15-30-day intervals, depending on the treatment performed and the extent of the area to be treated

5-8 sessions using 2 mL (1 vial) at 10-day intervals, depending on the treatment performed and the extent of the area to be treated

Apply and massage daily on the treated areas

aesthetic GUNA

Periorbital area: target & protocol

Under-eye bag treatment



- **TARGET:** MEN/WOMEN
- **PROTOCOL:**

1-2 tablets per day for 3 months

NEEDLE-BASED

3-5 injections of 2-4 mL (1-2 vials) at 15-30-day intervals, depending on the treatment performed and the extent of the area to be treated

NEEDLE-FREE

5-8 sessions using 2-4 mL (1-2 vials) at 10-day intervals, depending on the treatment performed and the extent of the area to be treated

Apply and massage daily on the treated areas

aesthetic GUNA

Periorbital area: study
Dark circle treatment

OBJECTIVE
To evaluate the effectiveness of a non-invasive regenerative protocol based on MD-MATRIX in improving dark circles in young and adult patients.

MATERIALS AND METHODS
- 10 patients (25-60 years) received 5 weekly injections of 4 mL of MD-MATRIX (citric acid and nicotinamide) using fanning and drop techniques (13 mm, 30G needle), combined with topical therapy using Dermoguna serum and Arnica.
- Assessment was performed using photographic documentation and physician-patient satisfaction scales.

MAIN RESULTS
Tissue improvement was observed, particularly in cases of dark circles associated with tear trough volume loss, with a camouflaging effect on pigmented dark circles and high tolerability.

CONCLUSIONS
The non-invasive regenerative MD-MATRIX protocol represents a promising therapeutic option for the treatment of dark circles related to volume loss, while adjunctive topical therapy also supported pigmented forms.

PRE-TREATMENT | POST-TREATMENT

READ THE STUDY

Squillante A. Trattamento delle occhiaie con collagene infiltrativo suino: approccio rigenerativo peruna zona periorbitale più giovane e luminosa. Conference poster AGORÀ 2025.

aesthetic GUNA

Periorbital area: study

Biostimulation of the periorbital area

OBJECTIVE

To evaluate the effectiveness of a combined MD-MATRIX and MD-TISSUE protocol in reducing dark circles in adult women.

MATERIALS AND METHODS

- 6 patients (30-50 years) received five weekly injections: the first two sessions with MD-MATRIX (collagen, citric acid, nicotinamide) to prepare the extracellular matrix, followed by three sessions with MD-TISSUE (collagen, vitamins C, B1, B2, B6, and magnesium gluconate) to target the tissues and enhance the regenerative and biostimulatory response.
- Assessment was performed using physician and patient satisfaction scales.

MAIN RESULTS

- Treatment led to an increase in dermal-epidermal thickness and a reduction in the visibility of superficial vessels and hyperchromic areas.
- Mean satisfaction scores were 8/10 for patients and 10/10 for physicians.

CONCLUSIONS

The combined MD-MATRIX and MD-TISSUE protocol promotes periocular biostimulation, improving skin tone, firmness, and radiance.

PRE-TREATMENT

POST-TREATMENT

READ THE STUDY

Turchi A. Efficacia della biostimolazione con collagene iniettivo suino nel trattamento delle occhiaie perioculari. Conference poster AGORÀ 2025.

aesthetic GUNA

Periorbital area: study

Periocular area treatment

OBJECTIVE

To evaluate the effectiveness of a non-invasive treatment of the periocular area, prone to early aging, characterized by skin laxity, roughness, and loss of tone.

MATERIALS AND METHODS

10 patients received 5 weekly sessions of transdermal delivery of MD-MATRIX (collagen, citric acid, and nicotinamide) using resonance magnetophoresis. Treatment was integrated with oral intake of Neorland® dermal collagen, rich in exosomes, horsetail extract, and vitamins C, E, B2, and niacin, as well as topical application of a serum containing the same collagen, vitamins C and E, and *Rosa Centifolia* flower water.

MAIN RESULTS

Post-treatment evaluation showed increased skin firmness, reduction of static wrinkles and dark circles, with no side effects. The treatment was well tolerated and easily performed, including during the summer period.

CONCLUSIONS

Transdermal delivery of collagen via magnetophoresis proved effective in improving periocular skin quality, offering a safe, effective, and well-tolerated therapeutic option.

READ THE STUDY

Ciampa S. Trattamento non invasivo della zona perioculare con collagene suino: dalle rughe al "Sorriso nello sguardo". Conference poster AGORÀ 2025.

aesthetic GUNA

Neck: treatments

- **WRINKLES →** 3-5 MD-TISSUE injection sessions, 2-6 mL per session. The first three sessions at 15-day intervals, followed by sessions at 30-day intervals.
  - ✔ Microinjection/wheal technique: insert the needle to a depth of 2-4 mm and perform adjacent microinjections of 0.05-0.1 mL, up to a total volume of 6 mL, to cover the entire treatment area.
  - ✔ Retrograde linear technique along horizontal neck wrinkles: insert the needle almost tangentially to the skin, then inject while simultaneously withdrawing the needle or cannula. Release approximately 0.05-0.1 mL per injection point.
- **SKIN HYPERPIGMENTATION →** 3-5 MD-MATRIX injection sessions, 2-6 mL per session. The first three sessions at 15-day intervals, followed by sessions at 30-day intervals.
  - ✔ Intradermal and subcutaneous administration: insert the needle to a depth of 2-4 mm and perform microinjections of 0.05-0.1 mL, spaced 0.5-1 cm apart, to cover the entire treatment area.
- **SUBMENTAL ADIPOSITY →** 3-5 MD-MATRIX injection sessions, 4-6 mL per session. The first three sessions at 15-day intervals, followed by sessions at 30-day intervals.
  - ✔ Intradermal and subcutaneous administration: insert the needle to a depth of 3-8 mm, depending on the submental skin fold, and perform microinjections of 0.1-0.2 mL per point, spaced approximately 1 cm apart, until an appropriate volume is delivered according to the treated area.
- **SCARS →** 3-5 MD-TISSUE injection sessions, 2-8 mL per session. The first three sessions at 15-day intervals, followed by sessions at 30-day intervals.
  - ✔ Step 1: using a 29G or 30G, 13 mm needle, insert tangentially into the scar to loosen the adhesion at its base (subcision or fibrotic debridement when feasible). Then inject 0.1 mL of product at this level using a retrograde linear technique.
  - ✔ Step 2: using a 30G, 4 mm needle, inject 0.05 mL of product into the superficial dermis (approximately 1-2 mm depth) to reach the most superficial portion of the scar. Cover the entire scar area with adjacent micro-wheals.

aesthetic GUNA

Neck: target & protocol

Wrinkle treatment

- **TARGET:** MEN/WOMEN
- **PROTOCOL:**

1-2 tablets per day for 3 months

NEEDLE-BASED

3-5 injections of 2-6 mL (1-3 vials) at 15-30-day intervals, depending on the treatment performed and the extent of the area to be treated

NEEDLE-FREE

5-8 sessions using 2-6 mL (1-3 vials) at 10-day intervals, depending on the treatment performed and the extent of the area to be treated

Apply and massage daily on the treated areas

aesthetic GUNA

Neck: target & protocol

Skin hyperpigmentation treatment

- **TARGET:** WOMEN
- **PROTOCOL:**

3 tablets per day for 3 months

NEEDLE-BASED

3-5 injections of 2-6 mL (1-3 vials) at 15-30-day intervals, depending on the treatment performed and the extent of the area to be treated

NEEDLE-FREE

5-8 sessions using 2-6 mL (1-3 vials) at 10-day intervals, depending on the treatment performed and the extent of the area to be treated

Apply and massage daily on the treated areas

aesthetic GUNA

Neck: target & protocol

Submental adiposity treatment

- **TARGET:** MEN/WOMEN
- **PROTOCOL:**

1 tablet per day for 3 months

NEEDLE-BASED

3-5 injections of 4-6 mL (2-3 vials) at 15-30-day intervals, depending on the treatment performed and the extent of the area to be treated

NEEDLE-FREE

5-8 sessions using 4-6 mL (2-3 vials) at 10-day intervals, depending on the treatment performed and the extent of the area to be treated

Apply and massage daily on the treated areas

aesthetic GUNA

Neck: target & protocol

Neck scar treatment

- **TARGET:** MEN/WOMEN
- **PROTOCOL:**

1 tablet per day for 3 months

NEEDLE-BASED

3-5 injections of 2-8 mL (1-4 vials) at 15-30-day intervals, depending on the treatment performed and the extent of the area to be treated

NEEDLE-FREE

5-8 sessions using 2-8 mL (1-4 vials) at 10-day intervals, depending on the treatment performed and the extent of the area to be treated

Apply and massage daily on the treated areas

aesthetic GUNA

Décolleté/breast area: treatments

- **WRINKLES →** 3-5 MD-TISSUE injection sessions, 2-8 mL per session. The first three sessions at 15-day intervals, followed by sessions at 30-day intervals.
  - ✔ Microinjection/wheal technique: insert the needle to a depth of 2-4 mm and perform adjacent microinjections of 0.05-0.1 mL, up to a total volume of 8 mL, to cover the entire treatment area.
  - ✔ Retrograde linear technique: In addition to the above biostimulation technique, the retrograde linear technique is recommended for the treatment of radial wrinkles. insert the needle almost tangentially to the skin, then inject using a retrograde technique while simultaneously withdrawing the needle or cannula. Release approximately 0.05-0.1 mL per injection point.
- **SKIN HYPERPIGMENTATION →** 3-5 MD-MATRIX injection sessions, 2-6 mL per session. The first three sessions at 15-day intervals, followed by sessions at 30-day intervals.
  - ✔ Intradermal and subcutaneous administration: insert the needle to a depth of 2-4 mm and perform microinjections of 0.05-0.1 mL, until the entire pigmented area is covered.
- **SCARS →** 3-5 MD-TISSUE injection sessions, 2-8 mL per session, depending on scar extent and depth. The first three sessions at 15-day intervals, followed by sessions at 30-day intervals.
  - ✔ Step 1: using a 29G or 30G, 13 mm needle, insert tangentially into the scar to loosen the adhesion at its base (subcision or fibrotic debridement when feasible). Then inject 0.1 mL of product at this level using a retrograde linear technique.
  - ✔ Step 2: using a 30G, 4 mm needle, inject 0.05 mL of product into the superficial dermis (approximately 1-2 mm depth) to reach the most superficial portion of the scar. Cover the entire scar area with adjacent micro-wheals.
- **STRETCH MARKS →** 3-5 MD-TISSUE injection sessions, 6-10 mL per session, depending on extent and depth of the lesion. The first three sessions at 15-day intervals, followed by sessions at 30-day intervals.
  - ✔ Microinjection/wheal technique: insert the needle to a depth of 2-6 mm and perform microinjections of 0.1-0.2 mL, until the entire area is covered (RED STRETCH MARKS).
  - ✔ Fanning technique: using a 29G or 30G, 13 mm needle, insert tangentially into the stretch mark to loosen the adhesion at its base (when feasible). Then inject 0.1 mL of product using a retrograde linear technique (WHITE STRETCH MARKS).

Décolleté/breast area: target & protocol

Wrinkle treatment

- **TARGET:** WOMEN
- **PROTOCOL:**

1-2 tablets per day for 3 months

NEEDLE-BASED

3-5 injections of 2-8 mL (1-4 vials) at 15-30-day intervals, depending on the treatment performed and the extent of the area to be treated

NEEDLE-FREE

5-8 sessions using 2-8 mL (1-4 vials) at 10-day intervals, depending on the treatment performed and the extent of the area to be treated

Apply and massage daily on the treated areas

aesthetic guna

Décolleté/breast area: target & protocol

Skin hyperpigmentation treatment

- **TARGET:** WOMEN
- **PROTOCOL:**

3 tablets per day for 3 months

NEEDLE-BASED

3-5 injections of 2-6 mL (1-3 vials) at 15-30-day intervals, depending on the treatment performed and the extent of the area to be treated

NEEDLE-FREE

5-8 sessions using 2-6 mL (1-3 vials) at 10-day intervals, depending on the treatment performed and the extent of the area to be treated

Apply and massage daily on the treated areas

aesthetic GUNA

Décolleté/breast area: target & protocol

Décolleté scar treatment

- **TARGET:** WOMEN
- **PROTOCOL:**

1 tablet per day for 3 months

NEEDLE-BASED

3-5 injections of 2-8 mL (1-4 vials) at 15-30-day intervals, depending on the treatment performed and the extent of the area to be treated

NEEDLE-FREE

5-8 sessions using 2-8 mL (1-4 vials) at 10-day intervals, depending on the treatment performed and the extent of the area to be treated

Apply and massage daily on the treated areas

aesthetic GUNA

Décolleté/breast area: target & protocol

Stretch mark treatment

- **TARGET:** WOMEN
- **PROTOCOL:**

1 tablet per day for 3 months

NEEDLE-BASED

3-5 injections of 6-10 mL (3-5 vials) at 15-30-day intervals, depending on the treatment performed and the extent of the area to be treated

NEEDLE-FREE

5-8 sessions using 6-10 mL (3-5 vials) at 10-day intervals, depending on the treatment performed and the extent of the area to be treated

Apply and massage daily on the treated areas

aesthetic GUNA

Décolleté/breast area: study

Complicated breast surgery scar

OBJECTIVE

To evaluate the effectiveness of MD-TISSUE injections in improving the aesthetic and functional outcome of a healed complex surgical scar.

MATERIALS AND METHODS

- A 44-year-old patient with a post-quadrantectomy breast scar, complicated by a sub-scar breast abscess that required drainage and subsequent healing by secondary intention.
- Subcutaneous injectable mesotherapy with MD-TISSUE collagen was initiated every 7 days for a total of 5 sessions.Follow-up evaluations were performed 3 and 10 days after completion of treatment.
- The Vancouver Scar Scale was administered before treatment and at follow-up visits.

MAIN RESULTS

Treatment led to an improvement in pigmentation and scar uniformity, with reduced adhesions to underlying tissues in the central portion of the scar (Vancouver Scale score: 4).

CONCLUSIONS

Collagen injections represent an innovative, minimally invasive therapeutic option with a favorable cost-benefit profile for the treatment of surgical scars.

PRE-TREATMENT

POST-TREATMENT

READ THE STUDY

Sgarbi L. Collagene suino di tipo i ad uso iniettivo sottocutaneo nel trattamento di cicatrice chirurgica mammaria complicata. Conference poster SIME 2025.

aesthetic GUNA

Arms: treatments

- **SKIN LAXITY →** 3-5 MD-TISSUE injection sessions, 4-10 mL per session. The first three sessions at 15-day intervals, followed by sessions at 30-day intervals.
  - ✔ Microinjection/wheal technique: insert the needle to a depth of 2-4 mm and perform microinjections of 0.02-0.05 mL, until the entire treatment area is covered.
  - ✔ Retrograde linear/fanning technique: insert the needle almost tangentially to the skin, then inject using a retrograde technique while simultaneously withdrawing the needle or cannula. Release approximately 0.05-0.1 mL per injection point.
- **LOCALIZED ADIPOSITY →** 3-5 MD-MATRIX injection sessions, 4-10 mL per session. The first three sessions at 15-day intervals, followed by sessions at 30-day intervals.
  - ✔ Intradermal and subcutaneous administration: insert the needle to a depth of 3-10 mm, depending on the thickness of the adipose fold, with the needle positioned perpendicular to the skin surface and within the adipose tissue layer. Space injection points approximately 1 cm apart until an appropriate volume is delivered according to the treated area. The use of 30G needles of appropriate length is recommended depending on the treatment goal: 4 mm needles may be sufficient to improve the appearance of localized adiposity; whereas 12 mm or 19 mm needles are recommended for the treatment of localized adiposity.
- **STRETCH MARKS →** 3-5 MD-TISSUE injection sessions, 8-10 mL per session, depending on extent and depth of the stretch marks.The first three sessions at 15-day intervals, followed by sessions at 30-day intervals.
  - ✔ Microinjection/wheal technique: insert the needle to a depth of 2-6 mm and perform microinjections of 0.1-0.2 mL, until the entire area is covered(RED STRETCH MARKS).
  - ✔ Fanning technique: using a 29G or 30G, 13 mm needle, insert tangentially into the stretch mark to loosen the adhesion at its base (when feasible). Then inject 0.1 mL of product using a retrograde linear technique (WHITE STRETCH MARKS).

Arms: target & protocol

Skin laxity treatment

- **TARGET:** MEN/WOMEN
- **PROTOCOL:**



NEEDLE-BASED

3-5 injections of 4-10 mL (2-5 vials) at 15-30-day intervals, depending on the treatment performed and the extent of the area to be treated

NEEDLE-FREE

5-8 sessions using 4-10 mL (2-5 vials) at 10-day intervals, depending on the treatment performed and the extent of the area to be treated

Apply and massage daily on the treated areas

aesthetic GUNA



Arms: target & protocol

Localized adiposity treatment

- **TARGET:** MEN/WOMEN
- **PROTOCOL:**

NEEDLE-BASED

3-5 injections of 4-10 mL (2-5 vials) at 15-30-day intervals, depending on the treatment performed and the extent of the area to be treated

NEEDLE-FREE

5-8 sessions using 4-10 mL (2-5 vials) at 10-day intervals, depending on the treatment performed and the extent of the area to be treated

Apply and massage daily on the treated areas

aesthetic GUNA

Arms: target & protocol

Stretch mark treatment

- **TARGET:** ADOLESCENTS/MEN/WOMEN
- **PROTOCOL:**

1 tablet per day for 3 months

NEEDLE-BASED

3-5 injections of 8-10 mL (4-5 vials) at 15-30-day intervals, depending on the treatment performed and the extent of the area to be treated

NEEDLE-FREE

5-8 sessions using 8-10 mL (4-5 vials) at 10-day intervals, depending on the treatment performed and the extent of the area to be treated

Apply and massage daily on the treated areas

aesthetic GUNA

Hands: treatments

- **SKIN LAXITY →** 3-5 MD-TISSUE injection sessions, 4-8 mL per session. The first three sessions at 15-day intervals, followed by sessions at 30-day intervals.
  - ✔ Microinjection/wheal technique: insert the needle to a depth of 2-3 mm and perform microinjections of 0.02-0.05 mL, until the entire treatment area is covered.
  - ✔ Retrograde linear cannula technique: insert a 25G or 23G cannula through the entry point created with the introducer needle. Position the cannula parallel to the skin surface, then inject using a retrograde technique while simultaneously withdrawing the cannula. Release approximately 0.02 mL per injection point.
- **SKIN HYPERPIGMENTATION →** 3-5 MD-MATRIX injection sessions, 2-6 mL per session. The first three sessions at 15-day intervals, followed by sessions at 30-day intervals.
  - ✔ Intradermal and subcutaneous administration: insert the needle to a depth of 2-4 mm and perform microinjections of 0.05-0.1 mL, until the entire pigmented area is covered.

Hands: target & protocol

Skin laxity treatment

- **TARGET:** WOMEN
- **PROTOCOL:**

1 tablet per day for 3 months

NEEDLE-BASED

3-5 injections of 4-8 mL (2-4 vials) at 15-30-day intervals, depending on the treatment performed and the extent of the area to be treated

NEEDLE-FREE

5-8 sessions using 4-8 mL (2-4 vials) at 10-day intervals, depending on the treatment performed and the extent of the area to be treated

Apply and massage daily on the treated areas

aesthetic GUNA

Hands: target & protocol

Skin hyperpigmentation treatment

- **TARGET:** WOMEN
- **PROTOCOL:**

3 tablets per day for 3 months

NEEDLE-BASED

3-5 injections of 2-6 mL (1-3 vials) at 15-30-day intervals, depending on the treatment performed and the extent of the area to be treated

NEEDLE-FREE

5-8 sessions using 2-6 mL (1-3 vials) at 10-day intervals, depending on the treatment performed and the extent of the area to be treated

Apply and massage daily on the treated areas

aesthetic GUNA

Abdomen: treatments

- **SKIN LAXITY →** 3-5 MD-TISSUE injection sessions, 6-10 mL per session. The first three sessions at 15-day intervals, followed by sessions at 30-day intervals
  - ✔ Microinjection/wheal technique: insert the needle to a depth of 1-3 mm and perform microinjections of 0.02-0.05 mL, until the entire treatment area is covered.
  - ✔ Retrograde linear/fanning technique: insert the needle almost tangentially to the skin, then inject using a retrograde technique while simultaneously withdrawing the needle or cannula. Release approximately 0.05-0.1 mL per injection point.
- **LOCALIZED ADIPOSITY/CELLULITE →** 3-5 MD-MATRIX injection sessions, 6-12 mL per session. The first three sessions at 15-day intervals, followed by sessions at 30-day intervals.
  - ✔ Intradermal and subcutaneous administration: insert the needle to a depth of 3-10 mm, depending on the thickness of the adipose fold. Perform microinjections of 0.1-0.2 mL per point, with the needle positioned perpendicular to the skin surface and within the adipose tissue layer, spacing injection points approximately 1 cm apart, until an appropriate volume is delivered according to the treated area. The use of 30G needles of appropriate length is recommended depending on the treatment goal: 4 mm needles may be sufficient to improve the appearance of cellulite; whereas 12 mm or 19 mm needles are recommended for the treatment of localized adiposity.
- **POST-PARTUM SCARS →** 3-5 MD-TISSUE injection sessions, 6-12 mL per session, at 15-day intervals, followed by sessions at 30-day intervals, depending on scar extent and depth.
  - ✔ Microinjection/wheal technique: insert the needle to a depth of 2-6 mm within the scar tissue and perform microinjections of 0.1-0.2 mL, up to a maximum volume of 12 mL in the treated area. Needles: 27-32G × 2-13 mm.
  - ✔ Fanning technique: insert the needle almost tangentially across the entire treatment area, then inject while simultaneously withdrawing the needle or cannula. Needles: 25-27G × 13 mm.
- **SCARS →** 3-5 MD-TISSUE injection sessions, 6-12 mL per session. The first three sessions at 15-day intervals, followed by sessions at 30-day intervals.
  - ✔ Step 1: using a 29G or 30G, 13 mm needle, insert tangentially into the scar to loosen the adhesion at its base (subcision or fibrotic debridement when feasible). Then inject 0.1 mL of product at this level using a retrograde linear technique.
  - ✔ Step 2: using a 30G, 4 mm needle, inject 0.05 mL of product into the superficial dermis (approximately 1-2 mm depth) to reach the most superficial portion of the scar. Cover the entire scar area with adjacent micro-wheals.
- **STRETCH MARKS →** 3-5 MD-TISSUE injection sessions, 8-10 mL per session, depending on extent and depth of the stretch marks. The first three sessions at 15-day intervals, followed by sessions at 30-day intervals.
  - ✔ Microinjection/wheal technique: insert the needle to a depth of 2-6 mm and perform microinjections of 0.1-0.2 mL, until the entire area is covered (RED STRETCH MARKS).
  - ✔ Fanning technique: using a 29G or 30G, 13 mm needle, insert tangentially into the stretch mark to loosen the adhesion at its base (when feasible). Then inject 0.1 mL of product using a retrograde linear technique (WHITE STRETCH MARKS).

Abdomen: target & protocol

Skin laxity treatment

- **TARGET:** MEN/WOMEN
- **PROTOCOL:**

1 tablet per day for 3 months

NEEDLE-BASED

3-5 injections of 6-10 mL (3-5 vials) at 15-30-day intervals, depending on the treatment performed and the extent of the area to be treated

NEEDLE-FREE

5-8 sessions using 6-10 mL (3-5 vials) at 10-day intervals, depending on the treatment performed and the extent of the area to be treated

Apply and massage daily on the treated areas

aesthetic GUNA



Abdomen: target & protocol

Localized adiposity/cellulite treatment

- **TARGET:** MEN/WOMEN
- **PROTOCOL:**

NEEDLE-BASED

3-5 injections of 6-12 mL (3-6 vials) at 15-30-day intervals, depending on the treatment performed and the extent of the area to be treated

NEEDLE-FREE

5-8 sessions using 6-12 mL (3-6 vials) at 10-day intervals, depending on the treatment performed and the extent of the area to be treated

Apply and massage daily on the treated areas

aesthetic GUNA

Abdomen: target & protocol

Scar treatment

- **TARGET:** MEN/WOMEN
- **PROTOCOL:**

1 tablet per day for 3 months

NEEDLE-BASED

3-5 injections of 6-12 mL (3-6 vials) at 15-30-day intervals, depending on the treatment performed and the extent of the area to be treated

NEEDLE-FREE

5-8 sessions using 6-12 mL (3-6 vials) at 10-day intervals, depending on the treatment performed and the extent of the area to be treated

Apply and massage daily on the treated areas

aesthetic GUNA

Abdomen: target & protocol

Stretch mark treatment

- **TARGET:** MEN/WOMEN
- **PROTOCOL:**

1 tablet per day for 3 months

NEEDLE-BASED

3-5 injections of 8-10 mL (4-5 vials) at 15-30-day intervals, depending on the treatment performed and the extent of the area to be treated

NEEDLE-FREE

5-8 sessions using 8-10 mL (4-5 vials) at 10-day intervals, depending on the treatment performed and the extent of the area to be treated

Apply and massage daily on the treated areas

aesthetic GUNA

Abdomen: study

Acumesotherapy in patients with localized abdominal adiposity

OBJECTIVE

To evaluate the effects of two combined techniques: acupuncture and MD-MATRIX mesotherapy, in patients with abdominal adiposity.

MATERIALS AND METHODS

- 23 women (27-53 years) with excess abdominal fat deposits
- 5 months of treatment, consisting of 10 weekly sessions of acupuncture + mesotherapy
- Subcutaneous injections were performed at a depth of 5-10 mm using 27G needles, injecting 0.2 mL of MD-MATRIX at the acupuncture points Ren12, Kd16, St25, Sp15, GB26, Ren6
- Umbilical circumference was measured at each session and at the end of therapy

MAIN RESULTS

All patients showed a reduction in abdominal circumference, ranging from 3 to 11.5 cm, with an overall mean reduction of 6.3 cm.

Circumference reduction (cm)	N. subjects	% patients
3.0 cm	2	8.7 %
4.5 cm	4	17.4 %
5.5 cm	3	13.0 %
6.5 cm	7	30.4 %
7.0 cm	4	17.4 %
8.5 cm	1	4.3 %
9.0 cm	1	4.3 %
11.5 cm	1	4.3 %

CONCLUSIONS

The combination of acupuncture and MD-MATRIX mesotherapy is effective and synergistic in reducing abdominal adiposity and in restoring the physiological balance of the treated tissue.

READ THE STUDY

Elenkova S., Pozharashka J. Acumesotherapy with guna MD-MATRIX in patients with localized abdominal adiposity. Physiological Regulating Medicine 2012.

aesthetic GUNA

Abdomen: study

Effectiveness of MD-TISSUE in pelvic pain caused by episiotomy and cesarean section scars: a pilot study

OBJECTIVE

To evaluate the effectiveness of MD-TISSUE collagen injections on pain and scar appearance in perineal lacerations, episiotomies, and cesarean section scars.

MATERIALS AND METHODS

- A randomized, controlled, single-blind pilot study involving 15 women
- The intervention group (n = 7) received 3-5 weekly MD-TISSUE injections (2 mL for episiotomies; 4 mL for cesarean scars);
- Baseline and 6-week follow-up assessments were performed using VAS, the McGill Pain Questionnaire, and the Vancouver Scar Scale/Patient Scar Assessment for scar appearance.

MAIN RESULTS

Patients treated with MD-TISSUE showed greater improvement in pain and scar appearance compared with the control group, which underwent conventional rehabilitation.

CONCLUSIONS

Collagen injections appear promising for the management of pelvic pain and scar appearance; however, further studies are needed to define cost-effectiveness and their role in the routine treatment of painful scars.

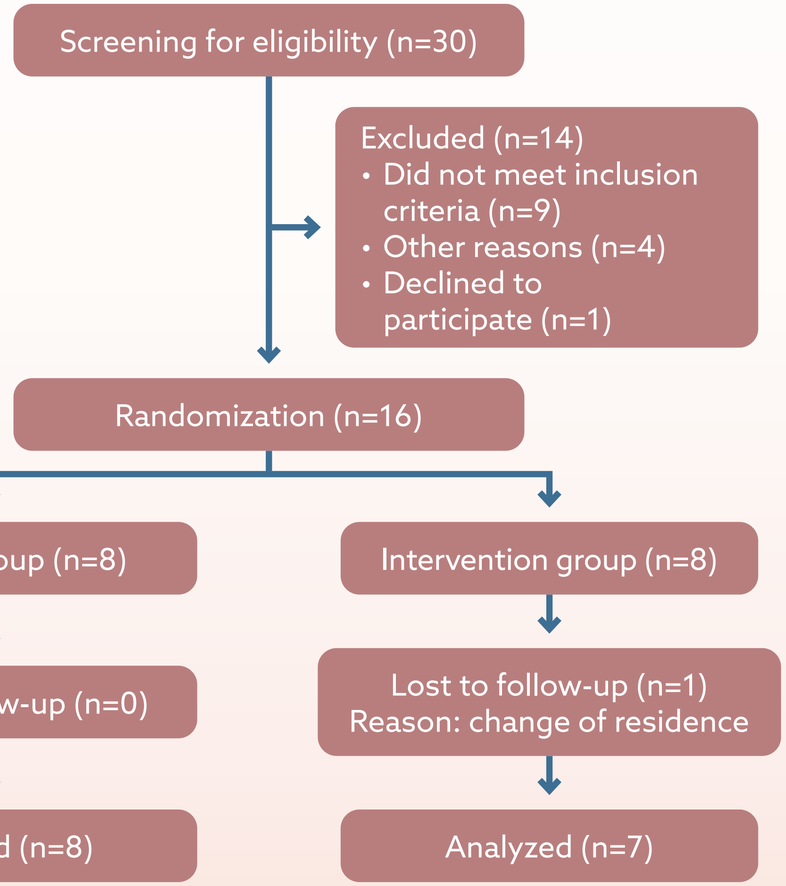

READ THE STUDY

Romero-Cullerés G., et al. Efficacy of collagen infiltrations in the pelvic pain caused by episiotomy and caesarean scars. Pilot randomized clinical trial. Rehabilitacion (Madr). 2021 Sep 3; S0048-7120(21)00059-1.

aesthetic GUNA

Gluteus/thigh: treatments

- **SKIN LAXITY →** 3-5 MD-TISSUE injection sessions, 6-10 mL per session. The first three sessions at 15-day intervals, followed by sessions at 30-day intervals.
  - ✔ Microinjection/wheal technique: insert the needle to a depth of 2-4 mm and perform microinjections of 0.02-0.05 mL, until the entire treatment area is covered.
  - ✔ Retrograde linear/fanning technique: insert the needle almost tangentially to the skin, then inject using a retrograde technique while simultaneously withdrawing the needle or cannula. Release approximately 0.05-0.1 mL per injection point.
- **LOCALIZED ADIPOSITY/CELLULITE →** 3-5 MD-MATRIX injection sessions, 6-12 mL per session. The first three sessions at 15-day intervals, followed by sessions at 30-day intervals.
  - ✔ Intradermal and subcutaneous administration: insert the needle to a depth of 3-10 mm, depending on the thickness of the adipose fold. Perform microinjections of 0.1-0.3 mL per point, with the needle positioned perpendicular to the skin surface and within the adipose tissue layer, spacing injection points approximately 1 cm apart, until an appropriate volume is delivered according to the treated area. The use of 30G needles of appropriate length is recommended depending on the treatment goal: 4 mm needles may be sufficient to improve the appearance of cellulite; whereas 12 mm or 19 mm needles are recommended for the treatment of localized adiposity.
- **STRETCH MARKS →** 3-5 MD-TISSUE injection sessions, 8-10 mL per session, depending on extent and depth of the stretch marks. The first three sessions at 15-day intervals, followed by sessions at 30-day intervals.
  - ✔ Microinjection/wheal technique: insert the needle to a depth of 2-6 mm and perform microinjections of 0.1-0.2 mL, until the entire area is covered (RED STRETCH MARKS).
  - ✔ Fanning technique: using a 29G or 30G, 13 mm needle, insert tangentially into the stretch mark to loosen the adhesion at its base (when feasible). Then inject 0.1 mL of product using a retrograde linear technique (WHITE STRETCH MARKS).

aesthetic GUNA

Gluteus/thigh: target & protocol

Skin laxity treatment

- **TARGET:** MEN/WOMEN
- **PROTOCOL:**

1 tablet per day for 3 months

NEEDLE-BASED

3-5 injections of 6-10 mL (3-5 vials) at 15-30-day intervals, depending on the treatment performed and the extent of the area to be treated

NEEDLE-FREE

5-8 sessions using 6-10 mL (3-5 vials) at 10-day intervals, depending on the treatment performed and the extent of the area to be treated

Apply and massage daily on the treated areas

aesthetic GUNA



Gluteus/thigh: target & protocol

Localized adiposity/cellulite treatment

- **TARGET:** MEN/WOMEN
- **PROTOCOL:**

NEEDLE-BASED

3-5 injections of 6-12 mL (3-6 vials) at 15-30-day intervals, depending on the treatment performed and the extent of the area to be treated

NEEDLE-FREE

5-8 sessions using 6-12 mL (3-6 vials) at 10-day intervals, depending on the treatment performed and the extent of the area to be treated

Apply and massage daily on the treated areas

aesthetic GUNA

Gluteus/thigh: target & protocol

Stretch mark treatment

- **TARGET:** MEN/WOMEN
- **PROTOCOL:**

1 tablet per day for 3 months

NEEDLE-BASED

3-5 injections of 8-10 mL (4-5 vials) at 15-30-day intervals, depending on the treatment performed and the extent of the area to be treated

NEEDLE-FREE

5-8 sessions using 8-10 mL (4-5 vials) at 10-day intervals, depending on the treatment performed and the extent of the area to be treated

Apply and massage daily on the treated areas

aesthetic GUNA

Gluteus/thigh: study

Injectable collagen acumesotherapy in patients with localized knee adiposity

OBJECTIVE

To evaluate the combined effectiveness of acupuncture and infiltrative collagen mesotherapy in the treatment of localized adiposity of the knees.

MATERIALS AND METHODS

- 22 women (25-51 years) underwent 10 weekly sessions of acumesotherapy.
- Subcutaneous injections of 0.3 mL of MD-MATRIX were performed using 27G needles at a depth of 5-10 mm.
- Circumference at the popliteal fold was measured before treatment, at the beginning of each subsequent session, and at the end of therapy.

MAIN RESULTS

- All patients showed a mean circumference reduction of 3.3 cm (from 42.68 cm to 39.36 cm).
- A reduction in pain was observed in patients with Hoffa's disease, along with an increase in self-esteem.

CONCLUSIONS

The combination of acupuncture and mesotherapy provides synergistic results, achieving correction of localized fat deposits and restoration of physiological balance in the treated tissue. Additional benefits include pain reduction in patients with Hoffa's disease and improved self-esteem.

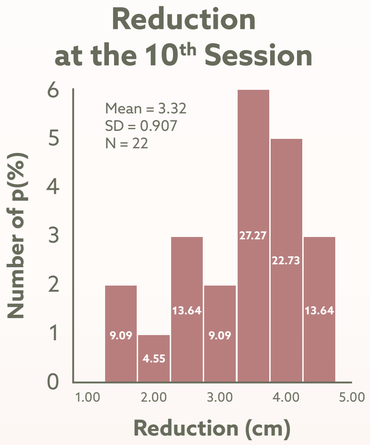

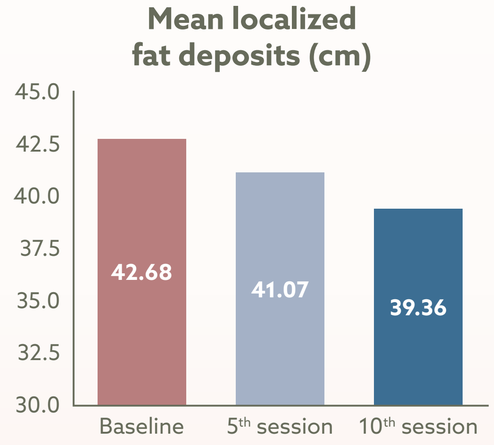

PRE-TREATMENT

POST-TREATMENT

READ THE STUDY

Elenkova S., Pozharashka J. Acumesotherapy with injectable collagen in patients with localized adiposity of the knees. ECIM 2012, Firenze.

aesthetic guna

Gluteus/thigh: study

Lassità skin laxity of the brachial region, knees, and abdomen

OBJECTIVE

To evaluate the effectiveness of injectable collagen as a biostimulatory and regenerative therapy to improve tissue quality, considering the natural decline of collagen starting from 30-35 years of age.

MATERIALS AND METHODS

- 10 patients underwent a cycle of 5 weekly injections (total volume: 6 mL; 4 mL MD-MATRIX + 2 mL MD-TISSUE).
- Assessment was performed using a skin tonicity scale and comparative pre- and post-treatment photographic analysis.

MAIN RESULTS

Treatment provided satisfactory outcomes in terms of tonicity recovery, improvement of skin histological structure, and a volumizing effect with increased dermal firmness.

CONCLUSIONS

Injectable collagen treatment proved to be well tolerated and cost-effective compared with other therapies. A clinically significant improvement in tissue repair and regeneration was observed and perceived by both patients and physicians.

PRE-TREATMENT

POST-TREATMENT

READ THE STUDY

Zazzaron M. Trattamento rigenerativo con collagene suino iniettivo per il rilassamento cutaneo. Conference poster AGORÀ 2025.

aesthetic GUNA

Beauthentic

The new language of the skin

Treatments and protocols in aesthetic medicine

TARGET > 40 YEARS

PLAY SURE doping free

SUMMARY PROTOCOLS >40 YEARS

aesthetic GUNA

Summary protocols > 40 years

Area	Indications	Number of sessions of collagen injections	Transcutaneous sessions with gunaphoresis (magnetophoresis)
Facial area	Wrinkles	4-7 (MD-TISSUE, 2-6 ml each)	6-10 (MD-TISSUE, 2-6 ml each)
	Skin hyperpigmentation	4-7 (MD-MATRIX, 2-6 ml each)	6-10 (MD-MATRIX, 2-6 ml each)
	Scars (post-acne, post-surgical)	3-5 (MD-TISSUE, 2-8 ml* each)	5-8 (MD-TISSUE, 2-8 ml* each)
Periorbital area	Wrinkles	4-7 (MD-TISSUE, 2-4 ml each)	6-10 (MD-TISSUE, 2-4 ml each)
	Marks and dark circles	4-7 (MD-MATRIX, 2 ml each)	6-10 (MD-MATRIX, 2 ml each)
	Under-eye bag	4-7 (MD-TISSUE, 2-4 ml each)	6-10 (MD-TISSUE, 2-4 ml each)
Neck	Wrinkles	4-7 (MD-TISSUE, 2-6 ml each)	6-10 (MD-TISSUE, 2-6 ml each)
	Skin hyperpigmentation	4-7 (MD-MATRIX, 2-6 ml each)	6-10 (MD-MATRIX, 2-6 ml each)
	Submental adiposity	4-7 (MD-MATRIX, 4-6 ml each)	6-10 (MD-MATRIX, 4-6 ml each)
	Scars	3-5 (MD-TISSUE, 2-8 ml each)	5-8 (MD-TISSUE, 2-8 ml each)
Décolleté/ breast area	Wrinkles	4-7 (MD-TISSUE, 2-8 ml each)	6-10 (MD-TISSUE, 2-8 ml each)
	Skin hyperpigmentation	4-7 (MD-MATRIX, 2-6 ml each)	6-10 (MD-MATRIX, 2-6 ml each)
	Scars	3-5 (MD-TISSUE, 2-8 ml* each)	5-8 (MD-TISSUE, 2-8 ml* each)
	Stretch marks	3-5 (MD-TISSUE, 6-10 ml* each)	5-8 (MD-TISSUE, 6-10 ml* each)
Arms	Skin laxity	4-7 (MD-TISSUE, 4-10 ml each)	6-10 (MD-TISSUE, 4-10 ml each)
	Localized adiposity	4-7 (MD-MATRIX, 4-10 ml each)	6-10 (MD-MATRIX, 4-10 ml each)
	Scars/Stretch marks	3-5 (MD-TISSUE, 8-10 ml* each)	5-8 (MD-TISSUE, 8-10 ml* each)
Hands	Skin laxity	4-7 (MD-TISSUE, 4-8 ml each)	6-10 (MD-TISSUE, 4-8 ml each)
	Skin hyperpigmentation	4-7 (MD-MATRIX, 2-6 ml each)	6-10 (MD-MATRIX, 2-6 ml each)
Abdomen	Skin laxity	4-7 (MD-TISSUE, 6-10 ml each)	6-10 (MD-TISSUE, 6-10 ml each)
	Localized adiposity/cellulite	4-7 (MD-MATRIX, 6-12 ml each)	6-10 (MD-MATRIX, 6-12 ml each)
	Scars	3-5 (MD-TISSUE, 6-12 ml* each)	5-8 (MD-TISSUE, 6-12 ml* each)
	Stretch marks	3-5 (MD-TISSUE, 8-10 ml* each)	5-8 (MD-TISSUE, 8-10 ml* each)
Gluteus/thighs	Skin laxity	4-7 (MD-TISSUE, 6-10 ml each)	6-10 (MD-TISSUE, 6-10 ml each)
	Localized adiposity/cellulite	4-7 (MD-MATRIX, 6-12 ml each)	6-10 (MD-MATRIX, 6-12 ml each)
	Stretch marks	3-5 (MD-TISSUE, 8-10 ml* each)	5-8 (MD-TISSUE, 8-10 ml* each)

*Depending on the extent and depth of the stretch marks.

Facial area: treatments

- **WRINKLES →** 4-7 MD-TISSUE injection sessions, 2-6 mL per session. The first three sessions at 15-day intervals, followed by sessions at 30-day intervals.
  - ✔ Microinjection/wheal technique: insert the needle to a depth of 1-3 mm and perform microinjections of 0.02-0.05 mL, placed adjacent to each other at 1-1.5 cm intervals and at a depth of 1-2 mm, up to a total volume of 8 mL in the treated area. Close micro-deposits may be performed along the main axis of static wrinkles.
  - ✔ Retrograde linear/fanning technique: insert the needle almost tangentially to the skin across the entire treatment area, then inject using a retrograde technique while simultaneously withdrawing the needle or cannula. Release approximately 0.05 mL per injection point.
- **SKIN HYPERPIGMENTATION →** 4-7 MD-MATRIX injection sessions, 2-6 mL per session. The first three sessions at 15-day intervals, followed by sessions at 30-day intervals.
  - ✔ Intradermal and subcutaneous administration: insert the needle to a depth of 1-3 mm and perform microinjections of 0.02-0.05 mL per point, up to a maximum total volume of 6 mL in the treated area.
- **SCARS/ACNE →** 3-5 MD-TISSUE injection sessions, 2-8 mL per session, depending on scar extent and depth. The first three sessions at 15-day intervals, followed by sessions at 30-day intervals.
  - ✔ Step 1: using a 29G or 30G, 13 mm needle, insert tangentially into the scar to loosen the adhesion at its base (subcision or fibrotic debridement when feasible). Then inject 0.1 mL of product at this level using a retrograde linear technique.
  - ✔ Step 2: using a 30G, 4 mm needle, inject 0.05 mL of product into the superficial dermis (approximately 1-2 mm depth) to reach the most superficial portion of the scar. Cover the entire scar area with adjacent micro-wheals.

Facial area: target & protocol

Wrinkle treatment

- **TARGET:** MEN/WOMEN
- **PROTOCOL:**

1-2 tablets per day for 3 months

NEEDLE-BASED

4-7 injections of 2-6 mL (1-3 vials) at 15-30-day intervals, depending on the treatment performed and the extent of the area to be treated

NEEDLE-FREE

6-10 sessions using 2-6 mL (1-3 vials) at 10-day intervals, depending on the treatment performed and the extent of the area to be treated

Apply and massage daily on the treated areas

aesthetic GUNA

Facial area: target & protocol

Skin hyperpigmentation treatment

- **TARGET:** WOMEN
- **PROTOCOL:**

3 tablets per day for 3 months

NEEDLE-BASED

4-7 injections of 2-6 mL (1-3 vials) at 15-30-day intervals, depending on the treatment performed and the extent of the area to be treated

NEEDLE-FREE

6-10 sessions using 2-6 mL (1-3 vials) at 10-day intervals, depending on the treatment performed and the extent of the area to be treated

Apply and massage daily on the treated areas

aesthetic GUNA

Facial area: target & protocol

Scar/acne treatment

- **TARGET:** MEN/WOMEN
- **PROTOCOL:**

1 tablet per day for 3 months

NEEDLE-BASED

3-5 injections of 2-8 mL (1-4 vials) at 15-30-day intervals, depending on the treatment performed and the extent of the area to be treated

NEEDLE-FREE

5-8 sessions using 2-8 mL (1-4 vials) at 10-day intervals, depending on the treatment performed and the extent of the area to be treated

Apply and massage daily on the treated areas

aesthetic GUNA

Facial area: study

Biorevitalization with MD-TISSUE

OBJECTIVE

To evaluate the effectiveness of the medical device MD-TISSUE as a facial revitalizing treatment in improving skin elasticity and reducing wrinkles without altering facial expression.

MATERIALS AND METHODS

- 15 volunteers (33-50 years old) were treated with 6 weekly injection sessions into the nasolabial folds using a retrograde linear technique (27G needle).
- Outcomes were assessed using: photographic documentation (Visioface Quick), wrinkle volume calculation, elasticity measurement using an elastometer (at T0, T3, and T6), and patient satisfaction questionnaire.

MAIN RESULTS

- After 3 weeks of treatment, 11 out of 15 volunteers (73.33%) showed increased skin elasticity compared to baseline.
- Wrinkle volume was reduced by an average of 2.7% after 3 weeks and 13.4% after 6 weeks of treatment.

CONCLUSIONS

- MD-TISSUE demonstrated a good ability to improve skin elasticity and to reduce wrinkle volume.
- The fluid texture of the product is suitable for treatments of the neck, décolleté, and dorsal surface of the hands. Facial applications may include different techniques such as microinjections, injections at acupuncture points, and rejuvenation of the periocular and forehead areas.

READ THE STUDY

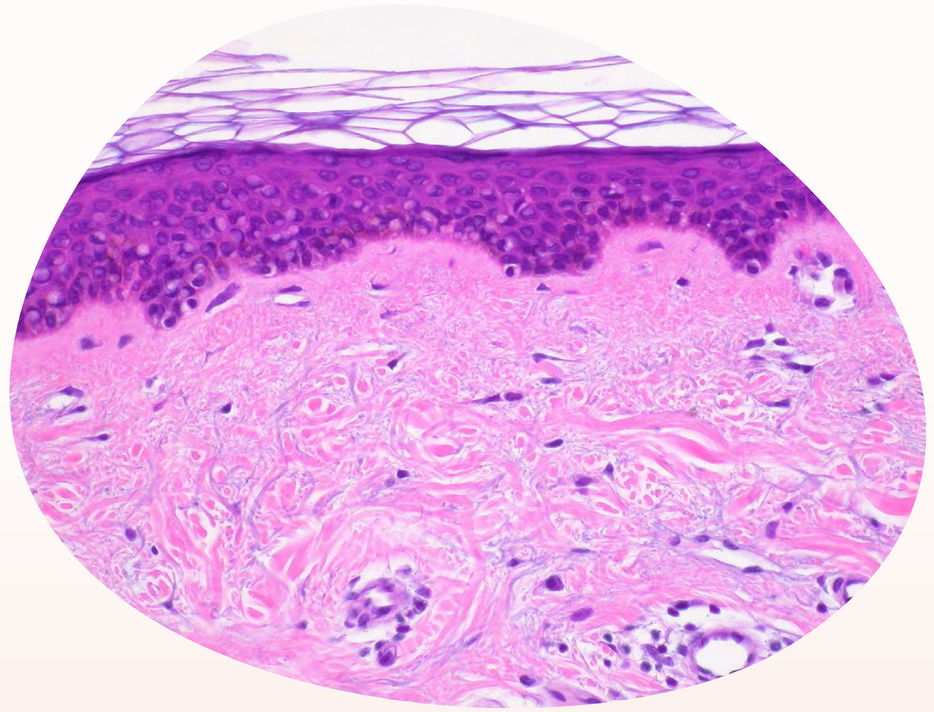

MD-TISSUE is a product designed for soft tissues, capable of creating a **protective barrier** against free radicals and **counteracting the physiological aging** of connective tissue. These properties are essential for an effective tissue **revitalizing treatment**.

Falconi Klein E. Face Revitalization - Biolifting With MD-TISSUE. Physiological Regulating Medicine 2012.

aesthetic GUNA

Facial area: study

Facial dermo-aesthetic medicine: integrated therapy

OBJECTIVE

To evaluate the effectiveness of a multisystemic approach combining Bioregulatory Systems Medicine (BrSM) and nutraceuticals in the prevention and treatment of skin aging.

MATERIALS AND METHODS

20 women (35-70 years) were treated with multilevel protocols including **biodetoxification** (drainage, hydration, systemic anti-aging, body detox) and **biostimulation** (local injections, in selected cases microneedling radiofrequency, biorevitalizing acids, carboxytherapy), supported by BrSM and MADE, GUNA-Collagen, and MD-TISSUE preparations. Assessments were performed using questionnaires and photographic documentation.

MAIN RESULTS

A marked improvement in overall psychophysical well-being was observed, with no adverse reactions and excellent outpatient and home-treatment compliance.

CONCLUSIONS

The multisystemic approach combining BrSM and nutraceuticals proved to be safe and effective in the prevention and treatment of skin aging.

PRE-TREATMENT POST-TREATMENT

Female, 53 years old. The patient underwent 5 sessions of carboxytherapy, followed by **weekly biostimulation**. A significant reduction in micro- and macro-wrinkles, particularly in the periocular area, was observed, along with an overall improvement in skin texture.

READ THE STUDY

Felloni G. Dermoaesthetic Facial Medicine – Integrated Therapy. Physiological Regulating Medicine 2023.

aesthetic GUNA

Facial area: study

Cervico-facial rejuvenation

OBJECTIVE

To evaluate the outcomes of injectable heterologous collagen treatment (MD-TISSUE) in improving wrinkles and skin quality of the face and neck.

MATERIALS AND METHODS

- 12 patients (45-70 years, mean age 53) were treated with MD-TISSUE (collagen combined with vitamins C, B1-B2-B6, and magnesium gluconate) using a retrograde linear technique (27-30G needles).
- 2-6 sessions per year (mean 3), spaced 3-8 weeks apart.

MAIN RESULTS

- Aesthetic improvement of wrinkles was observed in all cases, documented photographically.
- Mean patient satisfaction score: 8.5/10.

CONCLUSIONS

Biostimulation with MD-TISSUE helps counteract the physiological deterioration of the skin and subdermal connective tissue, offering an optimal cost-benefit profile with no clinically relevant product-related complications.

PRE-TREATMENT

POST-TREATMENT

READ THE STUDY

Riggio E. Medical device a base di collagene, MD-TISSUE, nel ringiovanimento cervico-facciale. Conference poster SIME 2025.

aesthetic GUNA

Facial area: study

Treatment of post-adolescence acne scarring

OBJECTIVE

To evaluate the efficacy and tolerability of MD-TISSUE in improving post-acne scars in adolescents.

MATERIALS AND METHODS

- 5 adolescents (15-17 years) received five weekly MD-TISSUE injections using a mesotherapy technique (13 mm, 30G needle), combined with oral and topical Dermoguna therapy.
- Assessment was performed through clinical and photographic evaluation, supported by patient satisfaction scales.

MAIN RESULTS

Patients showed a significant aesthetic improvement in scar depth, smoothness, and texture, confirmed by satisfaction scores (mean score: 9/10), with no allergic reactions or treatment-related discomfort.

CONCLUSIONS

MD-TISSUE injection, combined with antioxidant excipients (vitamins C, B1, B2, B6, and magnesium gluconate), represents a safe and effective therapy for the treatment of post-acne scarring in adolescents.

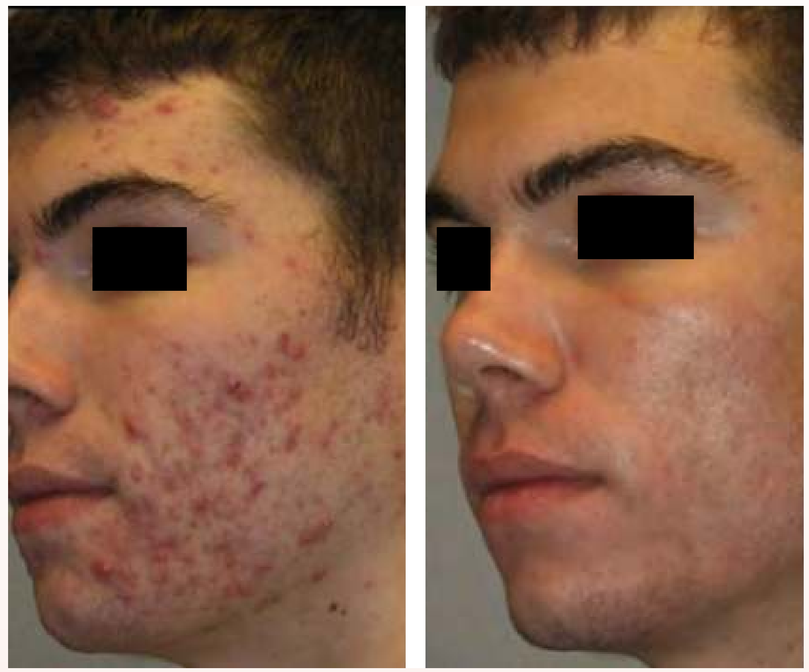

PRE-TREATMENT | POST-TREATMENT

READ THE STUDY

Squillante A. Trattamento con collagene infiltrativo suino in esiti cicatriziali post acne adolescenziale. Conference poster AGORÀ 2025.

Facial area: study

Biostimulation and dermal biorestructuring in skin aging

OBJECTIVE

To evaluate the effectiveness of collagen biostimulation in improving skin aging in patients over 35 years.

MATERIALS AND METHODS

- 10 patients received 4 biweekly injections of 2 mL of MD-TISSUE to the face, neck, and periocular area.
- Assessments were performed through photographic documentation and aesthetic satisfaction scales.

MAIN RESULTS

70% of patients showed functional and aesthetic improvement, with wrinkle smoothing, increased skin tone and elasticity, and improved extracellular matrix plasticity.

CONCLUSIONS

MD-TISSUE is effective in dermal biorestructuring in adults over 35 years, promoting neocollagenesis and improving skin tone, elasticity, and natural appearance.

PRE-TREATMENT | POST-TREATMENT

READ THE STUDY

Turchi A. Biostimolazione e bioristrutturazione dermica con collagene porcino nell'invecchiamento cutaneo. Conference poster AGORÀ 2025.

aesthetic GUNA

Periorbital area: treatment

- **WRINKLES →** 4-7 MD-TISSUE injection sessions, 2-4 mL per session. The first three sessions at 15-day intervals, followed by sessions at 30-day intervals.
  - ✔ Microinjection/wheal technique: insert the needle to a depth of 1-2 mm and perform microinjections of 0.02-0.05 mL, up to a total volume of 4 mL in the treated area.
  - ✔ Retrograde linear technique: using a 13 mm needle, insert almost tangentially to the skin across the entire treatment area. Inject using a retrograde technique while simultaneously withdrawing the needle or cannula. Release approximately 0.05 mL per injection point.
- **INFRAORBITAL HYPERPIGMENTATION (DARK CIRCLES) →** 4-7 MD-MATRIX injection sessions, 2 mL per session. The first three sessions at 15-day intervals, followed by sessions at 30-day intervals.
  - ✔ Intradermal and subcutaneous administration: insert the needle to a depth of 1-4 mm and perform microinjections of 0.05 mL per point. The total injected volume varies according to the extent of the pigmented area.
- **UNDER-EYE BAGS →** 4-7 MD-TISSUE injection sessions, 2-4 mL per session. The first three sessions at 15-day intervals, followed by sessions at 30-day intervals.
  - ✔ Microinjection/wheal technique: insert the needle to a depth of 1-3 mm and perform microinjections of 0.02-0.05 mL, up to a total volume of 4 mL in the treated area.

Periorbital area: target & protocol

Periorbital wrinkle treatment

- **TARGET:** MEN/WOMEN
- **PROTOCOL:**

1-2 tablets per day for 3 months

NEEDLE-BASED

4-7 injections of 2-4 mL (1-2 vials) at 15-30-day intervals, depending on the treatment performed and the extent of the area to be treated

NEEDLE-FREE

6-10 sessions using 2-4 mL (1-2 vials) at 10-day intervals, depending on the treatment performed and the extent of the area to be treated

Apply and massage daily on the treated areas

aesthetic GUNA

Periorbital area: target & protocol

Infraorbital hyperpigmentation and mark treatment (dark circles)

- **TARGET:** MEN/WOMEN
- **PROTOCOL:**

NEEDLE-BASED

NEEDLE-FREE

3 tablets per day for 3 months

4-7 injections of 2 mL (1 vial) at 15-30-day intervals, depending on the treatment performed and the extent of the area to be treated

6-10 sessions using 2 mL (1 vial) at 10-day intervals, depending on the treatment performed and the extent of the area to be treated

Apply and massage daily on the treated areas

aesthetic GUNA

Periorbital area: target & protocol

Under-eye bag treatment

- **TARGET:** MEN/WOMEN
- **PROTOCOL:**

1-2 tablets per day for 3 months

NEEDLE-BASED

4-7 injections of 2-4 mL (1-2 vials) at 15-30-day intervals, depending on the treatment performed and the extent of the area to be treated

NEEDLE-FREE

6-10 sessions using 2-4 mL (1-2 vials) at 10-day intervals, depending on the treatment performed and the extent of the area to be treated

Apply and massage daily on the treated areas

aesthetic GUNA

Periorbital area: study
Dark circle treatment

OBJECTIVE
To evaluate the effectiveness of a non-invasive regenerative protocol based on MD-MATRIX in improving dark circles in young and adult patients.

MATERIALS AND METHODS
- 10 patients (25-60 years) received 5 weekly injections of 4 mL of MD-MATRIX (citric acid and nicotinamide) using fanning and drop techniques (13 mm, 30G needle), combined with topical therapy using Dermoguna serum and Arnica.
- Assessment was performed using photographic documentation and physician-patient satisfaction scales.

MAIN RESULTS
Tissue improvement was observed, particularly in cases of dark circles associated with tear trough volume loss, with a camouflaging effect on pigmented dark circles and high tolerability.

CONCLUSIONS
The non-invasive regenerative MD-MATRIX protocol represents a promising therapeutic option for the treatment of dark circles related to volume loss, while adjunctive topical therapy also supported pigmented forms.

PRE-TREATMENT | POST-TREATMENT

READ THE STUDY

Squillante A. Trattamento delle occhiaie con collagene infiltrativo suino: approccio rigenerativo peruna zona periorbitale più giovane e luminosa. Conference poster AGORÀ 2025.

aesthetic GUNA

Periorbital area: study

Biostimulation of the periorbital area

OBJECTIVE

To evaluate the effectiveness of a combined MD-MATRIX and MD-TISSUE protocol in reducing dark circles in adult women.

MATERIALS AND METHODS

- 6 patients (30-50 years) received five weekly injections: the first two sessions with MD-MATRIX (collagen, citric acid, nicotinamide) to prepare the extracellular matrix, followed by three sessions with MD-TISSUE (collagen, vitamins C, B1, B2, B6, and magnesium gluconate) to target the tissues and enhance the regenerative and biostimulatory response.
- Assessment was performed using physician and patient satisfaction scales.

MAIN RESULTS

- Treatment led to an increase in dermal-epidermal thickness and a reduction in the visibility of superficial vessels and hyperchromic areas.
- Mean satisfaction scores were 8/10 for patients and 10/10 for physicians.

CONCLUSIONS

The combined MD-MATRIX and MD-TISSUE protocol promotes periocular biostimulation, improving skin tone, firmness, and radiance.

PRE-TREATMENT

POST-TREATMENT

READ THE STUDY

Turchi A. Efficacia della biostimolazione con collagene iniettivo suino nel trattamento delle occhiaie perioculari. Conference poster AGORÀ 2025.

aesthetic GUNA

Periorbital area: study

Periocular area treatment

OBJECTIVE

To evaluate the effectiveness of a non-invasive treatment of the periocular area, prone to early aging, characterized by skin laxity, roughness, and loss of tone.

MATERIALS AND METHODS

10 patients received 5 weekly sessions of transdermal delivery of MD-MATRIX (collagen, citric acid, and nicotinamide) using resonance magnetophoresis. Treatment was integrated with oral intake of Neorland® dermal collagen, rich in exosomes, horsetail extract, and vitamins C, E, B2, and niacin, as well as topical application of a serum containing the same collagen, vitamins C and E, and *Rosa Centifolia* flower water.

MAIN RESULTS

Post-treatment evaluation showed increased skin firmness, reduction of static wrinkles and dark circles, with no side effects. The treatment was well tolerated and easily performed, including during the summer period.

CONCLUSIONS

Transdermal delivery of collagen via magnetophoresis proved effective in improving periocular skin quality, offering a safe, effective, and well-tolerated therapeutic option.

READ THE STUDY

Ciampa S. Trattamento non invasivo della zona perioculare con collagene suino: dalle rughe al "Sorriso nello sguardo". Conference poster AGORÀ 2025.

aesthetic GUNA

Neck: treatment

- **WRINKLES →** 4-7 MD-TISSUE injection sessions, 2-6 mL per session. The first three sessions at 15-day intervals, followed by sessions at 30-day intervals.
  - ✔ Microinjection/wheal technique: insert the needle to a depth of 2-4 mm and perform adjacent microinjections of 0.05-0.1 mL, up to a total volume of 6 mL, to cover the entire treatment area.
  - ✔ Retrograde linear technique along horizontal neck wrinkles: insert the needle almost tangentially to the skin, then inject while simultaneously withdrawing the needle or cannula. Release approximately 0.05-0.1 mL per injection point.
- **SKIN HYPERPIGMENTATION →** 4-7 MD-MATRIX injection sessions, 2-6 mL per session. The first three sessions at 15-day intervals, followed by sessions at 30-day intervals.
  - ✔ Intradermal and subcutaneous administration:insert the needle to a depth of 2-4 mm and perform microinjections of 0.05-0.1 mL, spaced 0.5-1 cm apart, to cover the entire treatment area.
- **SUBMENTAL ADIPOSITY →** 4-7 MD-MATRIX injection sessions, 4-6 mL per session. The first three sessions at 15-day intervals, followed by sessions at 30-day intervals.
  - ✔ Intradermal and subcutaneous administration: insert the needle to a depth of 3-8 mm, depending on the submental skin fold, and perform microinjections of 0.1-0.2 mL per point, spaced approximately 1 cm apart, until an appropriate volume is delivered according to the treated area.
- **SCARS →** 3-5 MD-TISSUE injection sessions, 2-8 mL per session. The first three sessions at 15-day intervals, followed by sessions at 30-day intervals.
  - ✔ Step 1: using a 29G or 30G, 13 mm needle, insert tangentially into the scar to loosen the adhesion at its base (subcision or fibrotic debridement when feasible). Then inject 0.1 mL of product at this level using a retrograde linear technique.
  - ✔ Step 2: using a 30G, 4 mm needle, inject 0.05 mL of product into the superficial dermis (approximately 1-2 mm depth) to reach the most superficial portion of the scar. Cover the entire scar area with adjacent micro-wheals.

aesthetic GUNA

Neck: target & protocol

Wrinkle treatment

- **TARGET:** MEN/WOMEN
- **PROTOCOL:**

1-2 tablets per day for 3 months

NEEDLE-BASED

4-7 injections of 2-6 mL (1-3 vials) at 15-30-day intervals, depending on the treatment performed and the extent of the area to be treated

NEEDLE-FREE

6-10 sessions using 2-6 mL (1-3 vials) at 10-day intervals, depending on the treatment performed and the extent of the area to be treated

Apply and massage daily on the treated areas

aesthetic GUNA

Neck: target & protocol

Skin hyperpigmentation treatment

- **TARGET:** WOMEN
- **PROTOCOL:**

3 tablets per day for 3 months

NEEDLE-BASED

4-7 injections of 2-6 mL (1-3 vials) at 15-30-day intervals, depending on the treatment performed and the extent of the area to be treated

NEEDLE-FREE

6-10 sessions using 2-6 mL (1-3 vials) at 10-day intervals, depending on the treatment performed and the extent of the area to be treated

Apply and massage daily on the treated areas

aesthetic GUNA

Neck: target & protocol

Submental adiposity treatment

- **TARGET:** MEN/WOMEN
- **PROTOCOL:**

1 tablet per day for 3 months

NEEDLE-BASED

4-7 injections of 4-6 mL (2-3 vials) at 15-30-day intervals, depending on the treatment performed and the extent of the area to be treated

NEEDLE-FREE

6-10 sessions using 4-6 mL (2-3 vials) at 10-day intervals, depending on the treatment performed and the extent of the area to be treated

Apply and massage daily on the treated areas

aesthetic GUNA

Neck: target & protocol

Neck scar treatment

- **TARGET:** MEN/WOMEN
- **PROTOCOL:**

1 tablet per day for 3 months

NEEDLE-BASED

3-5 injections of 2-8 mL (1-4 vials) at 15-30-day intervals, depending on the treatment performed and the extent of the area to be treated

NEEDLE-FREE

5-8 sessions using 2-8 mL (1-4 vials) at 10-day intervals, depending on the treatment performed and the extent of the area to be treated

Apply and massage daily on the treated areas

aesthetic GUNA

Décolleté/breast area: treatments

- **WRINKLES →** 4-7 MD-TISSUE injection sessions, 2-8 mL per session. The first three sessions at 15-day intervals, followed by sessions at 30-day intervals.
  - ✔ Microinjection/wheal technique: insert the needle to a depth of 2-4 mm and perform adjacent microinjections of 0.05-0.1 mL, up to a total volume of 8 mL, to cover the entire treatment area.
  - ✔ Retrograde linear technique: in addition to the above biostimulation technique, the retrograde linear technique is recommended for the treatment of radial wrinkles. insert the needle almost tangentially to the skin, then inject using a retrograde technique while simultaneously withdrawing the needle or cannula. Release approximately 0.05-0.1 mL per injection point.
- **SKIN HYPERPIGMENTATION →** 4-7 MD-MATRIX injection sessions, 2-6 mL per session. The first three sessions at 15-day intervals, followed by sessions at 30-day intervals.
  - ✔ Intradermal and subcutaneous administration: insert the needle to a depth of 2-4 mm and perform microinjections of 0.05-0.1 mL, until the entire pigmented area is covered.
- **SCARS →** 3-5 MD-TISSUE injection sessions, 2-8 mL per session, depending on scar extent and depth. The first three sessions at 15-day intervals, followed by sessions at 30-day intervals.
  - ✔ Step 1: using a 29G or 30G, 13 mm needle, insert tangentially into the scar to loosen the adhesion at its base (subcision or fibrotic debridement when feasible). Then inject 0.1 mL of product at this level using a retrograde linear technique.
  - ✔ Step 2: using a 30G, 4 mm needle, inject 0.05 mL of product into the superficial dermis (approximately 1-2 mm depth) to reach the most superficial portion of the scar. Cover the entire scar area with adjacent micro-wheals.
- **STRETCH MARKS →** 3-5 MD-TISSUE injection sessions, 6-10 mL per session, depending on extent and depth of the stretch marks. The first three sessions at 15-day intervals, followed by sessions at 30-day intervals.
  - ✔ Microinjection/wheal technique: insert the needle to a depth of 2-6 mm and perform microinjections of 0.1-0.2 mL, until the entire area is covered (RED STRETCH MARKS).
  - ✔ Fanning technique: using a 29G or 30G, 13 mm needle, insert tangentially into the stretch mark to loosen the adhesion at its base (when feasible). Then inject 0.1 mL of product using a retrograde linear technique (WHITE STRETCH MARKS).

Décolleté/breast area: target & protocol

Wrinkle treatment

- **TARGET:** WOMEN
- **PROTOCOL:**

1-2 tablets per day for 3 months

NEEDLE-BASED

4-7 injections of 2-8 mL (1-4 vials) at 15-30-day intervals, depending on the treatment performed and the extent of the area to be treated

NEEDLE-FREE

6-10 sessions using 2-8 mL (1-4 vials) at 10-day intervals, depending on the treatment performed and the extent of the area to be treated

Apply and massage daily on the treated areas

aesthetic GUNA

Décolleté/breast area: target & protocol

Skin hyperpigmentation treatment

- **TARGET:** WOMEN
- **PROTOCOL:**

3 tablets per day for 3 months

NEEDLE-BASED

4-7 injections of 2-6 mL (1-3 vials) at 15-30-day intervals, depending on the treatment performed and the extent of the area to be treated

NEEDLE-FREE

6-10 sessions using 2-6 mL (1-3 vials) at 10-day intervals, depending on the treatment performed and the extent of the area to be treated

Apply and massage daily on the treated areas

aesthetic GUNA

Décolleté/breast area: target & protocol

Décolleté scar treatment

- **TARGET:** WOMEN
- **PROTOCOL:**

1 tablet per day for 3 months

NEEDLE-BASED

3-5 injections of 2-8 mL (1-4 vials) at 15-30-day intervals, depending on the treatment performed and the extent of the area to be treated

NEEDLE-FREE

5-8 sessions using 2-8 mL (1-4 vials) at 10-day intervals, depending on the treatment performed and the extent of the area to be treated

Apply and massage daily on the treated areas

aesthetic GUNA

Décolleté/breast area: target & protocol

Stretch mark treatment

- **TARGET:** WOMEN
- **PROTOCOL:**

1 tablet per day for 3 months

NEEDLE-BASED

3-5 injections of 6-10 mL (3-5 vials) at 15-30-day intervals, depending on the treatment performed and the extent of the area to be treated

NEEDLE-FREE

5-8 sessions using 6-10 mL (3-5 vials) at 10-day intervals, depending on the treatment performed and the extent of the area to be treated

Apply and massage daily on the treated areas

aesthetic GUNA

Décolleté/breast area: study

Complicated breast surgery scar

OBJECTIVE

To evaluate the effectiveness of MD-TISSUE injections in improving the aesthetic and functional outcome of a healed complex surgical scar.

MATERIALS AND METHODS

- A 44-year-old patient with a post-quadrantectomy breast scar, complicated by a sub-scar breast abscess that required drainage and subsequent healing by secondary intention.
- Subcutaneous injectable mesotherapy with MD-TISSUE collagen was initiated every 7 days for a total of 5 sessions.Follow-up evaluations were performed 3 and 10 days after completion of treatment.
- The Vancouver Scar Scale was administered before treatment and at follow-up visits.

MAIN RESULTS

Treatment led to an improvement in pigmentation and scar uniformity, with reduced adhesions to underlying tissues in the central portion of the scar (Vancouver Scale score: 4).

CONCLUSIONS

Collagen injections represent an innovative, minimally invasive therapeutic option with a favorable cost-benefit profile for the treatment of surgical scars.

PRE-TREATMENT

POST-TREATMENT

READ THE STUDY

Sgarbi L. Collagene suino di tipo i ad uso iniettivo sottocutaneo nel trattamento di cicatrice chirurgica mammaria complicata. Conference poster SIME 2025.

aesthetic GUNA

Arms: treatments

- **SKIN LAXITY →** 4-7 MD-TISSUE injection sessions, 4-10 mL per session. The first three sessions at 15-day intervals, followed by sessions at 30-day intervals.
  - ✔ Microinjection/wheal technique: insert the needle to a depth of 2-4 mm and perform microinjections of 0.02-0.05 mL, until the entire treatment area is covered.
  - ✔ Retrograde linear/fanning technique: insert the needle almost tangentially to the skin, then inject using a retrograde technique while simultaneously withdrawing the needle or cannula. Release approximately 0.05-0.1 mL per injection point.
- **LOCALIZED ADIPOSITY →** 4-7 MD-MATRIX injection sessions, 4-10 mL per session. The first three sessions at 15-day intervals, followed by sessions at 30-day intervals.
  - ✔ Intradermal and subcutaneous administration: insert the needle to a depth of 3-10 mm, depending on the thickness of the adipose fold, with the needle positioned perpendicular to the skin surface and within the adipose tissue layer. Space injection points approximately 1 cm apart until an appropriate volume is delivered according to the treated area. The use of 30G needles of appropriate length is recommended depending on the treatment goal: 4 mm needles may be sufficient to improve the appearance of localized adiposity; whereas 12 mm or 19 mm needles are recommended for the treatment of localized adiposity.
- **STRETCH MARKS →** 3-5 MD-TISSUE injection sessions, 8-10 mL per session, depending on extent and depth of the stretch marks. The first three sessions at 15-day intervals, followed by sessions at 30-day intervals.
  - ✔ Microinjection/wheal technique: insert the needle to a depth of 2-6 mm and perform microinjections of 0.1-0.2 mL, until the entire area is covered (RED STRETCH MARKS).
  - ✔ Fanning technique: using a 29G or 30G, 13 mm needle, insert tangentially into the stretch mark to loosen the adhesion at its base (when feasible). Then inject 0.1 mL of product using a retrograde linear technique (WHITE STRETCH MARKS).

Arms: target & protocol

Skin laxity treatment

- **TARGET:** MEN/WOMEN
- **PROTOCOL:**

NEEDLE-BASED

4-7 injections of 4-10 mL (2-5 vials) at 15-30-day intervals, depending on the treatment performed and the extent of the area to be treated

NEEDLE-FREE

6-10 sessions using 4-10 mL (2-5 vials) at 10-day intervals, depending on the treatment performed and the extent of the area to be treated

Apply and massage daily on the treated areas

aesthetic GUNA

Arms: target & protocol

Localized adiposity treatment

- **TARGET:** MEN/WOMEN
- **PROTOCOL:**

NEEDLE-BASED

4-7 injections of 4-10 mL (2-5 vials) at 15-30-day intervals, depending on the treatment performed and the extent of the area to be treated

NEEDLE-FREE

6-10 sessions using 4-10 mL (2-5 vials) at 10-day intervals, depending on the treatment performed and the extent of the area to be treated

Apply and massage daily on the treated areas

aesthetic GUNA

Arms: target & protocol

Stretch mark treatment

- **TARGET:** MEN/WOMEN
- **PROTOCOL:**

1 tablet per day for 3 months

NEEDLE-BASED

3-5 injections of 8-10 mL (4-5 vials) at 15-30-day intervals, depending on the treatment performed and the extent of the area to be treated

NEEDLE-FREE

5-8 sessions using 8-10 mL (4-5 vials) at 10-day intervals, depending on the treatment performed and the extent of the area to be treated

Apply and massage daily on the treated areas

aesthetic GUNA

Hands: treatments

- **SKIN LAXITY →** 4-7 MD-TISSUE injection sessions, 4-8 mL per session. The first three sessions at 15-day intervals, followed by sessions at 30-day intervals.
  - ✔ Microinjection/wheal technique: insert the needle to a depth of 2-3 mm and perform microinjections of 0.02-0.05 mL, until the entire treatment area is covered.
  - ✔ Retrograde linear cannula technique: insert a 25G or 23G cannula through the entry point created with the introducer needle. Position the cannula parallel to the skin surface, then inject using a retrograde technique while simultaneously withdrawing the cannula. Release approximately 0.02 mL per injection point.
- **SKIN HYPERPIGMENTATION →** 4-7 MD-MATRIX injection sessions, 2-6 mL per session. The first three sessions at 15-day intervals, followed by sessions at 30-day intervals.
  - ✔ Intradermal and subcutaneous administration: insert the needle to a depth of 2-4 mm and perform microinjections of 0.05-0.1 mL, until the entire pigmented area is covered.

Hands: target & protocol

Skin laxity treatment

- **TARGET:** WOMEN
- **PROTOCOL:**

1 tablet per day for 3 months

NEEDLE-BASED

4-7 injections of 4-8 mL (2-4 vials) at 15-30-day intervals, depending on the treatment performed and the extent of the area to be treated

NEEDLE-FREE

6-10 sessions using 4-8 mL (2-4 vials) at 10-day intervals, depending on the treatment performed and the extent of the area to be treated

Apply and massage daily on the treated areas

aesthetic GUNA

Hands: target & protocol

Skin hyperpigmentation treatment

- **TARGET:** WOMEN
- **PROTOCOL:**

3 tablets per day for 3 months

NEEDLE-BASED

4-7 injections of 2-6 mL (1-3 vials) at 15-30-day intervals, depending on the treatment performed and the extent of the area to be treated

NEEDLE-FREE

6-10 sessions using 2-6 mL (1-3 vials) at 10-day intervals, depending on the treatment performed and the extent of the area to be treated

Apply and massage daily on the treated areas

aesthetic GUNA

Abdomen: treatment

- **SKIN LAXITY →** 4-7 MD-TISSUE injection sessions, 6-10 mL per session. The first three sessions at 15-day intervals, followed by sessions at 30-day intervals.
  - ✔ Microinjection/wheal technique: insert the needle to a depth of 1-3 mm and perform microinjections of 0.02-0.05 mL, up to a total volume of 8 mL in the treated area.
  - ✔ Retrograde linear/fanning technique: insert the needle almost tangentially across the entire treatment area, then inject while simultaneously withdrawing the needle or cannula during product delivery.
- **LOCALIZED ADIPOSITY/CELLULITE →** 4-7 MD-MATRIX injection sessions, 6-12 mL per session. The first three sessions at 15-day intervals, followed by sessions at 30-day intervals.
  - ✔ Intradermal and subcutaneous administration: insert the needle to a depth of 3-10 mm, depending on the thickness of the adipose fold. Perform microinjections of 0.1-0.2 mL per point, with the needle positioned perpendicular to the skin surface and within the adipose tissue layer, spacing injection points approximately 1 cm apart, until an appropriate volume is delivered according to the treated area. The use of 30G needles of appropriate length is recommended depending on the treatment objective: 4 mm needles may be sufficient to improve the appearance of cellulite; whereas 12 mm or 19 mm needles are recommended for the treatment of localized adiposity.
- **POST-PARTUM SCARS →** 3-5 MD-TISSUE injection sessions, 6-12 mL per session, at 15-day intervals, followed by sessions at 30-day intervals, depending on scar extent and depth.
  - ✔ Microinjection/wheal technique: insert the needle to a depth of 2-6 mm within the scar tissue and perform microinjections of 0.1-0.2 mL, up to a maximum volume of 12 mL in the treated area. Needles: 27-32G × 2-13 mm.
  - ✔ Fanning technique: insert the needle almost tangentially across the entire treatment area, then inject while simultaneously withdrawing the needle or cannula during product delivery. Needles: 25-27G × 13 mm.
- **SCARS →** 3-5 MD-TISSUE injection sessions, 6-12 mL per session. The first three sessions at 15-day intervals, followed by sessions at 30-day intervals.
  - ✔ Step 1: using a 29G or 30G, 13 mm needle, insert tangentially into the scar to loosen the adhesion at its base (subcision or fibrotic debridement when feasible). Then inject 0.1 mL of product at this level using a retrograde linear technique.
  - ✔ Step 2: using a 30G, 4 mm needle, inject 0.05 mL of product into the superficial dermis (approximately 1-2 mm depth) to reach the most superficial portion of the scar. Cover the entire scar area with adjacent micro-wheals.
- **STRETCH MARKS →** 3-5 MD-TISSUE injection sessions, 8-10 mL per session, depending on extent and depth of the stretch marks. The first three sessions at 15-day intervals, followed by sessions at 30-day intervals.
  - ✔ Microinjection/wheal technique: insert the needle to a depth of 2-6 mm and perform microinjections of 0.1-0.2 mL, until the entire area is covered (RED STRETCH MARKS).
  - ✔ Fanning technique: using a 29G or 30G, 13 mm needle, insert tangentially into the stretch mark to loosen the adhesion at its base (when feasible). Then inject 0.1 mL of product using a retrograde linear technique (WHITE STRETCH MARKS).

Abdomen: target & protocol

Skin laxity treatment

- **TARGET:** MEN/WOMEN
- **PROTOCOL:**

1 tablet per day for 3 months

NEEDLE-BASED

4-7 injections of 6-10 mL (3-5 vials) at 15-30-day intervals, depending on the treatment performed and the extent of the area to be treated

NEEDLE-FREE

6-10 sessions using 6-10 mL (3-5 vials) at 10-day intervals, depending on the treatment performed and the extent of the area to be treated

Apply and massage daily on the treated areas

aesthetic GUNA

Abdomen: target & protocol

Localized adiposity/cellulite treatment

- **TARGET:** MEN/WOMEN
- **PROTOCOL:**

NEEDLE-BASED

4-7 injections of 6-12 mL (3-6 vials) at 15-30-day intervals, depending on the treatment performed and the extent of the area to be treated

NEEDLE-FREE

6-10 sessions using 6-12 mL (3-6 vials) at 10-day intervals, depending on the treatment performed and the extent of the area to be treated

Apply and massage daily on the treated areas

aesthetic GUNA

Abdomen: target & protocol

Scar treatment

- **TARGET:** MEN/WOMEN
- **PROTOCOL:**

1 tablet per day for 3 months

NEEDLE-BASED

3-5 injections of 6-12 mL (3-6 vials) at 15-30-day intervals, depending on the treatment performed and the extent of the area to be treated

NEEDLE-FREE

5-8 sessions using 6-12 mL (3-6 vials) at 10-day intervals, depending on the treatment performed and the extent of the area to be treated

Apply and massage daily on the treated areas

aesthetic GUNA

Abdomen: target & protocol

Stretch mark treatment

- **TARGET:** MEN/WOMEN
- **PROTOCOL:**

1 tablet per day for 3 months

NEEDLE-BASED

3-5 injections of 8-10 mL (4-5 vials) at 15-30-day intervals, depending on the treatment performed and the extent of the area to be treated

NEEDLE-FREE

5-8 sessions using 8-10 mL (4-5 vials) at 10-day intervals, depending on the treatment performed and the extent of the area to be treated

Apply and massage daily on the treated areas

aesthetic GUNA

Abdomen: study

Acumesotherapy in patients with localized abdominal adiposity

OBJECTIVE

To evaluate the effects of two combined techniques: acupuncture and MD-MATRIX mesotherapy, in patients with abdominal adiposity.

MATERIALS AND METHODS

- 23 women (27-53 years) with excess abdominal fat deposits
- 5 months of treatment, consisting of 10 weekly sessions of acupuncture + mesotherapy
- Subcutaneous injections were performed at a depth of 5-10 mm using 27G needles, injecting 0.2 mL of MD-MATRIX at the acupuncture points Ren12, Kd16, St25, Sp15, GB26, Ren6
- Umbilical circumference was measured at each session and at the end of therapy

MAIN RESULTS

All patients showed a reduction in abdominal circumference, ranging from 3 to 11.5 cm, with an overall mean reduction of 6.3 cm.

Circumference reduction (cm)	N. subjects	% patients
3.0 cm	2	8.7 %
4.5 cm	4	17.4 %
5.5 cm	3	13.0 %
6.5 cm	7	30.4 %
7.0 cm	4	17.4 %
8.5 cm	1	4.3 %
9.0 cm	1	4.3 %
11.5 cm	1	4.3 %

CONCLUSIONS

The combination of acupuncture and MD-MATRIX mesotherapy is effective and synergistic in reducing abdominal adiposity and in restoring the physiological balance of the treated tissue.

READ THE STUDY

Elenkova S., Pozharashka J. Acumesotherapy with guna MD-MATRIX in patients with localized abdominal adiposity. Physiological Regulating Medicine 2012.

aesthetic GUNA

Abdomen: study

Effectiveness of MD-TISSUE in pelvic pain caused by episiotomy and cesarean section scars: a pilot study

OBJECTIVE

To evaluate the effectiveness of MD-TISSUE collagen injections on pain and scar appearance in perineal lacerations, episiotomies, and cesarean section scars.

MATERIALS AND METHODS

- A randomized, controlled, single-blind pilot study involving 15 women
- The intervention group (n = 7) received 3-5 weekly MD-TISSUE injections (2 mL for episiotomies; 4 mL for cesarean scars);
- Baseline and 6-week follow-up assessments were performed using VAS, the McGill Pain Questionnaire, and the Vancouver Scar Scale/Patient Scar Assessment for scar appearance.

MAIN RESULTS

Patients treated with MD-TISSUE showed greater improvement in pain and scar appearance compared with the control group, which underwent conventional rehabilitation.

CONCLUSIONS

Collagen injections appear promising for the management of pelvic pain and scar appearance; however, further studies are needed to define cost-effectiveness and their role in the routine treatment of painful scars.

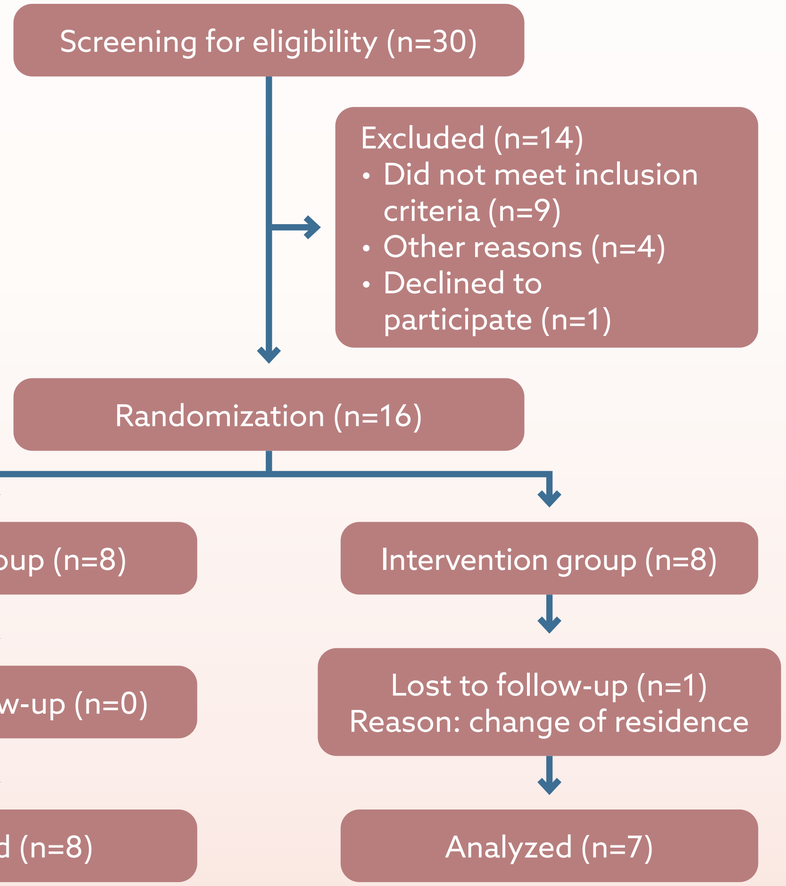

READ THE STUDY

Romero-Cullerés G., et al. Efficacy of collagen infiltrations in the pelvic pain caused by episiotomy and caesarean scars. Pilot randomized clinical trial. Rehabilitacion (Madr). 2021 Sep 3; S0048-7120(21)00059-1.

aesthetic GUNA

Gluteus/thigh: treatments

- **SKIN LAXITY →** 4-7 MD-TISSUE injection sessions, 6-10 mL per session. The first three sessions at 15-day intervals, followed by sessions at 30-day intervals.
  - ✔ Microinjection/wheal technique: insert the needle to a depth of 2-4 mm and perform microinjections of 0.02-0.05 mL, until the entire treatment area is covered.
  - ✔ Retrograde linear/fanning technique: insert the needle almost tangentially to the skin, then inject using a retrograde technique while simultaneously withdrawing the needle or cannula. Release approximately 0.05-0.1 mL per injection point.
- **LOCALIZED ADIPOSITY/CELLULITE →** 4-7 MD-MATRIX injection sessions, 6-12 mL per session. The first three sessions at 15-day intervals, followed by sessions at 30-day intervals
  - ✔ Intradermal and subcutaneous administration: insert the needle to a depth of 3-10 mm, depending on the thickness of the adipose fold. Perform microinjections of 0.1-0.3 mL per point, with the needle positioned perpendicular to the skin surface and within the adipose tissue layer, spacing injection points approximately 1 cm apart, until an appropriate volume is delivered according to the treated area. The use of 30G needles of appropriate length is recommended depending on the treatment objective: 4 mm needles may be sufficient to improve the appearance of cellulite; whereas 12 mm or 19 mm needles are recommended for the treatment of localized adiposity.
- **STRETCH MARKS →** 3-5 MD-TISSUE injection sessions, 8-10 mL per session, depending on extent and depth of the stretch marks. The first three sessions at 15-day intervals, followed by sessions at 30-day intervals.
  - ✔ Microinjection/wheal technique: insert the needle to a depth of 2-6 mm and perform microinjections of 0.1-0.2 mL, until the entire area is covered (RED STRETCH MARKS).
  - ✔ Fanning technique: using a 29G or 30G, 13 mm needle, insert tangentially into the stretch mark to loosen the adhesion at its base (when feasible). Then inject 0.1 mL of product using a retrograde linear technique (WHITE STRETCH MARKS).

Gluteus/thigh: target & protocol

Skin laxity treatment

- **TARGET:** MEN/WOMEN
- **PROTOCOL:**

1 tablet per day for 3 months

NEEDLE-BASED

4-7 injections of 6-10 mL (3-5 vials) at 15-30-day intervals, depending on the treatment performed and the extent of the area to be treated

NEEDLE-FREE

6-10 sessions using 6-10 mL (3-5 vials) at 10-day intervals, depending on the treatment performed and the extent of the area to be treated

Apply and massage daily on the treated areas

aesthetic GUNA

Gluteus/thigh: target & protocol

Localized adiposity/cellulite treatment

- **TARGET:** MEN/WOMEN
- **PROTOCOL:**

NEEDLE-BASED

4-7 injections of 6-12 mL (3-6 vials) at 15-30-day intervals, depending on the treatment performed and the extent of the area to be treated

NEEDLE-FREE

6-10 sessions using 6-12 mL (3-6 vials) at 10-day intervals, depending on the treatment performed and the extent of the area to be treated

Apply and massage daily on the treated areas

aesthetic GUNA

Gluteus/thigh: target & protocol

Stretch mark treatment

- **TARGET:** MEN/WOMEN
- **PROTOCOL:**

1 tablet per day for 3 months

NEEDLE-BASED

3-5 injections of 8-10 mL (4-5 vials) at 15-30-day intervals, depending on the treatment performed and the extent of the area to be treated

NEEDLE-FREE

5-8 sessions using 8-10 mL (4-5 vials) at 10-day intervals, depending on the treatment performed and the extent of the area to be treated

Apply and massage daily on the treated areas

aesthetic GUNA

Gluteus/thigh: study

Injectable collagen acumesotherapy in patients with localized knee adiposity

OBJECTIVE

To evaluate the combined effectiveness of acupuncture and infiltrative collagen mesotherapy in the treatment of localized adiposity of the knees.

MATERIALS AND METHODS

- 22 women (25-51 years) underwent 10 weekly sessions of acumesotherapy.
- Subcutaneous injections of 0.3 mL of MD-MATRIX were performed using 27G needles at a depth of 5-10 mm.
- Circumference at the popliteal fold was measured before treatment, at the beginning of each subsequent session, and at the end of therapy.

MAIN RESULTS

- All patients showed a mean circumference reduction of 3.3 cm (from 42.68 cm to 39.36 cm).
- A reduction in pain was observed in patients with Hoffa's disease, along with an increase in self-esteem.

CONCLUSIONS

The combination of acupuncture and mesotherapy provides synergistic results, achieving correction of localized fat deposits and restoration of physiological balance in the treated tissue. Additional benefits include pain reduction in patients with Hoffa's disease and improved self-esteem.

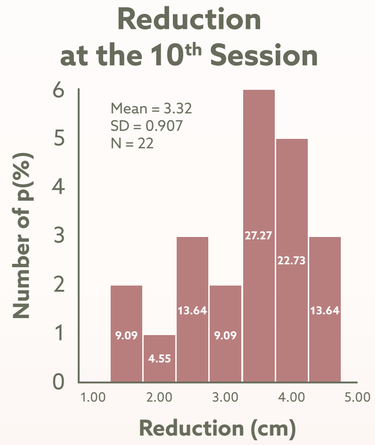

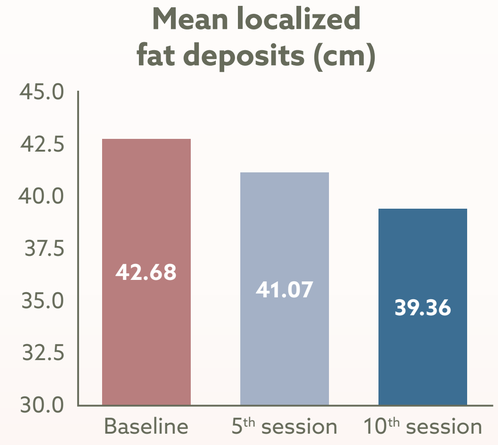

PRE-TREATMENT

POST-TREATMENT

READ THE STUDY

Elenkova S., Pozharashka J. Acumesotherapy with injectable collagen in patients with localized adiposity of the knees. ECIM 2012, Firenze.

aesthetic guna

Gluteus/thigh: study

Lassità skin laxity of the brachial region, knees, and abdomen

OBJECTIVE

To evaluate the effectiveness of injectable collagen as a biostimulatory and regenerative therapy to improve tissue quality, considering the natural decline of collagen starting from 30-35 years of age.

MATERIALS AND METHODS

- 10 patients underwent a cycle of 5 weekly injections (total volume: 6 mL; 4 mL MD-MATRIX + 2 mL MD-TISSUE).
- Assessment was performed using a skin tonicity scale and comparative pre- and post-treatment photographic analysis.

MAIN RESULTS

Treatment provided satisfactory outcomes in terms of tonicity recovery, improvement of skin histological structure, and a volumizing effect with increased dermal firmness.

CONCLUSIONS

Injectable collagen treatment proved to be well tolerated and cost-effective compared with other therapies. A clinically significant improvement in tissue repair and regeneration was observed and perceived by both patients and physicians.

PRE-TREATMENT

POST-TREATMENT

READ THE STUDY

Zazzaron M. Trattamento rigenerativo con collagene suino iniettivo per il rilassamento cutaneo. Conference poster AGORÀ 2025.

aesthetic GUNA

Beauthentic

The new language of the skin

PLAY SURE
doping free

Visit Beauthentic Website

aesthetic GUNA

TRATTAMENTO NON INVASIVO DELLA ZONA PERIOCULARE CON COLLAGENE SUINO: DALLE RUGHE AL "SORRISO NELLO SGUARDO"

D.ssa Sonia Ciampa, *Medico Estetico Poliambulatorio Rimedical Rimini*

OBIETTIVI:

La regione perioculare è una zona del viso soggetta a invecchiamento, perdità di elasticità, microrugosità e alterazioni cromatiche.
Il trattamento della regione perioculare (come dark circles, borse edematose, discromie da deposito di melanina) è un aspetto chiave dell'estetica del volto, frequentemente soggetta a inestetismi sia in età giovanile, sia in età adulta.
L'obiettivo di questo lavoro è valutare l'efficacia del trattamento non invasivo della zona perioculare, soggetta a precoce invecchiamento, dove compaiono lassità, rugosità e perdita di tono.
L'approccio non invasivo con collagene suino può rappresentare una nuova soluzione efficace per la biostimolazione dermica, migliorando tono, idratazione e luminosità cutanea.

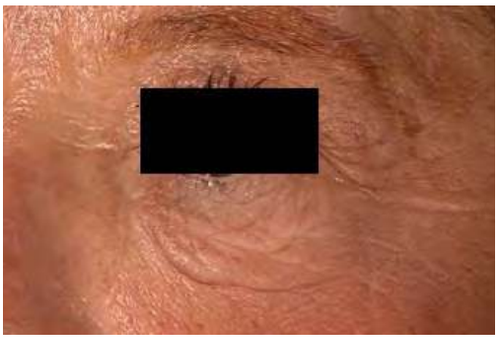

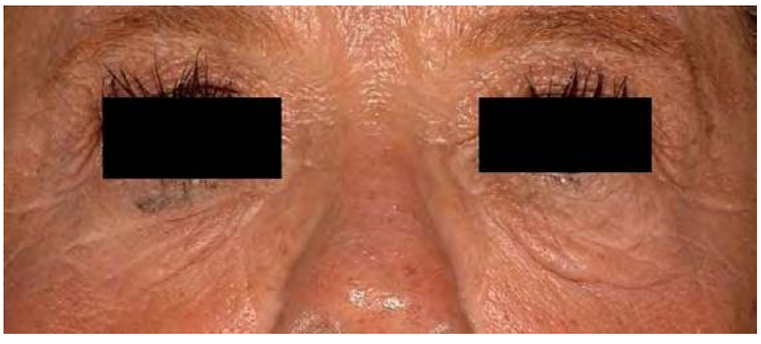

MATERIALI E METODI:

È stata utilizzata una metodica non invasiva mediante magnetoforesi di risonanza per il trattamento della zona periorbitale andando a veicolare transdermicamente il dispositivo medico di classe III a base di collagene suino, acido citrico e nicotinamide.
La magnetoterapia di risonanza è una metodica che permette la somministrazione dei principi attivi per via transcutanea in modo indolore attraverso l'utilizzo di campi magnetici a bassa intensità. Attraverso la magnetoterapia le informazioni chimico-elettriche dei dispositivi medici vengono veicolate ai tessuti trattati in maniera specifica e selettiva.
I 10 pazienti inseriti nello studio hanno inoltre assunto dermacollagene neorland ricco in esosomi, equiseto, vitamina C, E, B2 e niacina per os e applicato localmente un siero a base dello stesso collagene, vitamina C, vitamina E e acqua di fiori di Rosa Centifolia.
I pazienti sono stati trattati a cadenza settimanale per 5 sedute.
Dopo adeguata detersione cutanea il medical device oggetto dello studio (utilizzabile sia per via iniettabile che per via transdermica) è stato miscelato con un gel specifico ed applicato con spatola sulla cute del contorno occhi per veicolazione transdermica tramite magnetoforesi di risonanza.

RISULTATI:

Al termine del ciclo di trattamento è stata osservata una cute più tonica nella zona trattata, una rugosità statica ridotta e una significativa riduzione dei dark circles.
L'assenza totale di effetti collaterali ha reso il trattamento ben tollerato e facilmente eseguibile anche in periodo estivo.

CONCLUSIONI:

La veicolazione trandermica del dispositivo medico a base di collagene suino, acido citrico e nicotinamide mediante magnetoforesi si è dimostrata efficace nel migliorare la qualità cutanea della zona periorbitale, offrendo una soluzione sicura, efficace e ben tollerata dai pazienti.

BIBLIOGRAFIA:

1. Randelli F, Menon A, Giai Via A, et al, Effect of a Collagen-Based Compound on Morpho-Functional Properties of Cultured Human Tenocytes. Cells. 2018 Dec 6;7(12):246.

2. Randelli F, Sartori P, Carlomagno C, Bedoni M, Menon A, Vezzoli E, et al. The Collagen-Based Medical Device MD-Tissue Acts as a Mechanical Scaffold Influencing Morpho-Functional Properties of Cultured Human Tenocytes. Cells. 2020 Dec 8;9(12):2641.

S. Elenkova, J. Pozharashka

ACUMESOTHERAPY WITH GUNA MD-MATRIX IN PATIENTS WITH LOCALIZED ABDOMINAL ADIPOSITY

INTRODUCTION

The Localized Adiposity is not only an aesthetic problem, but a complex pathology – an external expression of numerous metabolic alterations in the tissue / connective matrix, adipose tissue / and the organic/endocrine, circulatory, nervous, immune/ systems.

MD-Matrix – ampoule 2 ml (Guna Spa, Milan, Italy), containing collagen and as excipients: citric acid + nicotinamide, is designed according to the conception of Physiological Regulative Medicine (PRM) in order to correct physiological imbalances in the tissue.

PURPOSE OF THE STUDY

To examine and evaluate the effects of simultaneous application of two established techniques – Acupuncture and Mesotherapy with MD-Matrix in patients with Localized Abdominal Adiposity.

PATIENTS AND METHOD

Inclusion criteria

Our investigation covered 23 healthy women aged between 27-53 with excess abdominal fat deposits.

No special diet was given to the patients.

It was only recommended to take once a week 1500 g. of fruits divided into 4 equal portions during the day.

From February 2011 to July 2011, ten sessions of Acupuncture + Mesotherapy were carried out once a week.

Subcutaneous injections at 5-10 mm depth, using needles 27G and injecting 0.2 ml MD-Matrix in the following acu-points: **Ren12, Kd16, St25, Sp15, GB26, Ren6**.

Measurements of the circumference on the level of the umbilicus was taken before starting the treatment, at the beginning of every next session and at the end of the therapy.

RESULTS

All patients have obtained an objective reduction of the localized abdominal fat deposits.

- 2 subjects (8.7%) reduction of umbilical circumference 3.0 cm.
- 4 subjects (17.4%) reduction of circumference 4.5 cm.
- 3 subjects (13.0%) reduction of circumference 5.5 cm.
- 7 subjects (30.4%) reduction of circumference 6.5 cm.
- 4 subjects (17.4%) reduction of circumference 7.0 cm.
- 1 subject (4.3%) reduction of circumference 8.5 cm.
- 1 subject (4.3%) reduction of circumference 9.0 cm.
- 1 subject (4.3%) reduction of circumference 11.5 cm.

CONCLUSIONS

The clinical evaluation provides important positive data regarding the effectiveness of Acupuncture + Mesotherapy with MD-Matrix in women with Localized Abdominal Adiposity.

A significant decrease of the umbilical circumference has been noted with an **average of 6.3 cm**.

– It can be concluded that this combination ensures synergistic results – correction of localized excess of fat deposits and restore of the physiological balance in the treated tissue. Additional benefits are the improved self-confidence and physiological comfort. ■

Abstract presented at the
5th International Medical Acupuncture Congress
5th-6th November 2011, Barcelona - Spain

First author

Dr. S. Elenkova, MD
– Center of Integrative Medicine
Sofia, Bulgaria

ACUMESOTHERAPY WITH INJECTABLE COLLAGEN IN PATIENTS WITH LOCALIZED ADIPOSITY OF THE KNEES

Elenkova Silvia, MD, Center of Integrative Medicine, Sofia, Bulgaria, e-mail: dr.elenkova@abv.bg
Pozharashka Joana, Center of Integrative Medicine, Sofia, Bulgaria, e-mail: pojarashka@gmail.com

KEY WORDS
- Localized adiposity
- Mesotherapy
- Local knee acupuncture points
- Injectable collagen MD Matrix

THE PROBLEM: The Localized Adiposity is not only an aesthetic problem, but a complex pathology – an external expression of numerous metabolic alterations in the tissues /connective matrix, adipose tissue/ and the organic /endocrine, circulatory, nervous, immune / systems.

- Is the accumulation of brown fat, rebellious to the physical activity in certain areas of the body that cause alterations in body contour.
- It is usually located in the abdomen ("lifeguard or rolls") to the sides of the legs (" riding pants"), shoulder and back of the arms, back ("hump"), inside of knees, etc.

FOUR FACILITATING ADIPOSITY FACTORS
- Alcoholic beverages: every gram of alcohol has 7 kilocalories.
- Smoking: Smokers have more fat in the abdomen than non-smokers.
- Sugar and fat: the combination tends to increase the volume of the abdominal area.
- Swimming in cold water increases the appetite and body fat accumulation as a mechanism for heat conservation. swimming is a very complete sport, but in very cold water can have "side effects".

THE HYPODERMIS is made up of adipocytes grouped in lobules approximately 1cm in diameter; they are separated by walls of connective tissue through which blood and lymph vessels run. From these walls others emerge surrounding the lobes with abundant micro capillaries resulting in a very vulnerable terminal structure.

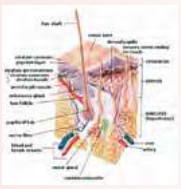

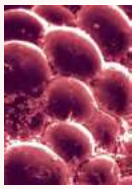

ADIPOCYTES/ELECTRONIC MICROSCOPY/

PATHOGENESIS OF LOCAL ADIPOSITY
There is not single opinion. The most popular pathogenetic models mentioned are:
- **Poor oxygenation** of tissues and accumulation of waste material and liquid in the connective tissue.
- **Disorders of lymph drainage** – adipocytes and the accumulated liquids push and spoil the connective tissue, break collagen fibers and block blood and lymphatic flow.
- **Hormonal influences** – fat distribution is regulated by **17 – beta estradiol**. Regarding the hormonal changes there is a greater predisposition for development of fat cells in women. In adolescence there is increased activity of the estrogen-dependent **lipoproteolipase**, which is who contributes triglycerides to the fat cells. The **lypogenic hormones** are mainly **insulin and estrogen**.

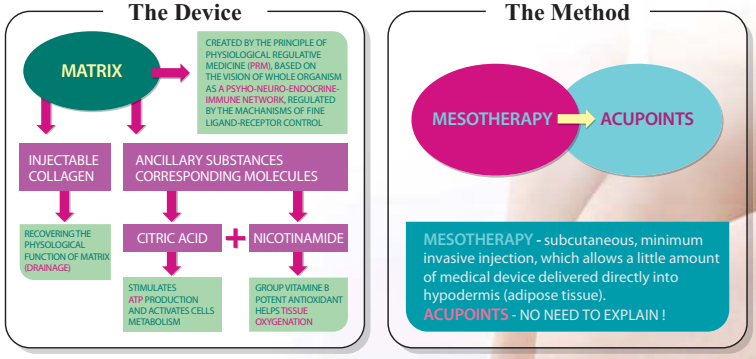

PURPOUSE: **To examine and evaluate the effects of simultaneous application of two established techniques – Acupuncture and Mesotherapy with Injectable Collagen in the treatment of adipose accumulations, located on the knees.**

DESIGN OF THE STUDY: **Our investigation covered 22 women with excess fat deposits on the knees, aged 25-51 years, answering the inclusion criteria. They were under our observation from October 2011 to March 2012. During this period ten sessions of Acu- mesotherapy were carried out once a week. Measurement of the circumference on the level of popliteal crease was taken before starting the treatment, in the beginning of every next session and at the end of the course.**

We were making subcutaneous injection at 5-10 mm depth, using needles 27G and injecting 0,3 ml Collagen /MD-Matrix/ in the following acu-points:

St-34, St-36, Sp-9, Sp-10, Liv-8,Bl-40 and 0,2 ml in St- 35

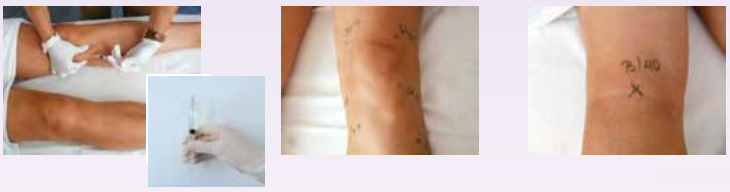

RESULTS: **All patients obtained objective reduction of the localized knee fat deposits.**

The decrease in knee circumference is statistically significant: F(2, 42) = 208,708, p<0.001, analyzed with Repeated measures analysis.

Repeated measures analysis:
Before treatment: mean 42.68sm,
After 5th session: mean 41.07sm,
After 10th session: mean 39.36sm

Histogram of the reduction after 10th session:

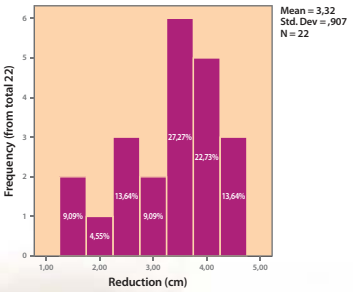

Reduction after 5th and 10th session:

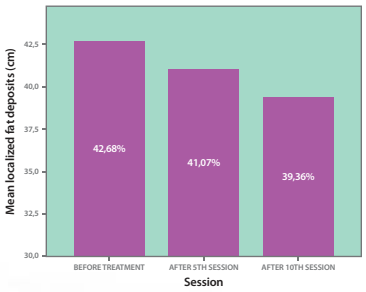

THE RESULTS BEFORE/AFTER THE TREATMENT

CONCLUSIONS: **This clinical evaluation provides positive data regarding the effectiveness of Acumesotherapy with Injectable Collagen in women with Localized Knee Adiposity. The significant decrease of knee circumference at an average 3,3 cm allows us to conclude, that this combination ensures synergistic results - correction of localized excess fat deposits and restore of the physiological balance in treated tissue.**
Additional benefits are reduction of the pain in patients with Hoffa's disease and improved self-esteem .

E. Falconi Klein

FACE REVITALIZATION - BIOLIFTING WITH MD-TISSUE

SUMMARY

In our society there is a major interest in the treatment of ageing skin with revitalizers that stimulate new collagen production and that can enhance face luminosity and freshness without damaging the health of the patients treated.
The aim of this study is to demonstrate the efficacy of the medical device MD-Tissue as a face revitalizer. Fifteen female volunteers have been treated with weekly injections for six consecutive weeks; the evaluation has concerned only the nasolabial folds.

– A photographic documentation with Visioface® Quick has been carried out and the volume of the wrinkle has been calculated; during the treatment period of the elasticity has also been measured. The Collagen Medical Device MD-Tissue has been perfectly tolerated by all volunteers.
It has proven an average capacity in the improvement of the skin elasticity and a good capacity in the reduction of the wrinkle volume.

KEY WORDS

SKIN AGING - FACE REVITALIZATION - COLLAGEN MEDICAL DEVICE MD-TISSUE, VISIOFACE® QUICK, ELASTICITY, WRINKLE VOLUME

SKIN AGING

The aging of the skin – especially the one of the face – is a growing concern for most people, regardless of their age.

Patients can be very young, looking for tips to prevent wrinkles, or they can be middle-aged, desiring to look younger or at least keep their appearance unchanged. On other occasions patients start treatments when they are elderly, and have finally decided to do something for themselves.

– Skin aging depends on several factors: biological senescence and genetic heritage (chrono-aging), photo-aging due to UV rays, and finally on lifestyle (diet, alcohol, smoking, pollution and oxidative stress).
The appearance of the aged skin varies depending on the prevalence of chrono- or of photo-aging (1, 2, 3): the senile skin is pale and dry, thin, floppy, hypo-elastic and finely wrinkled, whereas the photo-aged skin is rough, patched and crossed by deep wrinkles, the skin is anelastic and the horny layer is thickened; the smokers' skin is also sallow and dull.

WRINKLES AND THEIR PATHOPHYSIOLOGY

The causes that lead to the formation of the wrinkles are – in addition to chronological aging as a whole – the degradation of the elastic fibers and the alteration of the collagen ones (caused by the sun), muscle and joint movements, and the force of gravity.

The formation of wrinkles is affected by these factors to different extents and – consequently – also in the classification of the aging degree.
The classification of the signs of aging conducted by Kligman (1) can help to identify the various stages of the aging process: linear wrinkles, glyphic wrinkles, creases, lines of articulation, nasolabial folds (4).
Linear wrinkles result from linear contraction of the mimic muscles of the face, when they lose tone and elasticity. At first they are temporary folds and furrows, then they mark the face increasingly, following the muscle movement.

For instance, the "crow's feet", around the eyes; the "wrinkles of wonder", parallel to the front; the "thinker's wrinkles", vertical at the center of the eyebrows, the "smoker's wrinkles" that surround the mouth.
All gradually become more marked in relation to the photo-induced damage.
Glyphic wrinkles – which other authors define as skin texture – are lines that form square or rhomboid areas on the skin surface; with aging they become more evident, they are particularly noticeable on the cheeks of the elderly with photo-damaged skin.
Creases – better known as "the folds of

sleep" – develop late, caused by the head resting on the pillow while sleeping.
Their vertical course crosses the vertical mimetic muscle lines, especially on the forehead and cheeks.
The lines of articulation are those found in places where there is a hinge movement (ankles, elbows, wrists, etc.); existing since the birth, they become more marked and increase in other zones too (neck, trunk, etc.) with senility.
They are not very much considered from the point of view of cosmetology and dermatology, nevertheless.

Finally, the nasolabial folds, which have been taken into consideration in this article, and the folds of muscle-skin laxity that appear when the collagen and elastic texture is no longer able to counteract the force of gravity and present themselves as a falling of the skin due to the force of gravity.

The loosening skin is the outward visible result of the degradation of the connective tissue in which collagen, elastin, fibronectin and proteoglycans have lost their cohesion, their strength and ability to respond to elastic stimuli.
This phenomenon is connected to aging or to prolonged sun exposure, or even to weight loss following a state of obesity (4).
Revitalizers are very suitable for patients who want a natural treatment which does not change the facial expression.
The possibility of using a revitalizing such as **MD-Tissue** could offer many advantages. It is a product that has been planned for soft tissues, able to create a defense barrier against free radicals and to counteract the physiological aging of connective tissue (5).
These are all properties required for the use of a good tissue revitalizer.

Homeopathized collagen has been used since the 90s (Kollagen D6, D8) and after the first encouraging results, more revitalizing substances have been added.

Thus, the product **MADE** was born; it contains Collagen D8/D30, Hyaluronidase D8/D30 and Magnesium D6 (6).
Collagen D8/D30 works by stimulating the production of endogenous collagen, because – according to the law of the Arndt-Schultz reverse effect – weak stimuli (diluted doses) excite the biological activity.
The Hyaluronidase D8/D30, acting with the mechanism of the inverse effect, encourages greater compactness of the basic substance reducing wrinkles and toning the skin.
Magnesium D6 stimulates the production of exogenous collagen too.
– MADE also contains enzymatic catalysts, which act on the cellular respiration, drainers and organotherapy medicines with toning and revitalizing effects (6).

THE TUNNELING TECHNIQUE

Tunneling represents an infiltrative technique which consists in introducing the needle (in this study it was used the 27G needle) for its entire length almost tangentially to the skin surface, so to take wrinkles or nasolabial folds for their entire length.
Once introduced the needle, one starts to inject the substance and simultaneously pulls the syringe in a retrograde sense until the needle comes out.

– The purpose of this paper is to demonstrate the effectiveness of the medical device MD-Tissue, measuring objective parameters before, during and after the treatment of fifteen volunteers aged between 33 and 50 years.

In addition to the photographic documentation of the wrinkles with the photographic method Visioface® Quick, measurements of skin elasticity are performed with the elastomer.
All the equipment above described was kindly made available by BIOBASIC Europe Srl, Milan (Italy).

MATERIAL AND METHODS

– MD-Tissue

Fields of application known so far:
MD-Tissue is intended to improve the movement, helping to contain the physiological deterioration of joints and tissue and counterbalance the effects of a variety of causes including:
- Aging
- Postural defects
- Concomitant chronic diseases
- Trauma and injuries
- Polluting agents.

MD-Tissue is a medical device useful for facilitating mobility, counteracting the physiological aging of connective tissue, whose primary therapeutic treatment consists in the following functions:
1. Barrier
2. Lubricant
3. Mechanical support in the case pharmacological therapy.

– We recommend the use of MD-Tissue to be undertaken by qualified health professionals.

– Treatment protocol

Two treatments for the first 2 weeks, 1 treatment until improvement of symptoms (8-10 sessions on average).
If necessary, continue with one treatment every other week for a maximum of 10 sessions. Chronic pathologies: continue with 1 treatment a week for 1 month until improvement of symptoms, and subsequently 1 treatment a month.
- via intradermal injection: the area of application must be sterile; introduce the needle to a depth of 1-3 mm.
- via periarticular injection: the area of application must be sterile; introduce the needle in the proximity of the joint to a depth of 2-4 mm.

– Method of administration

For this use of the medical device, it is recommended to use the following materials and accessories:
- Material to ensure skin asepsis: dispo-

sable gloves, iodine based solution, alcoholic solution, sterile gauzes, ethyl chloride spray.
- Sterile needles (27G)
- Syringes (5 or 10 cc), depending on the amount of solution to be injected.

– Contraindications / Side Effects

No case of hypersensitivity to MD-Tissue has been reported.
Patients with known hypersensitivity to the component or the excipients must be previously undergo injecting test in the arm and kept under observation for one hour.

– Protocol applied for revitalization with MD-Tissue

Before proceeding with the treatment all the volunteers signed an informed consent. Then an allergological test with intracutaneous injection of a small amount of MD-Tissue was performed on all the volunteers in order to exclude a possible sensitization.

None of the 15 volunteers had any adverse reaction to MD-Tissue.

– After a phase of clinical observation lasting 30 minutes – which is generally sufficient to exclude immediate type I allergic reactions – basal measurements have been taken (time 0, T0) by performing a measurement of the skin elasticity of the **nasogenian fold** and a photograph of the face performed with the Visioscan® was also taken.
It was decided to apply a pattern that is frequently chosen in various protocols for anti-aging revitalization of the face. The injective treatment with MD-Tissue was performed once a week for 6 consecutive weeks.
At each session it was injected intradermally a 2ml vial of MD-Tissue in the nasogenian folds, following linearly the nasogenian fold with the tunneling technique.
Some volunteers have called for the application of an anesthetic cream prior to receiving this treatment.
The needle used was 27G.

After the 3rd session and prior to the 4th session, intermediate measurements (time 3 weeks, T3) were taken with photo-documentation and measurement of the elasticity, so to be able to better assess the progress of the treatment.
At the end of the treatment (after the 6th session) – 7 days after the last treatment – the latest measurements were carried out, always with photo-documentation and measurement of the elasticity.

– Self-evaluation form

At the end of the treatment, the volunteers filled out a self-evaluation form. The votes are comprised between 0 and 10, where 0 is equivalent to "not at all" and 10 to "very much." The evaluation is expressed spontaneously, in writing and kept reserved by the patient to avoid any influence from the doctor.

The questions that have been chosen for this experiment are the following:

1. To what extent do you think that the product reduces the visibility of the expression lines?
2. To what extent do you think that the product reduces the visibility of micro wrinkles?
3. To what extent do you think that your wrinkles are less deep?
4. To what extent do you think that the product increases skin elasticity?
5. To what extent do you think that the product increases your skin brightness?
6. To what extent do you think that your skin looks fresher / revitalized?
7. To what extent do you think that that the product increases your skin firmness?
8. To what extent do you think that the product increases your skin smoothness?
9. To what extent do you think that the product improves your skin texture?

Long term skin elasticity

Volunteer n.	t0	t 3 weeks	t 6 weeks
1	0,8123	0,8129	0,7092
2	0,6720	0,6786	0,7213
3	0,8785	0,8591	0,8088
4	0,6879	0,7143	0,7398
5	0,6906	0,7990	0,6931
6	0,7642	0,8412	0,8526
7	0,7500	0,8452	0,8400
8	0,7654	0,8168	0,8000
9	0,8265	0,8022	0,8387
10	0,8406	0,8300	0,8377
11	0,7721	0,8128	0,6633
12	0,7893	0,8084	0,8280
13	0,8150	0,7738	0,6606
14	0,7686	0,8254	0,6812
15	0,8030	0,8138	0,8067
Average	0,776	0,802	0,765
Dev. STD	0,0584572575	0,0480712665	0,0716924682
	Δ%	3,4	-1,3

TAB. 1
Long term skin elasticity.

10. To what extent do you think that your skin looks healthier?
11. To what extent do you think that the product gives your skin a "comfortable" feeling?

In the interpretation of the results it was decided to unify some votes to avoid data loss.
– The votes 9 and 10 are considered "very good"; 7 and 8 "good"; 6 "fair"; 3, 4 and 5 "poor".

– Skin elasticity

Skin elasticity is defined as the ability of the skin to stretch without breaking down, then returning to its original shape.
It has been measured with the elastomer (Cutometer® MPA 580, Courage-Khazaka Electronic GmbH, Koeln, Germany).
Applied to the skin, this device performs a suction of a part of the skin and the height reached by the aspirated layer refers to its degree of tensile distensibility; repeating several times the same maneuver, a further increase of skin distensibility can be observed – defined as tensile stretching, which is evaluated and recorded by the device.
The latest and most refined dermatological-physiological research could find that distensibility reflects the state of health of the collagen fibers of the dermis and that the recovery distensibility briefs about the conditions of the elastic fibers (4).

– Photographic documentation

The photographic documentation was performed with the computer system Visioface® Quick (full face photo analysis), CK electronic GmbH Koeln (Germany).

RESULTS

– Results of the measurement of skin elasticity

The results of the measurements of skin elasticity carried out on 15 volunteers at T0 (before treatment with revitalizing MD-Tissue) at T3 (1 week after the 3rd treatment, i.e before the 4th) and at T6 (1 week after the 6th and final treatment) are presented.
– The measurement was always performed on the nasogenian folds.
TAB. 1 lists all the numerical results of the 15 volunteers with their values at T0, T3 and T6.
– Overall, there was a slight increase in skin elasticity after 3 weeks of treatment, and after 6 weeks, the values return almost to baseline. The average of the values which initially was 0.776 increases on average to 0.802 after 3 weeks and then lowers again to 0.765.
After 3 weeks of treatment, 11 out of 15 volunteers (73.33%) show greater elasticity compared to the beginning.
Only 4 volunteers (number 3, 9, 10, 13) (26.33%) show a lowering of elasticity after the first three treatments.
After 6 weeks of treatment 9 voluntary out of 15 (60%) have greater elasticity than at the beginning, while 6 volunteers (number 1, 3, 10, 11, 13, 14) (40%) have a lowering of the elasticity under values of T0.
TAB. 2 represents graphically the results recorded by the volunteers (1-15).

– Results of photographic documentation Visioface® Quick

The volume and depth of wrinkles were studied with Visioface® Quick and the data processing was performed with the program Skin Surface Analyzer SSA.
From the front picture of the complete face it is chosen a small area located on the right or left nasogenian fold of each patient, this selected rectangular area corresponds to the "surface" of the wrinkle.
The "depth" of the wrinkle is measured in AU (Adimensional Unit).
It is a measurement scale created on a colorimetric basis to give depth to the selected area.

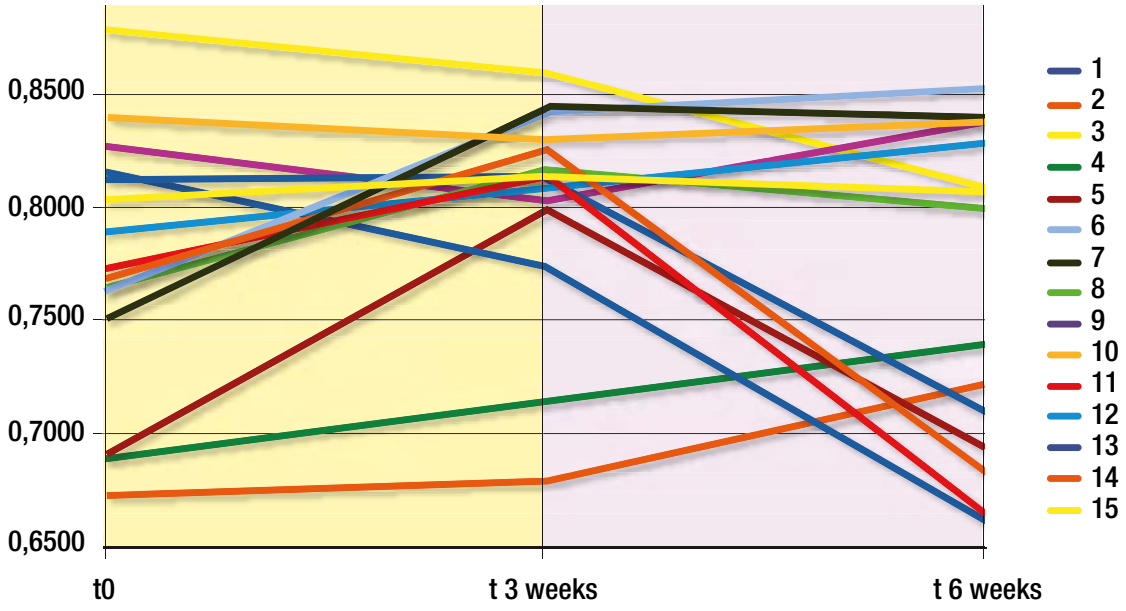

TAB. 2
Skin elasticity, graphical representation for each patient.

Volunteer n.	Wrinkle volume mm² X A.U. t0	t 3 weeks	t 6 weeks	%
1	0,4500	0,4500	0,3200	-28,9
2	0,2400	0,2000	0,2200	-8,3
3	0,1000	0,0900	0,0900	-10,0
4	0,1300	0,1600	0,1000	-23,1
5	0,8100	0,8500	0,7200	-11,1
6	0,2800	0,2300	0,2400	-14,3
7	0,2300	0,2300	0,1900	-17,4
8	0,2100	0,2500	0,2000	-4,8
9	0,1700	0,1900	0,1700	0,0
10	0,0800	0,0900	0,0800	0,0
11	0,3800	0,3600	0,3200	-15,8
12	0,1100	0,1000	0,1000	-9,1
13	0,5300	0,4000	0,4800	-9,4
14	0,2200	0,2400	0,2000	-9,1
15	0,1600	0,1500	0,1200	-25,0
Average	0,273	0,266	0,237	
Dev. STD	0,19722	0,19449	0,17182	
	Δ%	-2,7	-13,4	

TAB. 3
Wrinkle volume mm² 2 X A.U. with decrease percentage of each patient after 6-week treatment.

The "volume" of the wrinkle is the result of the following calculation:
Volume of the wrinkle (mm (2)) = AU x height (mm) x width (mm) x depth.

The volume of wrinkles was reduced by a total of 2.7% after 3 weeks and 13.4% after 6 weeks of treatment.
The values ranged from 0% to 28.9%.

– Results of self-assessment

Here below are shown the 11 questions along with the opinions expressed in votes and in percentage to which the 15 patients of the trial replied:

1. To what extent do you think that the product reduces the visibility of the expression lines?
   – The ability to reduce the visibility of the expression lines is considered by 80% of patients "good", by 6.67% "fair" and by 13.33% "poor".
2. To what extent do you think that the product reduces the visibility of micro wrinkles?
   – The ability to reduce the visibility of micro wrinkles is considered by 13.33% of patients "very good", by 53.33% "good", by 20% "fair" and by 13.33% "poor".
3. To what extent do you think that your wrinkles are less deep?
   – The perception of less deep wrinkles is for 6.67% of patients "very good", for 80% "good" and for 13.33% "poor".
4. To what extent do you think that the product increases the skin elasticity?
   – The increase in the skin elasticity is perceived by 86.67% of patients to be "good" and by 13.33% "fair".
5. To what extent do you feel that the product increases the brightness of your skin?
   – The increase in brightness is held "very good" by 13.33% of the patients, "good" by 66.67%, "fair" by 6.67% "fair" and "poor" by 13.33%.
6. To what extent do you think that your skin looks fresher / revitalized?
   – The perception of a fresh and revitalized skin is for 13.33% of patients "very good", for 66.67% "good" and for 20% "fair".
7. To what extent do you think that the product increases your skin firmness?
   – The increase in firmness is considered by 6.67% of patients "very good", by 73.33% "good" and by 20% "fair".
8. To what extent do you think that the product increases your skin smoothness?
   – The increase in smoothness is perceived by 6.67% of patients as "very good", by 60% "good" and by 33.33% "fair".
9. To what extent do you think that the product improves your skin texture?
   – The improvement in the skin texture is considered by 6.67% of patients "very good", by 46.67% "good" and by 46.67% "fair".
10. To what extent do you think that your skin looks healthier?
    – The perception of a healthier skin is for 6.67% of patients "very good", for 80% "good" and for 13.33% "fair".
11. To what extent do you think that the product gives your skin a

"comfortable" feeling?
– The perception of a sense of "comfort" is for 6.67% of patients "very good", for 73.33% "good", for 13.33% "fair" and for 6.67% "poor".

DISCUSSION

The aim of this study was to demonstrate the effectiveness of the medical device MD-Tissue as facial revitalizer.
15 patients – 33-50 years – were evaluated; first they underwent an allergy test with the provocation of a small intracutaneous wheal to exclude sensitization to the product.
MD-Tissue showed an acceptability of 100%, none of the patients experienced discomfort or side effects.
Consequently, they were administered weekly injections of MD-Tissue (2.0 ml), exclusively in the nasogenian folds. At the beginning of the treatment (T0), after 3 weeks (T3) and after 6 weeks (T6) a photographic documentation was performed using Visioface® Quick and the measurement of elasticity using the elastomer (Cutometer Courage - Khazaka).
At the end of the treatment the patients completed a self-evaluation questionnaire.

After 3 weeks of treatment the elasticity values showed an improvement of 73.33% and have achieved a total improvement of 3.4%; after 6 weeks of treatment they stabilized at 60%.

In order to achieve more indicative values, further measurements and – above all – a higher number of patients may be required.

However, the effect is present and elasticity in this work was higher after 3 weeks than after 6 weeks of treatment.

As for the photographic documentation obtained through the device Visioface® Quick and the data calculation achieved with the Skin Surface Analyzer SSA, results were highly positive.
The overall improvement of the patients, with a lowering of the wrinkle volume calculated by the Skin Surface Analyzer, was of -2.7% after 3 weeks and -13.4% after 6 weeks with peak improvements in the depth of wrinkles even reaching 28.9%.
– This very satisfactory result is also reflected in the data interpretation found in the patients' self-assessment questionnaire and in their happiness:

80% considered "**good**" the reduction of the visibility of the expression lines; they considered that the wrinkles on the face are less deep, and their skin healthier.
86, 67% considered "**good**" the increase in elasticity; **73.33%** judged as "**good**"; **6.67%** as "**very good**" the increase in the skin compactness; they also thought that the product gives a feeling of comfort.
66.67% considered "**good**" and **13.33%** "**very good**" the increase in skin brightness; they also thought the skin looked fresher and more revitalized.

In conclusion we can confirm that the medical device MD-Tissue revealed to be a reliable and safe product for the face revitalization.
– This can lead to several different uses in aesthetic medicine. The fluid texture of the product is definitely very suitable for the treatment of the neck, décolletage and back of the hands.
Face applications can include several techniques such as the treatment with micro wheals, injections in acupuncture points, eye zone and forehead rejuvenation. ■

References

1. Kligman L. - Photoaging: manifestations, prevention and treatment. Clin Geriatr Med **1989**;5: 235-251.
2. Gilchrest B.A. - Skin aging and photoaging: an overview. J Am Acad Dermatol **1989**; 21: 510-513.
3. Kang S., Fisher G.J., Voorhees J.J. - Photoaging: pathogenesis, prevention and treatment. Clin Geriatr Med **2001**; 17: 643-659.
4. Fracassi P., Marottoli M.S. - Dizionario di Dermocosmesi. Tecniche nuove, **2006**.
5. Milani L. - Un nuovo e raffinato trattamento iniettivo delle patologie algiche dell'apparato locomotore. La Med. Biol., **2010**/3; 3-15.
6. De Bellis M. - Omeomesoterapia in medicina estetica, Scuola di Omeopatia-Omotossicologia e Discipline Integrate. Dispense AA. **2011-2012**.

Acknowledgements

The author thanks the BIOBASIC EUROPE SRL staff for their collaboration as well as for the use of their devices.

Author

Dr. E. Falconi Klein, MD
– Specialist in Dermatology
– Specialist in Allergology
Via Mauro Macchi, 42
I – 20124 - Milano

CLINICAL

G. Felloni

DERMOAESTHETIC FACIAL MEDICINE – INTEGRATED THERAPY

SUMMARY

Ageing is a generalised process that affects all organs; however, it is common to refer to the skin when talking about biological ageing. Psychological experience, chrono- and photo-aging, and skin are closely related. Stress, which is at the root of the alterations in the systems, leads to a chronic inflammatory state that disrupts the balance of organs, particularly the skin, resulting in the appearance of blemishes and wrinkles.
The skin is the largest organ in the human body and is in close connection with the Autonomic Nervous System: muscular tightening, which constricts the blood vessels resulting in less O_2 supply to the skin Tissues, and the excessive production of cortisol, correlate to the occurrence of pathologies and kinesthetics.
Unlike classic aesthetic medicine, which only treats the blemish without considering the person as a whole, the integrated multi-systemic and multi-level approach places the underlying causes of the blemish at the centre, acting mainly on the basic chronic inflammation to recover, reactivate and maintain the 'youthfulness', health and quality of the skin.

– The multi-systemic approach involves the use of biological drugs that can 'talk' to the cells and bioregulate them, allowing a state of global well-being to be achieved along with the aesthetic result and to enhance all the other treatments in the therapeutic protocol.

– Twenty female patients aged between 35 and 70 years were enrolled and underwent several multilevel steps: bio-detoxification (by means of an oral drainage and hydration therapy of the extracellular matrix, a systemic anti-ageing therapy and a body detoxification); biostimulation (by means of a local infiltrative therapy), accompanied in some cases by radiofrequency intradermal needle therapy, the application of biorevititalising acids and carboxytherapy. Both steps involve solutions acting at multiple levels due to the effect of BrSM natural multi-components capable of modulating the physiological mechanisms regulating ageing and Made, Guna-Collagen, and MD-Tissue. The effects of the therapy were assessed by means of a self-assessment questionnaire by the patients and with photographs.

KEY WORDS

AGEING, INFLAMMAGEING, WRINKLES, GUNA-COLLAGEN, MD-TISSUE

"One does not become old because a certain number of years have rained down upon us: one becomes old because one has abandoned one's ideals.
You will stay young as long as you stay receptive.
Receptive to what is beautiful, good and great.
Receptive to the messages of nature, of man, of the infinite".

Gen. Douglas A. McArthur (1880-1964)

INTRODUCTION

The skin is a constantly changing organ that performs numerous functions:
- coating and protection from external agents
- regulation of body temperature
- sending tactile and pain information to the Nervous System
- immune defence
- production of vitamin D
- elimination of toxic substances.

The skin microbiome, which is in continuous communication with the gut microbiome, is dynamic and changes over time; its stability is lower than the intestinal one, probably due to the greater exposure to extrinsic varying factors as genotype, gender, age, environment, climate, geographic area, lifestyle, work activity, personal hygiene, concomitant diseases, immune activity, and inflammation.

– The skin is a very complex organ that acts as a protective barrier against the external environment.

It is the largest organ in the human body; its average surface area is between 1.6 and 1.85 square metres; the skin surface is characterised by the presence of folds, ridges and orifices.

The pattern of the texture of the palmar lines is genetically determined (arcs, loops, swirls). During embryonic development they begin to take shape before the onset of hand movements (around week 11 of gestation), do not change throughout life, have a high discriminating power and uniqueness and serve as a clinical-diagnostic aid in certain Syndromes due to chromosomal aberrations.

The **Extracellular Matrix (ECM)** of the dermal connective Tissue contains glycosaminoglycans (hyaluronic acid,

DIFFERENCES BETWEEN INTRINSIC AND EXTRINSIC SKIN AGEING

CHARACTERISTICS	INTRINSIC AGEING	EXTRINSIC AGEING: PHOTO-AGEING
SKIN APPEARANCE	smooth surface, deepening expression lines, moderate loss of elasticity	knotty and thickened surface with spots tending to yellow, deep wrinkles, significant loss of elasticity
EPIDERMIS	soft and radiant	marked acanthosis, cellular apathy
ELASTIC TISSUE	increased, normal appearance	increased, degenerated into amorphous clusters
COLLAGEN	thickened, non-parallel bundles	decrease in collagen bundles and fibres: transformation from soluble to insoluble collagen
GLUCOSAMINOGLYCANS, PROTEOGLYCANS	slightly smaller	markedly increased
RETICULAR DERMIS	softer, decreased and inactive fibroblasts, decreased mastocytes, inflammation absent	thickened with elastosis phenomena, increased fibroblasts, hyperactive, mast cells markedly increased, infiltrated with mixed inflammation
PAPILLARY DERMIS	absent in the border areas with the dermis	solar elastosis

TAB. 1

chondroitin sulphate and dermatan sulphate); hyaluronic acid is distributed throughout the connective fibres in the spaces between the fibres.

– These molecules contribute to the elastic properties of the skin.

The subcutaneous Tissue (hypodermis) is the deepest layer and is connected to the dermis by septa of fibrous connective Tissue; it consists of adipose Tissue and collagen; there are also larger blood vessels, lymph vessels and nerves.

– With age, the skin becomes pale and thin with less tolerance to solar radiation exposure due to a decrease in the number of melanocytes; the decline in sebaceous and glandular activity leads to dryness and the appearance of wrinkles due to the loss of elastic fibres, reduced vascular supply and lower sexual hormones.
There is the onset of solar lentigo, seborrhoeic and actinic keratoses and telangiectasias.

There is a chrono- and photo-ageing (TAB. 1); the latter mainly affects areas exposed to sunlight.
– Ultraviolet rays act, partly directly and partly mediated by the production of free radicals, on RNA, DNA, proteins, cell membrane and cytoplasmic enzyme phospholipids.
– Free radicals attack collagen and determine cross-linking bonds between fibres in the dermis, making them less elastic; they also attack hyaluronic acid, lowering its quality and functions.

Certain types of wrinkles are classified as:
– linear
– graphic
– creases
– naso-labial.

The state of health of the stomach, intestines, kidney, liver, etc., can be 'read' from the particular signs on the face; this proves that a comprehensive, integrated anti-ageing medicine is required, considering not only local problematic issues, but also the person in his or her entire 'being'.

"Every problem you recognise is but a tiny dot on the radar screen of your well-being. Every time you experience a difficulty, homeostasis is working for you to bring you back into perfect balance. Your role is simply to relax and allow nature to take its course".
(Alan Cohen - writer)

Stress, underlying the alteration of the organic systems, leads to a chronic inflammatory state that causes cortisol levels to rise in an attempt to manage and extinguish Chronic Low Grade Inflammation.
Furthermore, of great importance is the Gut-Brain Axis, in which the gut microbiota is considered the second brain that is subsequently in close communication with the skin's microbiota.

The skin's microbiota actively participates in the dual protective function of the skin, as a physical and immune barrier that hinders the development of harmful bacteria, generating an environment which is hostile for their development; with its activity of degrading skin surface lipids, it also protects against the immunosuppressive action that UV radiation causes in the skin.

It is important to maintain a balanced composition of the microbiota in order to avoid the colonisation of harmful bacteria; when this balance is disrupted, inflammatory problems, infections, allergies and autoimmune diseases emerge.
– Recent studies have shown that the imbalance and destruction of skin microbial populations correlates with the worsening of existing pathological conditions (e.g. Atopic Dermatitis, Acne, Psoriasis).

– Based on this evidence, scientific re-

search has started to focus on the study of new cosmetic products containing bacteria which is useful in combating the skin disorders caused by pathogens.

When talking about PNEI regulatory Systems, it is possible to understand how stress is at the basis of alterations in these systems and the cause of Chronic Low Grade Inflammation, and how adaptogenic substances reduce the load caused by stress and are a valuable aid for an organism seeking a balance of health.

Due to its function as a protective interface between the inside of the body and the highly contaminated external environment, the skin is densely colonised by a diverse and active microbiota, a complex and dynamic ecosystem inhabited by bacteria, viruses, fungi and archaea. – These, collectively referred to as the 'skin microbiota', are fundamental to skin physiology and immunity. Interactions between skin microbes and the host can 'fall' anywhere along the *continuum* between mutualism and pathogenicity.

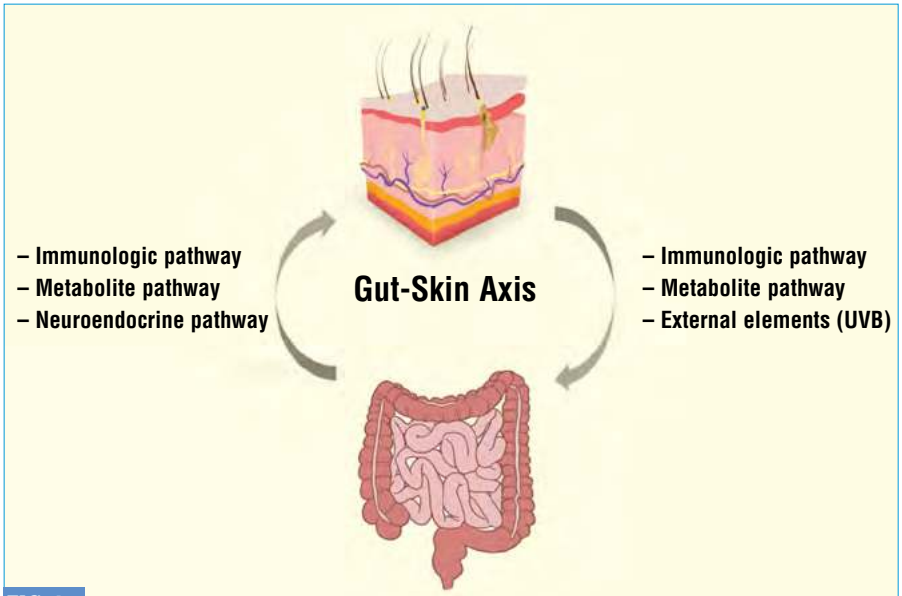

FIG. 1

Gut-Skin Axis.

Park D.H. *et* Al. – Comparative Analysis of the Microbiome across the Gut–Skin Axis in Atopic Dermatitis. Int. J. Mol. Sci. **2021**, 22, 4228. https://www.mdpi.com/1422-0067/22/8/4228

Although cause and effect are generally difficult to determine with certainty, changes in the skin microbiota clearly play a role in the pathobiology of multiple skin diseases and aesthetic disorders.

The skin microbiota is of great importance for human health and wellbeing; it is involved in several skin diseases such as Psoriasis, Eczema, Contact Dermatitis, food Allergies, Seborrotic Dermatitis, Acne rosacea and it plays an im-

FIG. 2 **Multi-systemic medicine.**

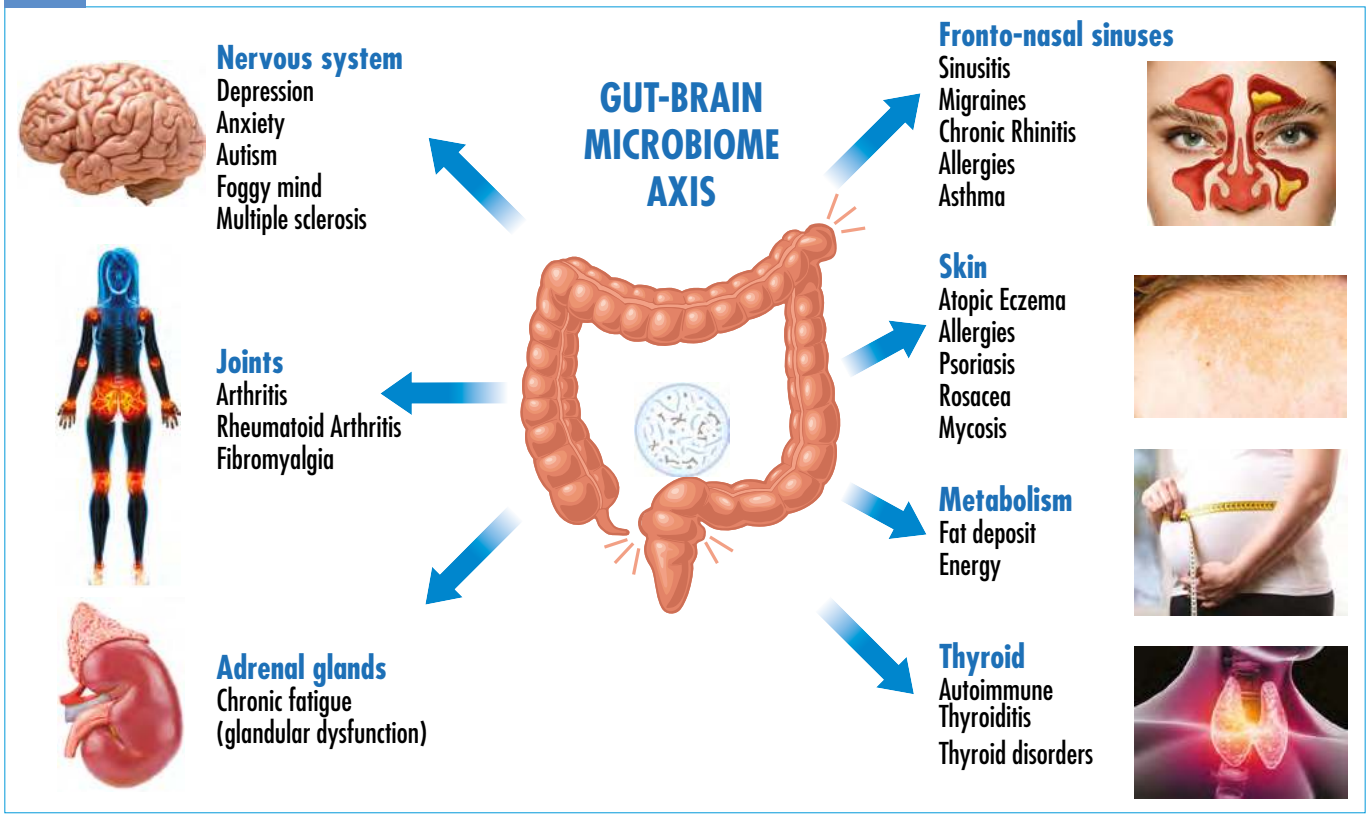

FIG. 3

Female, 40 years old. Slight skin laxity in the neck and "Venus rings" wrinkles; the patient underwent 4 sessions of biostimulation with Made (micro-injections); each session was performed every 2 weeks.

portant role in wound infections; it also plays an essential role in skin ageing, hence the importance of a **comprehensive** and **integrated therapeutic approach** that will act both topically and systemically with more physiological and natural methods.

– A crucial role in the onset of Acne, for example, is certainly played by *Propionibacterium acnes*, whereas atopic dermatitis involves *Staphylococcus epidermidis* and *Staphylococcus aureus*.

– Several ongoing studies aim at restoring the balance of the skin's microbiota and the subsequent well-being of the individual by means of skin therapies with prebiotics or probiotics and the use of thermal waters in subjects with Psoriasis.

For some dermatological diseases, a link has been shown with **intestinal dysbiosis** characterised by poor microbial biodiversity which is quite similar to that seen in patients suffering from Irritable Bowel Syndrome (IBS).
In many cases, the administration of certain strains of probiotics led to a lessening of intestinal and systemic inflammation and, subsequently, an improvement in skin symptoms.

– Such evidence demonstrates the existence of a true **'Gut-Skin Axis'** (FIG. 1).
The visceral brain presides over the vital functions of survival and is able to store stress and emotions, while the CNS regulates cognitive and relational function.

The gut produces neurotransmitters and psychoactive substances that influence moods (serotonin, endorphins) and the Gut-Brain Axis; consequently, the skin comprises direct links between these organs with reciprocal influences.

It is essential to rebalance the gut microbiome to achieve positive, enhanced and long-lasting effects on the skin.
The connection between gut and brain is via the vagus nerve and the release of serotonin (secreted mainly in the gut), melatonin, tryptophan, GABA, and Peptide YY*.
Oxytocin is also produced in the brain, but its formation can be favoured, via the vagus nerve, by a balanced microbiota and in particular by *Lactobacillus reuteri*.

Performing the function of support, union and protection between the different Tissues are the connective Tissues, within which ECM is present in abundance.
– To put it simply, the ECM has the fundamental purpose of connecting the various cells in the body. Its most abundant component is **collagen**.
Another of the components of the ECM is the so-called **Fundamental Substance (FS)**, a colloidal gel-like structure that is deposited in the interstices of the fascial structure or 'Fascial System'.
A particular feature of the FS is that inside there are structural elements such as lymphatic vessels, fibroblasts and fibrocytes, axons and arterio-venous capillaries. It is particularly the presence of all these elements that gives the ECM the articulated capacity to communicate at a distance between organs and apparatuses, albeit very different ones.

When an acid-base imbalance occurs, the composition of the FS is modified, becoming less fluid, reducing some of its most important functions, including its lymphatic drainage capacity, venous-capillary interchange and the plasticity of the Fascial System.

– In addition, it should be noted that the ECM also contains toxic metabolites.
The latter, together with the different state of FS and its ionic concentration, de-

* **Editor's note**: Peptide YY is a hormone produced by the L-cells of the mucosa of the ileum and colon.

termine both the reactive modes and the development of certain characteristics of the individual, as well as ageing and the involvement of the Immune, Hormonal and Vegetative Nervous Systems.

• It is mainly the Lymphatic System that ensures the efficiency of the ECM.

Not all of the capillary transudate fluid re-enters the vessels: 10% of it (≈ 3 L/day), is deposited in the Tissues, turning into interstitial fluid.

– Therefore, it is essential that the Lymphatic System is able to operate at its best in the re-circulation of proteins and fluids: only in this way can correct homeostasis be maintained and fluids be prevented from accumulating in the ECM.

– When the excretory organs fail to adequately eliminate acidic waste, it accumulates in the ECM, which reacts through a general detoxification action, like a *metabolic sponge*.

The accumulation of acidic residues, resulting from catabolism, will however take place at the expense of the transformation of colloidal substances from the sol to the gel state; the functions of

BEFORE AFTER

BEFORE AFTER

BEFORE AFTER

FIG. 4

Females, 65-67 years old. Severe degree of skin ageing.
– Six multilevel biostimulations were carried out on a weekly basis with Made + Guna-Collagen in a cocktail, followed by MD-Tissue; patients were then subjected to laser CO_2 treatment fractionated with double-pass and radiofrequency intradermal needling to complete the therapeutic procedure.
Maintenance with multi-level biostimulation, 2/month.

FIG. 5

Female, 65 years old. Increased evidence of advanced ageing in the middle-lower third with pronounced perioral micro-wrinkles and deep wrinkles in the nose-genius area; 3 sessions of biostimulation with MD-Tissue every 2 weeks were carried out.

FIG. 6

Female, 53 years old. Skin laxity on the inner side of the arm; 3 biostimulations every 2 weeks with Made + Guna-Collagen in a cocktail preceded by carboxytherapy.
– The patient continued with multi-level biostimulation and without needles in the same session, maintaining carboxytherapy, 1/month.

the ECM, together with the exchanges between cell and matrix, will tend to slow down.
The centrifugal force produced by the blood circulation pushes all the denser and heavier substances towards the periphery of the organism; skin changes caused by external irritation are rarer than those caused from within due to toxemia.

– The skin is thus to be considered as a draining organ that comes to the aid of the kidney, liver and lymphatic system.

Lymphatic drainage, **liver detoxification**, the **functionality of the ECM, intestinal microbiome,** and **acid-base rebalancing** are therefore fundamental.

The studies of Candace Pert, author of *"Molecules of emotion. Why you feel the way you feel"* have been able to ascertain the link between emotions and physiology, so much so that they claim that: *"this more holistic approach complements the reductionist view, expanding it rather than replacing it, and proposes a new way of understanding health and disease, not only to us scientists but also to laymen. We could define the entire system as a psychosomatic network of information, linking the psyche, comprising all that is non-material in nature, such as mind, emotions and soul, to the soma, which is the material world of molecules, cells and organs. Mind and body, psyche and soma"*.

▶ Unlike classical aesthetic medicine in which we intervene by directly treating the imperfection, without considering the person as a whole, **the multi-systemic approach** mainly targets the causes at the origin of the blemish, acting on the chronic inflammation to recover, reactivate and maintain the "youthfulness", health and quality of the skin (FIG. 2).

– This innovative approach for the patient acts on cellular vitality and restores the physiological balances that sustain them.
Blemishes are considered the reflection of an imbalance in the entire organism; by acting on the real causes of ageing and related phenomena, a state of global well-being can be achieved.
We are aiming for a person's harmony and psycho-physical well-being; **nutrition**, **nutraceutics**, **water** and **exercise** play a very important role.

– There are two distinct therapeutic steps that can be applied successively or in parallel.
STEP 1: bio-detoxification, through systemic oral therapy, aimed at draining toxins from the ECM, systemic anti-aging therapy and body detoxification, when necessary;
STEP 2: biostimulation through local injection therapy, aimed at biostimulating cellular turnover processes.

Both steps provide solutions that act at multiple levels through the effect of multi-component/multi-target natural medicines capable of modulating the physiological mechanisms that regulate ageing, without side effects.
STEP 1 can be enhanced by low-dose signal molecules capable of stimulating Tissue trophism.
STEP 2 is multi-layered through **low-dose multi-component/multi-target drugs** and **Collagen Medical Devices**, which are able to modulate the physiological mechanism leading to ageing; the latter act as scaffolds of the ECM, able to replace a structural vacuum.

– For a customised therapeutic strategy, they can be used individually or both, at several levels.

MATERIALS AND METHODS

• Systemic therapeutic protocol:
– Proflora, 1 sachet/day; it is a symbiotic food supplement containing 6 different probiotic bacterial strains that promote the natural well-being of the intestinal microflora;
– Guna-Matrix, 20 drops x 2/day + **Guna-Lympho**, 20 drops x 2/day x 2 consecutive months.
Repeat Guna-Matrix cyclically throughout the year.
– Lipidic Vitawin C, 3 capsules/day to be taken at main meals x 2 consecutive months.

• Local therapeutic protocol:
– Guna-Collagen, 1 fl + **Made**, 1 fl; weekly infiltrative therapy for at least 5 consecutive weeks, in a mesotherapeutic mode by means of an injector with the needle depth controlled by a computerised system, or by means of manual mesotherapy injections.
– In some patients where the ageing process needed deeper action, **MD-Tissue** was injected in the same way.

The infiltrative technique is the microinjection technique, which is very suitable for reaching the dermal layer.
– The 30G needle is inserted very slowly and constant pressure is applied to the syringe plunger until a small white intradermal papule appears.
Depending on skin ageing, these treatments were accompanied by sessions of **carboxytherapy** [preceding biostimulation (STEP 2) and performed in the same session], with **needle-free biostimulation** and more invasive techniques such as the **fractioned CO_2 laser** and **intradermal needle-assisted radiofrequency**.

– Carboxytherapy consists in the subcutaneous administration of medical CO_2 in a gaseous state; it produces vasodilation and reactivation of the microcirculation, improves blood flow and skin metabolism, and increases tissue oxygenation.

– Needle-free biostimulation by means of peeling based on 33% trichloroacetic acid, kojic acid and hydrogen peroxide preceded by skin microneedling was generally carried out after micro-injections of the multi-level medicine products to enhance their effects.

– Treatment with the fractional CO_2 laser involves the execution of many tiny (a few microns) holes by means of a laser beam that reaches the dermis; it causes heating that generates the formation of young collagen.

The presence of new collagen results in the rejuvenation of the skin surface, from which corneous cells are removed, and the dermis, which thus acquires greater lustre and tone.
– Biostimulation treatments generally precede laser sessions to make the surface fertile and healthy in order to enhance their effects.

– Intradermal needle radiofrequency is the new generation microneedling device that offers immediate and long-term results, with well-tolerated sessions and very short recovery times.
This minimally invasive treatment helps stimulate natural collagen production and is effective in improving facial and neck wrinkles and acne scars.

Collagen synthesis stimulation and induction treatments, better known as

FIG. 7

The patient underwent 5 sessions of biostimulation with Made (microinjections) on a weekly basis using the needle gun and 1 session of fractioned CO_2 laser in "soft" mode: thanks to the BrSM medication, an optimal result was achieved, maintained and enhanced with the CO_2 laser, using parameters far below classical non-surgical blepharoplasty treatments.

FIG. 8

Female, 53 years old. The patient underwent 5 sessions of carboxytherapy followed by biostimulation on a weekly basis; there was a significant decrease of micro- and macro-wrinkles, especially in the periocular area; texture healed.

FIG. 9

Female, 50 years old. Medium to severe chrono- and photo-ageing on the neck.
– Four biostimulation sessions were carried out followed by multi-layer application with manual acid massage (needle-free biorevititalisation) on a weekly basis.

skin resurfacing, are among the safest and most popular.

Skin microneedling requires the use of disposable needles that gently penetrate the dermal-epidermal Tissue at specific depths; it stimulates the release of multiple growth factors that induce neo-collagenesis and neo-elastogenesis in the treated area via a cascading effect.
It is a dermo-epidermal renewal treatment that does not damage the epidermis, is not selective on melanocytes and does not cause post-inflammatory pigmentation.

Biostimulation can precede radiofrequency by a few weeks or can be performed in the same session, after letting the Tissues cool down with a soothing mask; the multilevel treatment acts as an aid in recovering the discomfort produced by radiofrequency and 'educating' the tissues to a rapid functional recovery with an enhanced effect.

– All these multilevel treatments result in different effects:
1) anti-inflammatory action
2) local circulation stimulation
3) Tissue stimulation
4) collagen production stimulation
5) wrinkle reduction
6) skin firming
7) bioscaffolding action.

At the end of each treatment, approximately 1 ml of a beauty gel was applied *in situ* with a gentle manual massage to penetrate the product.

– The evaluation of the results was based on the patients' satisfaction using the PAIS scale (Editor's note: The Psychosocial Adjustment to Illness Scale) and photographs.

RESULTS

This study shows that BrSM therapy, nutraceuticals and the multi-system approach are effective and highly efficient

in both the prevention and treatment of skin ageing.

– Patients report markedly improved well-being and general psycho-physical health compared to the start.

The total absence of adverse reactions and the results obtained ensured excellent compliance with both outpatient and home therapy.

– The study shows that the protocols applied are effective and safe in treating skin ageing (FIGG. 3-10).

DISCUSSION

Patients maintain their results through some basic daily activities: a proper diet, calorie restriction, macronutrient allocation, customised nutraceuticals, hormones, anti-free radical antioxidants, average aerobic and anaerobic exercise, stress management, self-care, sexual performance and socialising.

– Human beings are constantly changing; the processes of growth and ageing are the most striking examples of this reality.
Becoming aware of one's own evolution, of the rhythms and interconnections that keep a body alive, means learning to understand and to take care of oneself in order to achieve inner and outer harmony.

From the above, it is easy to understand the importance of a comprehensive and patient-friendly approach: doctors must not limit themselves to a single blemish, but... must look beyond the skin.

The secret to staying 'young' and healthy is to provide the body with the necessary tools to activate the regeneration and functional recovery processes.

FIG. 10

Female, 53 years old. The patient underwent 3 sessions of biostimulation, 1 session every 2 weeks; at the last session, needle radiofrequency was also used.

Essential References

– Barabási A.L., Oltvai Z. – Network biology: understanding the cell's functional organization. Nat Rev Genet 5, 101-113; **2004**.
– Bianchi I. – Argomenti di Omotossicologia. Vol. 1. Guna Ed.; **1987**.
– Bianchi I. – Approccio omotossicologico alla patologia del Tessuto connettivo. La Med. Biol., **1996**/3; 11-24.
– Cainelli T. *et* Al. – Manuale di Dermatologia medica e chirurgica. McGraw-Hill Education; **2017**.
– Cazzavillan S., Santangà D. – Inflammaging. Tecniche Nuove Editore; **2020**.
– Compostella R. – Ayurveda maharishi. Tecniche Nuove Editore; **2018**.
– Corman L. – Viso e carattere. Iniziazione alla morfopsicologia. Mediterranee Edizioni; **2003**.
– De Bellis L., Poli A. – Alimentazione, nutrizione e salute. Edises; **2019**.
– De Bellis M., Frasca N. – Terapie delle rughe e del rilassamento cutaneo con iniezioni intradermiche di un farmaco omeopatico complesso (MADE®) - Risultati di uno studio multicentrico su 681 pazienti. La Med. Biol. **2004**/2; 7-19.
– Del Prete M., Lozzi A. – *Low dose Medicine* ed Infiammazione. IPSA Editore; **2017**.
– Mastrodonato F. – Medicina Biointegrata. Tecniche Nuove Editore; **2001**.
– Maggio C. – 100 anni da giovane. Edizioni L'età dell'Acquario; **2012**.

- Milani L. – Terapia dell'invecchiamento della matrice: la ricarica dell'orologio biologico. La Med. Biol., **2004**/4; 17-25.
- Perra A. – L'universo della matrice extracellulare. Advanced Therapies; **2018**.
- Pignatti M. – Dermobiotica. Alimentazione, microbiota, pelle. Minerva medica Ed.; **2018**.
- Pinoli L.M. – Terapia *low dose*, nutraceutica fisiologica ed alimentare dell'Infiammazione Cronica Sistemica di Basso Grado. La Med. Biol., **2016**/3; 37-46.
- Schiff M. – La memoria dell'acqua. Edizioni Andromeda; **2011**.
- Zanghirati W. – Fondamenti di fitoterapia. Istituto Medicina Naturale di Urbino; **1997**.

Fig. 2: (recomposed)
Source: Manera S. – Cervello intestino, un legame indissolubile. p. 94. Macro Edizioni, 2021.

Author

Dr. med. Giulia Felloni

- Level II Master in Aesthetic Medicine; Level II Master in Cosmetic Dermatology; Level II Master in Dermatological and Aesthetic Laser Therapy; Level II Master in Integrated Anti-Ageing Therapy
- Specialist in Nuclear Medicine and Radiotherapy

Via Don Giovanni Bosco, 7/C
I – 44122 Ferrara

Healthspan versus Lifespan
Il ruolo della Medicina Estetica

SIME 2025 | 46° CONGRESSO Società Italiana di Medicina Estetica | 20° CONGRESSO aimaa Accademia Italiana di Medicina Anti-Aging

16, 17, 18 MAGGIO
Roma Convention Center La Nuvola

MEDICAL DEVICE A BASE DI COLLAGENE, MD-TISSUE, NEL RINGIOVANIMENTO CERVICO-FACCIALE

Dott. Egidio Riggio, *Dirigente medico in Chirurgia Plastica presso l'IRCCS Istituto Nazionale dei Tumori Milano*

INTRODUZIONE E OBIETTIVI:

La cute invecchia perdendo tono ed elasticità con netta riduzione della matrice extracellulare dermica essenzialmente a causa di minor sintesi di collagene dopo i 35 anni e aumento della degradazione di collagene per l'azione proteolitica di enzimi MMPs (metalloproteinasi di matrice) che degrada il collagene di tipo I e III. Differentemente, nella cute giovanile non esposta a raggi solari, sintesi di collagene e sua degradazione sono in equilibrio fisiologico conservando l'integrità della pelle. Il collagene eterologo funge da bioscaffold stimolando migrazione e produzione dei fibroblasti. Un trattamento iniettivo a base di collagene porcino di tipo I può trovare indicazioni terapeutiche, usato singolarmente o associato ad altri metodi nel distretto viso-collo per trattare: rughe; ristrutturazione del connettivo sottocutaneo e perivascolare e del trofismo connettivale danneggiato da inquinanti esogeni/dismetabolismi.

MATERIALI E METODI:

Una serie di 12 pazienti (età media 53; 45-70) affetti da rughe al collo (8), barcode (5), fronte (3), guancia (2), sono stati trattati con iniezioni di collagene tipo I, dispositivo medico di derivazione porcina, MD-TISSUE a basso peso molecolare integrato con vit.C+B1–B2–B6 e gluconato di magnesio con tecnica di tunnellizzazione retrograda mediante aghi 27-30 gauge, con sessioni multiple da 2 a 6 per anno (media 3), distanziate 3-8 settimane.

PRE TRATTAMENTO

COLLAGEN

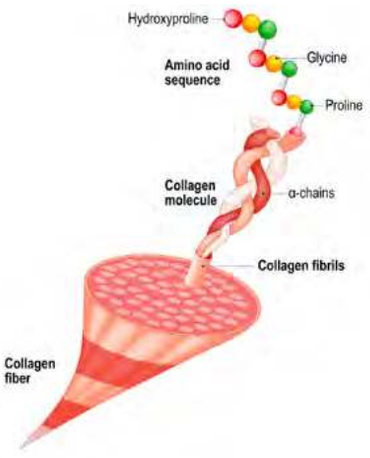

POST TRATTAMENTO

RISULTATI:

In tutti i casi il miglioramento estetico delle rughe è stato ottenuto mediante obiettivo confronto fotografico pre-post e mediante valutazione grado di soddisfazione delle pazienti in una scala da 0 a 10 con media di 8,5. In alcuni casi e in singole sessioni il prodotto è stato associato in sedi contigue ma non nelle medesime del collagene ad altri trattamenti topici.

CONCLUSIONE:

La biostimolazione con collagene come medical device di classe-III contiene il deterioramento fisiologico della cute e del tessuto connettivo sub dermico, con ottimale rapporto costi/benefici e complicanze prodotto-correlate di alcun rilievo clinico.

REFERENZE:

1. Ruiu DE. Advanced Therapies 2012; 1: 30-39
2. Falconi Klein E. Face Revitalization – Biolifting with MD-Tissue. Physiological Regulating Medicine 2012; 15-20
3. Aamodt JM, Grainger DW. Extracellular matrix-based biomaterial scaffolds and the host response. Biomaterials, 2016; 86, 68–82.
4. Rinaldi F, Pinto D, Trink A, Giuliani G, Sparavigna A. In vitro and in vivo Evaluation on the Safety and Efficacy of a Brand-New Intracutaneous Filler with α1-R-Collagen. Clin Cosmet Investig Dermatol. 2021;14:501-512. https://doi.org/10.2147/CCID.S295618
5. Gardeazabal L, Izeta A. Elastin and collagen fibres in cutaneous wound healing. Exp Dermatol. 2024;33(3):e15052. doi: 10.1111/exd.15052. PMID: 38483134.
6. Salvatore L, Natali ML, Brunetti C, Sannino A, Gallo N. An Update on the Clinical Efficacy and Safety of Collagen Injectables for Aesthetic and Regenerative Medicine Applications. Polymers. 2023; 15(4):1020. https://doi.org/10.3390/polym15041020
7. Randelli F, Menon A, Giai Via A, Mazzoleni MG, Sciancalepore F, Brioschi M, Gagliano N. Effect of a Collagen-Based Compound on Morpho-Functional Properties of Cultured Human Tenocytes. Cells. 2018; 6;7(12):246. doi: 10.3390/cells7120246.

Rehabilitacion (Madr). 2021 Sep 3; S0048-7120(21)00059-1. doi: 10.1016/j.rh.2021.04.001.
Online ahead of print.

[Efficacy of collagen infiltrations in the pelvic pain caused by episiotomy and caesarean scars. Pilot randomized clinical trial]

[Article in Spanish]

G Romero-Cullerés[1], A Amela-Arévalo[2], C Jané-Feixas[3], A Vilaseca-Grané[4], A Arnau[5], N Torà[5]

Affiliations PMID: 34489100 DOI: 10.1016/j.rh.2021.04.001

1 Servicio de Medicina Física y Rehabilitación, Althaia Xarxa Assistencial Universitària de Manresa, Manresa, Barcelona, España
2 Facultat de Ciències de la Salut, Universitat de Vic-Universitat Central de Catalunya (UVicUCC), Manresa, Barcelona, España
3 Servicio de Ginecología y Obstetricia, Hospital de Igualada, Igualada, Barcelona, España
4Servei d'Atenció a la Salut Sexual i Reproductiva (ASSIR) Bages, Centre d'Atenció Primària Bages, Manresa, Barcelona, España
5 Unitat de Recerca i Innovació, Althaia Xarxa Assistencial Universitària de Manresa, Manresa, Barcelona, España

Abstract

Background and aims: Pelvic pain is a frequently consulted symptom in pelvic floor rehabilitation units. The aim of this study was to evaluate the efficacy of collagen infiltrations in pain and the appearance of scars from perineal tears, episiotomies and caesarean sections.

Material and methods: Pilot randomized, controlled and single-blind clinical trial. Control group (CG) patients received conventional rehabilitation treatment. Additionally, those in the intervention group (IG) received 3-5 collagen infiltrations. The patients were evaluated at baseline and 6 weeks post-intervention. The main outcome was pain and it was evaluated with the Visual Analog Scale and McGill Pain Questionnaire. As secondary outcomes, the appearance of the scar was evaluated by Vancouver Scar Scale and the Patient Scar Assessment Scale. A sample of 15 women was analysed, 8 in the CG and 7 in the IG.

Results: The mean age was 33.1 years (SD 4.1). The intragroup analysis showed a significant decrease of the Visual Analog Scale punctuation and total McGill Pain Questionnaire score and the PRI-Emotional dimension of the McGill Pain Questionnaire. In the IG, a significant decrease was also observed in the PRI-Sensorial and PRI-Evaluative dimensions in comparison with baseline situation. In both groups, a significant improvement in the appearance of the scar was observed. In the intergroup analysis, a greater decrease in pain was observed in PRI-Sensorial subscale of the McGill Pain Questionnaire in the IG (-15.1 vs. -6; P=.040).

Conclusions: Collagen infiltrations may improve pain and the appearance of painful scars.

Keywords: Caesarean section; Cicatriz de cesárea; Collagen; Colágeno; Dolor pélvico; Episiotomy; Episiotomía; Infiltración; Infiltration; Pelvic pain; Rehabilitación; Rehabilitation.

Introduction

Pelvic pain (PP) is a frequent symptom of consultation in pelvic floor rehabilitation units after being treated in other services (Gynaecology, Urology, General Surgery and Digestology). It can affect more than 15% of women and only 30% of cases are attributable to gynaecological causes[1]. PP is a non-cyclic hypogastric pain that interferes with quality of life, being an important cause of discomfort, anxiety, increased visits to the doctor and surgery. It fundamentally affects women, in the absence of infectious and/or tumoral disease[2,3]. One of its causes is secondary to episiotomy or caesarean section scars. The incidence of postpartum PP due to episiotomy varies from 39% to 69%[4,5], remaining persistent in 6% to 10% at 12 months [5-7]. In caesarean sections, the frequency of immediate pain reaches 85-90% and persistent pain ranges between 8-22%[7,8]. There are different options in the therapeutic approach to painful scars: from silicone injections,

corticosteroids, subdermal procaine, immunomodulators, radiotherapy, laser therapy, cryotherapy, topical vitamin E, topical retinoid, colchicine, antihistamines or physiotherapy until surgery [9-11]. Physiotherapy treatments include ultrasound, transcutaneous nerve stimulation, as well as pelvic floor exercises and manual techniques. Massage of the scar, once the inflammatory phase has elapsed and complete repair of the dehiscence, improves flexibility and blood supply, and prevents possible adherence of the scar. [12-15]

There is little evidence of the efficacy of treatment with local infiltrations. Local collagen injections have recently been introduced. It is a health product based on purified type I collagen, together with ascorbic acid, magnesium gluconate, pyridoxine hydrochloride, riboflavin and thiamine hydrochloride. Type I collagen confers plasticity and flexibility in the final process of wound healing. The application of collagen in painful scars can confer these properties early and, therefore, reduce pain. There are different types of collagen infiltrations whose efficacy has been proven in disorders of the musculoskeletal system[16-18] such as myofascial pain syndrome[19,20] or atypical fascial neuralgia, and as a rejuvenating treatment[16]. However, its efficacy in the treatment of painful scars has not been evaluated. The aim of this study was to evaluate the efficacy of collagen injections on the pain and appearance of painful scars from perineal tears, and/or caesarean sections compared to conventional treatment with rehabilitation.

Material and methods

Design

Randomized, controlled, single-blind pilot clinical trial of patients with PP secondary to painful scars or caesarean sections. The protocol was approved by the Clinical Research Ethics Committee of the Fundació Unió Catalana d'Hospitals (code CEI17/73) and registered in clinical-trials.gov (NCT04112888). The study was conducted in accordance with current legal and regulatory requirements and following international ethical guidelines for research involving human beings. The results have been reported in accordance with the CONSORT 2010 statement.[21]

Study subjects

The study sample was obtained from patients referred between the months of April 2017 and May 2018 to the Pelvic Floor Rehabilitation consultation of our center, due to PP secondary to painful scars from both episiotomy and caesarean section. Women between 18 and 45 years old with a history of caesarean section or episiotomy delivery, with pain in the scar, who agreed to participate in the study and signed the informed consent were included. Women with PP due to other causes, mental or cognitive disorders, pregnancy, pacemaker carriers, treatment with oral anticoagulants, local infections, presence of episiotomy granuloma, total or partial denervation of the pelvic floor, and neurological diseases were excluded.

Randomization

Random assignment to the group control (CG) or intervention group (IG) was performed at the baseline visit. A list of 8 blocks with 2 patients per block was generated using a random sequence generation software (http://www.randomization.com). This process was the responsibility of the Unitat de Recerca i Innovació.

Study groups

The CG patients received conventional treatment of 8 individual rehabilitation sessions of 45 min. Two weekly sessions were scheduled for 4 weeks. The techniques of massage therapy, muscle stretching, fascia work were performed by the same physiotherapist specialized in pelvic floor. Scar massage therapy is a massage that consists of moving the tissues in all directions. Longitudinal and circular movements were made to release the tension, horizontal and vertical zigzag movements forming an «S», small pinches lifting the skin around the scar and, finally, rolling. Myofascial work consists of the relaxation of the fasciae to treat soft tissues that have suffered trauma, such as a scar. Work was done at the level of deep planes by means of

crossed hands/fingers or by placing one hand on top of the lesion and the other at the level of the sacrum, seeking restriction and causing sliding to improve mobility. Iliac psoas, piriformis, gluteal and hamstring stretches were performed. IG patients received the same rehabilitation treatment as CG patients. Additionally, IG patients received 3 (in case of episiotomy) to 5 (in case of caesarean section) injections of MD-Tissue® collagen into the scar once a week. Infiltrations of 2 ml (one vial) of collagen were performed in the episiotomy scars and 4 ml (2 vials) in the caesarean scars. Based on clinical criteria, it was decided to perform 3 to 5 infiltrations, which is the minimum number of infiltrations in order to be able to objectify clinical responses, performing more infiltrations and larger volumes in caesarean sections as they are larger. The rehabilitation doctor performed the intradermal infiltration using the tunnelling technique.

Procedure

The baseline assessment was carried out by the rehabilitation doctor. The demographic and clinical information of the patient (age, pathological and gynaecological-obstetric history) was collected, a basic examination of the pelvic floor was performed, evaluating the capacity for voluntary vaginal contraction (modified Oxford scale) and the areas to be infiltrated were located. For the subjective assessment of pain, the visual analogue scale (VAS)[22] and the McGill Pain Questionnaire (MPQ, «McGill pain questionnaire»[23]) validated in Spanish by Lázaro *et al.*[24] were used. To assess the appearance of the scar, the rehabilitation physician used the Vancouver Scar Scale (VSS) and the patient used the Patient Component of the Patient Scar Assessment Scale (PSAS) of the Patient and Observer Objective Assessment Scale.[25,26] An initial photograph of the scar was taken. Patients were reassessed 6 weeks postoperatively by a midwife blinded to group assignment. Information was collected through the VAS, the MPQ, the VSS and the PSAS, adding the subjective perception of scar improvement using the clinician's (CGI-I) and patient's (PGI-I) global impression scales.[27,28] A new photograph of the scar was taken to compare it with the baseline. Initially, 30 patients were evaluated for eligibility, of which 14 (46.7%) were excluded. Of the remaining 16, 8 were assigned to the CG and 8 to the IG. One patient moved from home before the post-intervention visit, so finally 8 in the CG and 7 in the IG were analysed (Fig. 1).

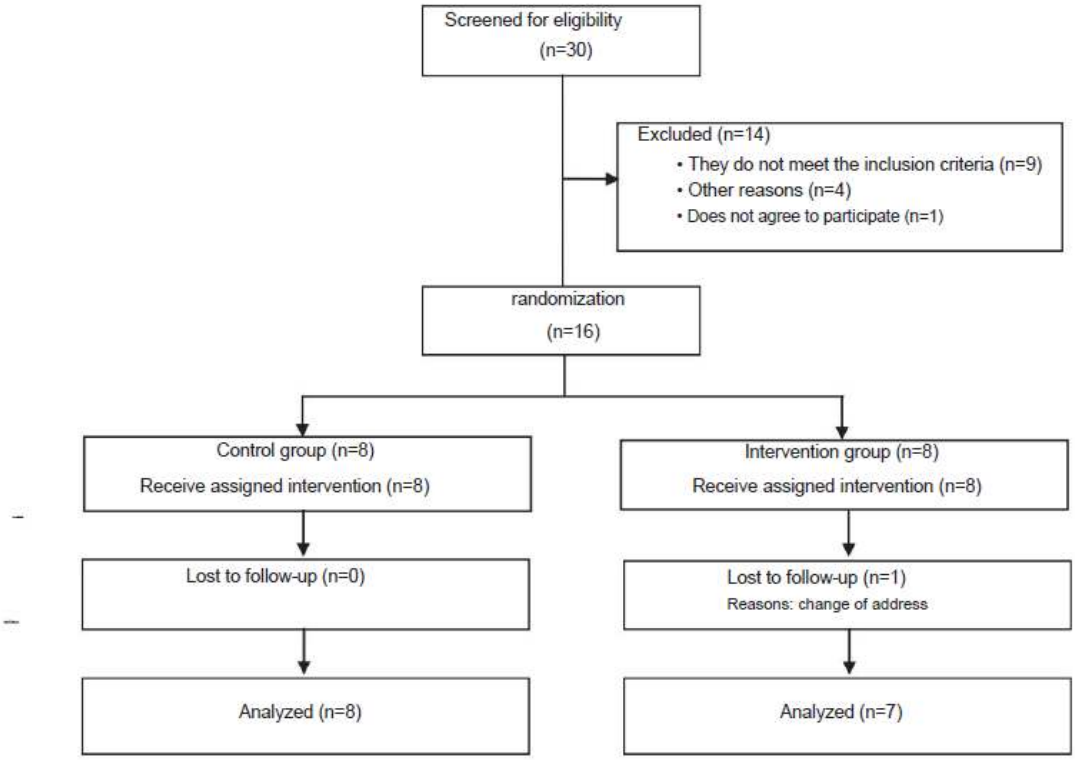

Figure 1 Flow chart.

Primary and Secondary Dependent Variables

The primary dependent variable was pelvic scar pain according to VAS and MPQ. The VAS makes it possible to measure the intensity of pain, which is described by a 10-cm horizontal line whose ends are the extreme expressions of pain. Score from 0-10. The MPQ is made up of 64 descriptors distributed in 19 subclasses (12 sensory, 3 miscellaneous-sensory, 3 emotional and an evaluative). Each of the descriptive terms is assigned a number or range that allows a score to be obtained according to the words chosen, thus obtaining the Pain Rating Index (PRI). Likewise, it allows assessing qualitative and quantitative characteristics of the pain experience by dividing the global results into three subscales: PRI-Sensory (12 subclasses), PRI-Emotional (3 subclasses) and PRI-Appreciative (1 subclass). As secondary dependent variables the appearance of the scar and the CGI-I and PGI-I were evaluated. VSS and PSAS were used to assess the appearance of the scar. The VSS evaluates 4 characteristics of the scar, such as pigmentation, vascularity, flexibility and height. The score range is between 0 and 10; the higher the score, the worse the healing. The PSAS allows to evaluate, on a numerical measure and subjectively, the symptoms related to pain, itching, colour, stiffness, thickness and relief. Each of the 6 questions has a value from 1 to 10, with a score of 10 being the worst scar imaginable or the worst feeling, and a score of 1 being normal skin. For the assessment of the global improvement after the intervention, the PGI-I scale was used, which describes the patient's perception of improvement between the categories of: much better, much better, a little better, no change, a slightly worse, much worse and much worse. The CGI-I describes the perception of improvement by the physician responsible for the treatment between the categories of: much better, better, no change, worse and much worse.

Statistical analysis

Continuous variables are summarized with the mean and standard deviation. Categorical variables are expressed in absolute value and relative frequencies. For the analysis of homogeneity of the baseline characteristics of both groups, the Student's t test was used to compare means with a normal distribution, and the Mann-Whitney U test for variables with a non-normal distribution. Fisher's exact test or Monte

Carlo's exact method was used for the comparison of proportions. For the efficacy analysis, the difference between the value obtained in the post-intervention assessment (6 weeks) and the baseline value of the main and secondary dependent variables was calculated for each one of the groups, together with its 95% confidence interval. Student's t test was used to compare the difference in means with normal distribution and the Mann-Whitney U test for variables with non-normal distribution. Cohen's d was calculated as a measure of effect size. A value ≤ 0.2 is considered a small effect, a d around 0.5 as a moderate effect and a d ≥ 0.8 as a large effect. For the comparison of the impression scales of global improvement post-intervention between the CG and IG used the exact Montecarlo method. The level of statistical significance used was 5% bilateral ($p < 0.05$). Data was analysed using IBM®SPSS®Statistics for Windows version 25 (IBM Corp, Armonk, New York, USA) and R® version 3.3.2 (R Foundation for Statistical Computing, Vienna, Austria).

Results

Baseline characteristics (Table 1) were similar in both groups, with a mean age of 33.1 (SD 4 ,1). The proportion of caesarean sections was higher in the CG than in the IG (50.0 vs. 28.6%; $p = 0.608$). The subjective perception of baseline pain according to the VAS was higher in the CG than in the IG (7.5 vs. 5.7; $p = 0.021$). Table 2 shows the differences in the means between the post-intervention assessment and the baseline for each one of the groups. In the intragroup analysis, a significant decrease in pain (VAS, MPQ, PRI-Emotional) and a significant improvement in wound healing (VSS) were observed in both groups. In the IG, a significant decrease was also observed in the PRI-Sensory and the PRI-Value. In the intergroup analysis, a statistically significant difference was observed in the PRI-Sensory subscale ($p = 0.040$). The decrease in the PRI-Sensory score was higher in the IG compared to the CG: −15.1 (−22.2 to −8.1) vs. −6 (−12.6 to 0.6). No significant differences were observed in the rest of the scales. However, despite the fact that a significant decrease in pain was observed in both groups according to the overall score obtained on the MPQ, this was higher in the IG (Cohen's $d = −1.02$). The decrease in the MPQ score in the IG was −17.4 (−25 to −9.9) vs. −8.4 (−16.3 to −0.4) of the CG. Table 3 shows the PGI-I and the CGI-I after the intervention according to the study group. The proportion of patients who scored much or very much better was lower in the CG than in the IG (50.0 vs. 71.5%; $p = 0.814$). The clinician rated 87.7% of the patients in the CG and 100% of those in the IG as much or very much better ($p = 1.000$). None of the patients presented complications or adverse reactions due to infiltrations.

Table 1 Baseline characteristics

	Control n = 8	Intervention n = 7	p
Age (years), "mean (SD)	34,5 (3,7)	31,4 (4,1)	0,152
Primiparous, n (%)			
No	7 (87,5) 1	7 (100,0) 0	1,000
Yes	(12,5)	(0,0)	
Birth rate, n (%)			
Vaginal	4 (50,0) 4	5 (71,4) 2	0,608
Caesarean section	(50,0)	(28,6)	
Instrumental, n (%)			
No	1 (25,0) 3	2 (40,0) 3	1,000
Yes	(75,0)	(60,0)	
Oxforda, n (%)			
0 a 2	2 (50,0) 2	3 (60,0) 2	1,000
3 a 5	(50,0)	(40,0)	
Pain in relationships, n (%)			
No	4 (50,0) 4	2 (28,6) 4	0,608
Yes	(50,0) 0	(57,1)	
not relations	(0,0)	1 (14,3)	
Pelvic pain, mean (SD)			
EVA	7,5 (0,9)	5,7 (1,4)	**0,021**
McGill Pain Questionnaire	28,9 (8,0)	31,1 (4,8)	0,525
PRI-Sensorial	23,6 (8,3)	26,1 (2,5)	0,456
PRI-Emotional	2,5 (1,7) 2,8	2,7 (2,1) 2,3	0,867
PRI-Valuation	(1,2)	(0,5)	0,463
Lesion appearance, mean (SD)			
Vancouver Scar Scale	5,5 (1,9)	4,6 (1,9)	0,356
Patient Scar Assessment Scale	34,0 (9,9)	25,4 (11,2)	0,109

The data highlighted in bold corresponds to a statistically significant difference
SD: standard deviation; VAS: visual analog scale; PRI: *Pain Rating Index*. a In case of vaginal delivery.

Discussion a significant decrease in the global assessment of the pain of the pelvic scars and an improvement in the healing of the lesion. The decrease in pelvic scar pain in the PRI-Sensory subscale was significantly greater in the IG patients.

Pain intensity scales are capable of determining changes in the same patient over time, but they have little ability to compare between subjects[29]. The VAS of pain is not very sensitive in the assessment and description of pain, the MPQ being more specific in this case in the evaluation of improvement in pain. The use of more specific scales/questionnaires can help us in the assessment of patients with any type of pain[30] The PP of perineal tear scars, episiotomies and/or caesarean sections is a frequently underdiagnosed and undertreated condition. A greater awareness of health professionals is required so that they ask about and assess the pain

Table 2 Primary and secondary dependent variables at baseline and post-intervention

	Basal, media (DE)		Post-intervention, mean (SD)		Differences between postintervention and baseline [95% CI]a		p*	d of Cohen
	Control n = 8	Intervention n = 7	Control n = 8	Intervention n = 7	Control n = 8	Intervention n = 7		
EVA	7,5 (0,9)	5,7 (1,4)	4,0 (3,1)	2,1 (2,4)	−3,5 [−6,3 a −0,7]	−3,6 [−6,3 a −0,9]	0,966	−0,02
McGill Pain Questionnaire	28,9 (8,0)	31,1 (4,8)	20,5 (15,4)	13,7 (8,9)	−8,4 [−16,3 a −0,4]	−17,4 [−25 a −9,9]	0,071	−1,02
PRI-Sensorial	23,6 (8,3)	26,1 (2,5)	17,6 (13,8)	11,0 (7,7)	−6 [−12,6 a 0,6]	−15,1 [−22,2 a −8,1]	0,040	−1,18
PRI-Emotional	2,5 (1,7)	2,7 (2,1)	1,1 (1,0)	1,1 (1,3)	−1,4 [−2,7 a −0,04]	−1,6 [−3,1 a −0,1]	0,817	−0,12
PRI-Valuation	2,8 (1,2)	2,3 (0,5)	1,8 (0,9)	1,6 (0,5)	−1 [−2,3 a 0,3]	−0,7 [−1,2 a −0,3]	1,000	0,25
Vancouver Scar Scale	5,5 (1,9)	4,6 (1,9)	3,4 (2,9)	1,7 (2,0)	−2,1 [−4 a −0,2]	−2,9 [−4,7 a −1,1]	0,613	−0,34
Patient Scar Assessment Scale	34,8 (9,9)	25,4 (11,2)	23,1 (18,3)	13,1 (16,1)	−11,6 [−25,4 a 2,2]	−12,3 [−26,6 a 2]	0,938	−0,04

Data highlighted in bold correspond to statistically significant differences
SD: standard deviation; VAS: visual analog scale; 95% CI: 95% confidence interval; PRI: *Pain Rating Index*.
a Difference of intragroup means together with their 95% confidence interval.
* p of the contrast of the intergroup mean difference.

Table 3 Impression scales of global improvement of postoperative patient / clinician

	Control n = 8	Intervention n = 7	p
PGI I			
Much Much better	2 (25,0)	2 (28,6)	0,814
Better	2 (25,0)	3 (42,9)	
A bit better	4 (50,0)	2 (28,6)	
CGI-I			
Much better	3 (37,5)	3 (42,9)	1,000
Better	4 (50,0)	4 (57,1)	
No change	1 (12,5)	0 (0,0)	

CGI-I: Clinician's Global Impression of Improvement Scale; PGI-I: impression scale of global improvement of the patient.

caused by these scars in women who have recently given birth, since a delay in diagnosis can cause a chronification of this pain and the consequent central sensitization, dificultivating the treatment and reducing the effectiveness of actions at the local level. This pilot study has shown a greater reduction in pelvic scar pain in temporal-spatial terms (PRI-Sensory subscale) in the IG. A large effect is also observed in the global MPQ score in favour of the IG, although the difference is not statistically significant, possibly due to the lack of statistical power as it is a pilot study with a small sample of patients. This small sample is clearly a limitation of the study, as well as the fact that it was not possible to carry out a blinded study. The fact that the intervention was not masked, and that the patient was aware of the group to which she was assigned could have led to a problem of social desirability in her responses so that they were seen as favourable by the health professional. As a pilot study, it was decided to compare with the Rehabilitation treatment commonly used without carrying out an infiltration with saline solution as a placebo or compared with other infiltrated treatments (glucocorticoids, local anaesthetics), thus being able to be carried out in future lines of research. The results obtained point to a new line of treatment for the approach of these scars and an unknown use of type I collagen. To date, there is no previous evidence of the use of collagen in painful scars, but more studies are required to establish the line of treatment in which the use of collagen can be placed. Double-blind comparative studies with placebo in which physiological saline is infiltrated, and comparative studies with other types of interventions such as infiltrations with substances such as glucocorticoids or local anaesthetics, are required. In addition, specific studies are required to determine the amount of collagen and the number of infiltrations that would be most appropriate for each type of scar, the effect depending on the time of evolution of the scar. Likewise, it is necessary to know the long-term efficacy of collagen infiltrations in the evolution of the appearance of scars in case repetition of these infiltrations is necessary.

Conclusions

Collagen infiltrations could improve PP in painful scars and their appearance in comparison with conventional rehabilitation treatment. Further studies are required to establish its efficacy and cost-effectiveness and its role in the routine treatment of painful scars.

Conflict of interest

The investigators of this study did not receive any type of financial compensation for conducting the study. The Oyasama laboratory provided the MD-Tissue® collagen vials used free of charge.

Bibliography

1. Romero Cullerés C, Tejero Sánchez M, Moreno Atanasio E. Definición. Epidemiología y fisiopatología del dolor pélvico crónico. Dolor. 2017;32:45–54.
2. López González PA, Tornero Ruiz JI, Cubillana PL, Iñiguez GD, Ruiz Morcillo JC, Albacete MP. Alternativa terapéutica para el dolor pélvico crónico de origen vesical. Actas Urol Esp. 2009;33:681–5, http://dx.doi.org/10.1016/s0210-4806(09)74207-x.
3. Reiter RC. A profile of women with chronic pelvic pain. Clin Obstet Gynecol. 1990;33:130–6.
4. Islam A, Hanif A, Ehsan A, Arif S, Niazi SK, Niazi AK. Morbidity from episiotomy. J Pak Med Assoc. 2013;63:696–701.
5. Schinkel N, Colbus L, Monrigal C, Granry JC. ATS14 - Prise en charge des douleurs périnéales postépisiotomies. Douleurs: Évaluation - Diagnostic - Traitement. 2006;7:63–4, http://dx.doi.org/10.1016/s1624-5687(06)77828-3.
6. Åhlund S, Rådestad I, Zwedberg S, Lindgren H. Perineal pain the first year after childbirth and uptake of post-partum check-up - A Swedish cohort study. Midwifery. 2019;78:85–90, http://dx.doi.org/10.1016/j.midw.2019.08.004.
7. Kainu JP, Halmesmäki E, Korttila KT, Sarvela PJ. Persistent pain after cesarean delivery and vaginal delivery: A prospective cohort study. Anesth Analg. 2016;123:1535–45, http://dx.doi.org/10.1213/ANE.0000000000001619.
8. Lavand'Homme P. Postoperative cesarean pain: Real but is it preventable? Curr Opin Anaesthesiol. 2018;31:262–7, http://dx.doi.org/10.1097/ACO.0000000000000585.
9. Vall-Toscas C, Sardá-Barea E, Martínez-Bueno C, Zaragoza-Marfá A. Dolor persistente posparto. Tratamiento con procaína subdérmica (terapia neural). Matronas Prof. 2016;17:143–8.
10. Herranz P, Santos Heredero X. Cicatrices, guía de valoración y tratamiento. Madrid: Meda Pharma; 2012. M-41381-2012.
11. Lucha Fernández V, Muñoz Mañez V, Fornes Pujalte B, García Garcerá M. La cicatrización de las heridas. Enfermería Dermatológica. 2008:8–15, http://dx.doi.org/10.1016/B978-84-9022-065-8/00007-6.
12. Rosenbaum TY, Owens A. The role of pelvic floor physical therapy in the treatment of pelvic and genital pain-related sexual dysfunction. J Sex Med. 2008;5:513–23, http://dx.doi.org/10.1111/j.1743-6109.2007.00761.x.
13. Itza F, Zarza D, Serra L, Gómez-Sancha F, Salinas J, Allona-Almagro A. Síndrome de dolor miofascial del suelo pélvico: una patología urológica muy frecuente. Actas Urol Esp. 2010;4:318–26, http://dx.doi.org/10.1016/j.acuro.2009.12.013.
14. Fernández Medina IM. Abordaje fisioterápico de las lesiones perineales en el posparto. Enfermería Docente. 2013;100:28–33, http://www.juntadeandalucia.es/servicioandaluzdesalud/huvvsites/default/files/revistas/ED-100-08.pdf.
15. Montes Posada I, Gutiérrez González J, Gil Fraguas ML, Romero Culleres G. Tratamiento del dolor pélvico crónico. Papel de las unidades de rehabilitación del suelo pélvico. Dolor. 2017;32:65–74.
16. Milani L. A new and refined injectable treatment for musculoskeletal disorders – bioscaffold properties of collagen and its clinical use and action. Physiol Regul Med. 2010:3–15.
17. Milani L. The collagen medical devices in the local treatment of the algic arthro-rheumopathies – Review of the clinical studies and clinical assessments 2010-2012. Physiol Regul Med. 2013:21–36.
18. Nitecka-Buchta A, Walczynska-Dragon K, Batko-Kapustecka J, Wieckiewicz M. Comparison between collagen and lidocaine intramuscular injections in terms of their efficiency in decreasing myofascial pain within masseter muscles: A randomized, single-blind controlled trial. Pain Res Manag. 2018;2018, http://dx.doi.org/10.1155/2018/8261090, 8261090.
19. Shah JP, Thaker N. Myofascial pain syndrome. En: Cheng J, Rosenquist RW, editores. Fundamental of pain medicine. Cham: Springer International Publishing; 2018. p. 177–84, http://dx.doi.org/10.1007/978-3-319-64922-1_19.
20. Martin Martin LS, Massafra U, Bizzi E, Migliore A. A double blind randomized active-controlled clinical trial on the intra-articular use of Md-Knee versus sodium hyaluronate in patients with knee osteoarthritis (''Joint''). BMC Musculoskelet Disord. 2016;17:94948, http://dx.doi.org/10.1186/s12891-016-0948-4.
21. Schulz KF, Altman DC, Moher D. CONSORT 2010 statement: Updated guidelines for reporting parallel group randomised trials. Ann Intern Med. 2010;152:726–32, http://dx.doi.org/10.7326/0003-4819-152-11-201006010-00232.
22. Huskisson EC. Measurement of pain. Lancet. 1974;9;2(7889):1127–31. https://doi.org/10.1016/s0140-6736(74)90884-8.
23. Ruiz-Lopez R, Ferrer I, Pagerols M. The Spanish pain questionnaire. Pain. 1990;41 Suppl 1:S304, http://dx.doi.org/10.1016/0304-3959(90)92723-4.
24. Lázaro C, Bosch F, Torrubia R, Baños JE. The development of a Spanish questionnaire for assessing pain: Preliminary data concerning reliability and validity. Eur J Psychol Assess. 1994;10:145–51.
25. Chae JK, Kim JH, Kim EJ, Park K. Values of a patient and observer scar assessment scale to evaluate the facial skin graft scar. Ann Dermatol. 2016;28:615–23, http://dx.doi.org/10.5021/ad.2016.28.5.615.
26. Draaijers LJ, Tempelman FRH, Botman YAM, Tuinebreijer WE, Middelkoop E, Kreis RW, et al. The patient and observer scar assessment scale: A reliable and feasible tool for scar evaluation. Plast Reconstr Surg. 2004;113:1960–5, http://dx.doi.org/10.1097/01.PRS.0000122207.28773.56.
27. Guy W, ed. ECDEU Assessment manual for psychopharmacology. Rockville, MD: US Department of Heath, Education, and Welfare Public Health Service Alcohol, Drug Abuse, and Mental Health Administration; 1976.
28. Romero Maroto J, Ortiz Gorraiz M, Prieto Chaparro L, Pacheco Bru JJ, Miralles Bueno JJ, Lopez Lopez C. Transvaginal adjustable tape: An adjustable mesh for surgical treatment of female stress urinary incontinence. Int Urogynecol J Pelvic Floor Dysfunct. 2008;19:1109–16, http://dx.doi.org/10.1007/s00192-008-0590-2.
29. Dunn DK, Jannetta PJ. Evaluation of chronic pain in children. Curr Probl Surg. 1973:64–72.
30. Serrano-Atero MS, Caballero J, Cañas A, García-Saura PL, Serrano-Álvarez C, Prieto J. Valoración del dolor (II). Rev Soc Esp Dolor. 2002;9:109–21.

MD-MATRIX

Porcine collagen-based medical device for the treatment of localised adiposity and firming of the subcutaneous connective tissue layer

PLAY SURE
doping free

SCAN ME

CE-marked Medical Device (Class III). Read the instructions and warnings before use.

COMPOSITION
Porcine-derived collagen, citric acid, nicotinamide, sodium chloride, water for injections.

PACKAGE
Packs of 5 and 10 vials (2 ml each - extractable volume).

INJECTION ROUTES OF ADMINISTRATION
For intradermal and subcutaneous administration: insert the needle to a depth of 4–13 mm, perform 6–10 microinjections of 0.2–0.5 ml per point up to a volume of 10 ml in the area to be treated (face, neck, décolleté, arms, buttocks, abdomen, knees, thighs).

RECOMMENDED NEEDLES
- *Microinjection/wheal technique:* 27–32G x 2–13 mm needle.
- *Tunnelling/fanning technique:* 25–27G x 13–38 mm needle.

Note: Thoroughly disinfect the skin with povidone-iodine, chlorhexidine, benzalkonium chloride.

AREAS OF APPLICATION
MD-MATRIX is intended to firm the subcutaneous and microvascular connective tissue layer in localised adiposity and in connective tissue fibroedematous gynoid excesses, particularly those located at the root of the thighs and the inner knee area.

Scientific evidence shows the efficacy and safety of MD-MATRIX:
• in the treatment of localised adiposity of the knees and abdomen.
Treatment may be combined with other therapies.

THERAPEUTIC PROTOCOL:
1 injection every 15 days to firm the subcutaneous and microvascular connective tissue layer in localised adiposity and in connective tissue fibroedematous gynoid excesses, particularly those located at the root of the thighs and the inner knee area.

Visible results from the third injection; however, depending on the patient's aesthetic treatment plan, treatment may be continued up to the tenth week without risks.

REFERENCES

- *Randelli F. et al Effect of a Collagen-Based Compound on Morpho-Functional Properties of Cultured Human Tenocytes. Cells. 2018 Dec 6;7(12):246*
- *Randelli F. et al The Collagen-Based Medical Device MD-Tissue Acts as a Mechanical Scaffold Influencing Morpho-Functional Properties of Cultured Human Tenocytes, Cells 2020;9:2641*
- *Elenkova S., Pozharashka J. Acumesotherapy with injectable collagen in patients with localised adiposity of the knees: an observational study. European Journal of Integrative Medicine 4S (2012) 124–201*
- *Elenkova S., Pozharashka J. Acumesotherapy with Guna MD-MATRIX in patients with localized abdominal adiposity. Physiological Regulating Medicine, 2012; 43.*

For access to the articles: collagenmd.guna.com, beauthentic.guna.it

THE INFORMATION CONTAINED IN THIS DATA SHEET IS INTENDED EXCLUSIVELY FOR PROFESSIONALS

Medical Device CE 0373

GUNA medical device

Guna S.p.a. • Milano

beauthentic.guna.it

LIFEGATE

Guna S.p.a. calculates and offsets the carbon footprint of the Via Palmanova plant in Milan and of the website by financing certified projects to safeguard the climate and the environment in developing countries and in Italy.

GUNA S.p.a. is a company with quality management standard system **ISO 13485** certified by Bureau Veritas Italia SpA

7EX154 A

MD-TISSUE

Porcine collagen-based medical device for the treatment of wrinkles, scars, post-acne blemishes, skin laxity and loss of tone

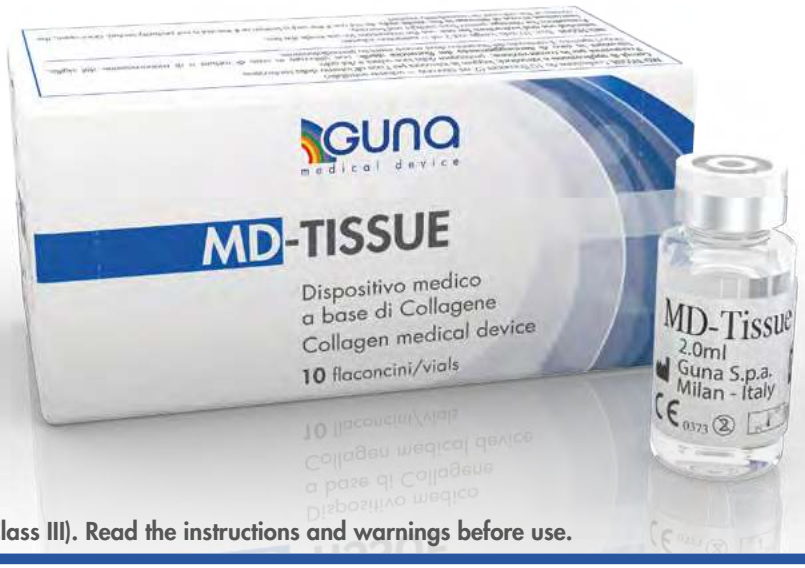

PLAY SURE
doping free

SCAN ME

CE-marked Medical Device (Class III). Read the instructions and warnings before use.

COMPOSITION
Porcine-derived collagen, ascorbic acid, magnesium gluconate, pyridoxine hydrochloride, riboflavin, thiamine hydrochloride, sodium chloride, water for injections.

PACKAGE
Packs of 5 and 10 vials (2 ml each - extractable volume).

INJECTION ROUTES OF ADMINISTRATION
Intradermal/subdermal: the application area must be aseptic:
- *Microinjection/wheal technique:* insert the needle to a depth of 2–6 mm, perform 6–10 microinjections of 0.2–0.5 ml up to 10 ml in the area to be treated (face, neck, décolleté, hands, breast, abdomen).
- *Tunnelling/fanning technique:* 2–10 ml to be infiltrated using an anterograde or retrograde technique. Insert the needle almost tangentially along the full length of the area, then inject while simultaneously withdrawing the needle or cannula as the product is delivered.

RECOMMENDED NEEDLES
- *Microinjection/wheal technique:* 27–32G x 2–13 mm needle.
- *Tunnelling/fanning technique:* 25–27G x 13–38 mm needle.

Note: Thoroughly disinfect the skin with povidone-iodine, chlorhexidine, benzalkonium chloride.

AREAS OF APPLICATION
MD-TISSUE is intended to limit the physiological deterioration of the skin and subcutaneous connective tissue and to counteract the effects due to chrono-ageing and photo-ageing, such as:
- topical anti-ageing treatment
- facial and neck wrinkles
- firming of the subcutaneous and perivascular connective tissue layer of the face and neck
- impaired trophism of the connective tissue of the face and neck due to exogenous pollutants/dysmetabolism

Scientific evidence shows the efficacy and safety of MD-TISSUE:
- in the treatment of scars and wounds.

Treatment may be combined with other therapies.

THERAPEUTIC PROTOCOL:
1 injection every 15 days to limit the physiological deterioration of the skin and subcutaneous connective tissue and to counteract the effects of chrono-ageing and photo-ageing.

Visible results from the third injection; however, depending on the patient's aesthetic treatment plan, treatment may be continued up to the tenth week without risks.

REFERENCES

- *Randelli F. et al Effect of a Collagen-Based Compound on Morpho-Functional Properties of Cultured Human Tenocytes. Cells. 2018 Dec 6;7(12):246*
- *Randelli F. et al The Collagen-Based Medical Device MD-Tissue Acts as a Mechanical Scaffold Influencing Morpho-Functional Properties of Cultured Human Tenocytes, Cells 2020;9:2641*
- *Romero-Cullerés G. et al Eficacia de las infiltraciones con colágeno en el dolor pélvico causado por cicatrices de episiotomía y cesáreas. Ensayo clínico piloto aleatorizado [Efficacy of collagen infiltrations in the pelvic pain caused by episiotomy and caesarean scars. Pilot randomized clinical trial]. Rehabilitacion (Madr). 2022 Apr-Jun;56(2):85-92. Spanish. doi: 10.1016/j.rh.2021.04.001. Epub 2021 Sep 4. PMID: 34489100.*

For access to the articles: collagenmd.guna.com, beauthentic.guna.it

THE INFORMATION CONTAINED IN THIS DATA SHEET IS INTENDED EXCLUSIVELY FOR PROFESSIONALS

Medical Device CE 0373

GUNA medical device

Guna S.p.a. • Milano

beauthentic.guna.it

LIFEGATE

Guna S.p.a. calculates and offsets the carbon footprint of the Via Palmanova plant in Milan and of the website by financing certified projects to safeguard the climate and the environment in developing countries and in Italy.

GUNA S.p.a. is a company with quality management standard system **ISO 13485** certified by Bureau Veritas Italia SpA

7EX155 A

Healthspan versus Lifespan
Il ruolo della Medicina Estetica

SIME 2025 | 46° CONGRESSO SIME Società Italiana di Medicina Estetica | 20° CONGRESSO AIMAA Accademia Italiana di Medicina Anti-Aging

16, 17, 18 MAGGIO
Roma Convention Center La Nuvola

COLLAGENE SUINO DI TIPO I AD USO INIETTIVO SOTTOCUTANEO NEL TRATTAMENTO DI CICATRICE CHIRURGICA MAMMARIA COMPLICATA

Dott.ssa Liliana Sgarbi, *Direttore UOC Riabilitazione Specialistica Presidio Fatebenefratelli Milano*

Ospedale Fatebenefratelli e Oftalmico
Sistema Socio Sanitario Regione Lombardia
ASST Fatebenefratelli Sacco

INTRODUZIONE:

Nelle ferite chirurgiche che guariscono per seconda intenzione, la risposta infiammatoria e la produzione di tessuto di granulazione sono più rilevanti rispetto alla guarigione per prima intenzione. La produzione di tessuto connettivo risulta più cospicua ma le fibre collageniche presentano scarso allineamento.
Una organizzazione disordinata del tessuto cicatriziale può essere causa di danni estetici e/o funzionali.
L'utilizzo di dispositivi medici a base di collagene di tipo I nel trattamento di cicatrici permette di fornire substrato, alla matrice extracellulare, di migliorare la capacità contrattile e quindi produttiva deifibroblasti e ottimizzare l'assetto delle fibre collagene prodotte.

CASO CLINICO:

Paziente di anni 44, affetta da carcinoma mammario. Sottoposta a quadrantectomia mammaria con dissezione ascellare. Intervento complicato da ascesso mammario sottocicatriziale, drenato con successiva guarigione per seconda intenzione.

ESAME OBIETTIVO:

Cicatrice chirurgica arrossata, discromica; adesa ai piani sottostanti; depressa nella porzione centrale con cordoncino ipertrofico longitudinale (punteggio 9 scala Vancuver).

MATERIALI E METODI:

Trattamento mesoterapico iniettivo sottocute con collagene MD-TISSUE GUNA eseguito ogni 7 giorni per complessivamente 5 sedute.
Follow up a 3 e 10 giorni dal termine del trattamento.
Somministrata la scala Vancuver prima del trattamento e nei follow up.

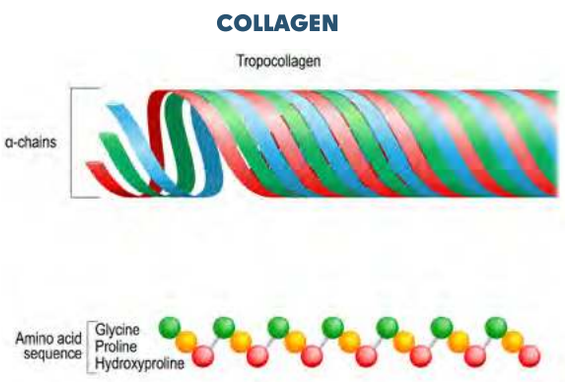

RISULTATI:

Esame obiettivo nei follow up: maggiore omogeneità della pigmentazione e una schiaritura della colorazione. Risoluzione dell'aderenza ai piani sottostanti nella porzione centrale della cicatrice (punteggio 4 scala Vancuver).

CONCLUSIONI:

L'utilizzo di questo dispositivo medico è una opzione terapeutica innovativa, scarsamente invasiva e con favorevole rapporto costo-beneficio. Tuttavia, servono ulteriori evidenze scientifiche a supporto.

REFERENZE:

1. Randelli F, Menon A, Giai Via A, et al, Effect of a Collagen-Based Compound on Morpho-Functional Properties of Cultured Human Tenocytes. Cells. 2018 Dec 6;7(12):246.
2. Randelli F, Sartori P, Carlomagno C, Bedoni M, Menon A, Vezzoli E, et al. The Collagen-Based Medical Device MD-Tissue Acts as a Mechanical Scaffold Influencing Morpho-Functional Properties of Cultured Human Tenocytes. Cells. 2020 Dec 8;9(12):264
3. Cotran RS, Kumar V, Collins T (2000) Robbins. Le basi patologiche delle malattie. Piccin editore
4. Lin-Hui L, Yuan-Yuan Z, Ming-Yu L, Xu-Dong H, Yin-Jia D, Yue Z, Yang-Hong-Hong F, Ai-Fen C, Xu-Dong Z, Zheng-Li C, Jian J. Recombinant Human Collagen Type III Improves Hypertrophic Scarring by Regulating the Ratio of Type I/III Collagen. J Burn Care Res. 2024 Sep 6;45(5):1269-1273
5. Gardeazabal L, Izeta A. Elastin and collagen fibres in cutaneous wound healing. Exp Dermatol. 2024 Mar;33(3):e15052.

TRATTAMENTO CON COLLAGENE INFILTRATIVO SUINO IN ESITI CICATRIZIALI POST ACNE ADOLESCENZIALE

D.ssa Arianna Squillante, *Centro Medico Eden Siracusa*

OBIETTIVI:

L'acne è una dermatosi cronica prevalente durante l'adolescenza con una buona percentuale significativa di casi che evolvono in cicatrici permanenti. Le cicatrici atrofiche derivano da una inadeguata produzione di collagene durante i processi di guarigione e rispondono bene a trattamenti di tipo rigenerativo come collagene, microneedling, PRP, Laser.
Le cicatrici post-acne nei giovani hanno un impatto significativo sull'autostima e qualità della vita.
Il collagene permette di ottenere un effetto di rimodellamento del tessuto fibrotico, andando a stimolare i fibroblasti e una neocollagenesi (collagene di tipo I va a sostituire il collagene di tipo III che conduce ad esiti cicatriziali).
In questo case series si è voluto valutare l'efficacia e la tollerabilità del collagene infiltrativo suino nel miglioramento degli esiti cicatriziali post-acne in soggetti adolescenti.
L'utilizzo del dispositivo medico MD-TISSUE a base di collagene suino rappresenta una opzione terapeutica innovativa ed efficace nel trattare queste cicatrici che possono lasciare aree profonde e depresse se non adeguatamente gestite.

MATERIALI E METODI:

5 pazienti (2 di 15 aa, 1 di 16 aa 2 di 17 aa) presentatavano cicatrici post-acne e sono stati sottoposti a ciclo infiltrativo in corrispondenza delle lesioni cicatriziali con tecnica mesoterapica a ventaglio sotto la cicatrice e puntiforme al centro della cicatrice.
E' stato eseguito un ciclo da 5 infiltrazioni, 1 a settimana per 5 settimane, utilizzando ago 13 mm e 30 G, 2 vials, (4 ml) di collagene suino.
E' stata effettuata valutazione clinica e fotografica includendo anche una scala di soddisfazione.
Si è associata terapia orale con Dermoguna compresse ed una terapia topica con Dermoguna siero per conferire maggiore levigatezza ed elasticità ai tessuti, oltre che prolungarne l'effetto.

RISULTATI:

I pazienti hanno mostrato un miglioramento significativo, documentato da immagini pre e post trattamento, sia nella profondità che nell'aspetto delle cicatrici. Si è ottenuto un buon risultato sulla distensione della cicatrice, grazie all'azione riparativa e biorigenerativa del collagene nel rispetto e uniformità della texture cutanea.
La valutazione dell'efficacia è stata effettuata mediante scale che misurano il grado di soddisfazione e miglioramento estetico dei pazienti (scala da 0 a 10; risultato 9) e anche da parte del medico e dei genitori si è apprezzato tale risultato.
Non si è riscontrata alcuna reazione allergica o fastidio durante e post trattamento.

PRE TRATTAMENTO

POST TRATTAMENTO

CONCLUSIONI:

L'infiltrazione del dispositivo medico classe III, a base di collagene suino ed eccipienti a base di vitamine C, B1, B2, B6 e gluconato di magnesio ad azione anti ossidante, rappresenta una terapia efficace e sicura per il trattamento delle cicatrici post-acne in adolescenti.
Questo dispositivo si è rivelato essere un'opzione terapeutica bioristrutturante e biorivivitalizzaante capace di stimolare il rimodellamento dermico grazie alla neocollagenesi e al supporto strutturale.

BIBLIOGRAFIA:

1. Randelli F, Sartori P, Carlomagno C, Bedoni M, Menon A, Vezzoli E, et al. The Collagen-Based Medical Device MD-Tissue Acts as a Mechanical Scaffold Influencing Morpho-Functional Properties of Cultured Human Tenocytes. Cells. 2020 Dec 8;9(12):2641.
2. Randelli F, Menon A, Giai Via A, et al, Effect of a Collagen-Based Compound on Morpho-Functional Properties of Cultured Human Tenocytes. Cells. 2018 Dec 6;7(12):246.
3. Vasam M, Korutla S, Bohara RA. Acne vulgaris: A review of the pathophysiology, treatment, and recent nanotechnology based advances. Biochem Biophys Rep. 2023 Nov 23;36:101578.

TRATTAMENTO DELLE OCCHIAIE CON COLLAGENE INFILTRATIVO SUINO: APPROCCIO RIGENERATIVO PER UNA ZONA PERIORBITALE PIÙ GIOVANE E LUMINOSA

D.ssa Arianna Squillante, *Centro Medico Eden Siracusa*

OBIETTIVI:

Le occhiaie (iperpigmentazione infraorbitale o dark circles) rappresentano un inestetismo comune della regione periorbitale inferiore, presente sia in soggetti giovani che adulti. Clinicamente si distinguono diverse tipologie di occhiaie: pigmentate, vascolari, strutturali e miste con eziopatogenesi multifattoriale. Il trattamento delle occhiaie è complesso e richiede approcci personalizzati e multifunzionali.
In questo case series abbiamo valutato un protocollo rigenerativo non invasivo (con dispositivo medico a base di collagene suino ed eccipienti come acido citrico e nicotinamide) infiltrato su una serie di pazienti con tecnica a ventaglio.
Il collagene grazie al suo effetto rigenerativo e biostimolante, sulla zona periorbitale, promuove dei buoni risultati per una pelle più luminosa ed elastica.

MATERIALI E METODI:

10 pazienti (4 paz di 40 aa, 2 di 35 aa, 3 paz di 25 aa, 1 paz di 60 aa) , sono stati sottoposti ad un ciclo di 5 infiltrazioni con 2 vials (4 ml) di collagene suino + acido citrico e nicotinamide, mediante tecnica sia ventaglio che a caduta (seguendo il profilo del canto osseo), a cadenza settimanale, utilizzando ago 13 mm e 30 gauche.
Si associa terapia topica con Dermoguna siero e Arnica durante e dopo il trattamento.
La valutazione dei risultati era stata fatta mediante immagine fotografica prima e dopo il trattamento; scala soggettiva di soddisfazione del paziente e del medico prima e dopo trattamento.

PRE TRATTAMENTO

POST TRATTAMENTO

POST TRATTAMENTO

RISULTATI:

Il trattamento delle occhiaie, mediante questa metodica infiltrativa e grazie alle proprietà del collagene come biostimolante, ha permesso di avere un miglioramento tissutale a fine trattamento.
Questo soprattutto nei casi di occhiaie strutturali associate a svuotamento del solco lacrimale, con un effetto coprente sulle occhiaie pigmentate e alta tollerabilità da parte dei pazienti.
Lievi arrossamenti o gonfiori post-trattamento sono stati solo transitori.

CONCLUSIONI:

L'utilizzo infiltrativo del dispositivo medico in classe III a base di collagene suino ed eccipienti come acido citrico e nicotinamide rappresenta un'opzione terapeutica promettente e sicura nel trattamento di occhiaie dovute a perdita di volume e la terapia topica associata con siero è stata utile a supportare anche le forme pigmentarie.

BIBLIOGRAFIA:

1. Randelli F, Menon A, Giai Via A, et al, Effect of a Collagen-Based Compound on Morpho-Functional Properties of Cultured Human Tenocytes. Cells. 2018 Dec 6;7(12):246.
2. Zhao R, Qiu H, Liu S, Cao L, Yu D, Wang H. Quantifiable clinical efficacy of injectable porcine collagen for the treatment of structural dark circles. J Cosmet Dermatol. 2021 May;20(5):1520-1528.
3. Michelle, Lauren BA*,†; Pouldar Foulad, Delila MD*; Ekelem, Chloe MD*; Saedi, Nazanin MD‡; Mesinkovska, Natasha Atanaskova MD, PhD*. Treatments of Periorbital Hyperpigmentation: A Systematic Review. Dermatologic Surgery 47(1):p 70-74, January 2021.

BIOSTIMOLAZIONE E BIORISTRUTTURAZIONE DERMICA CON COLLAGENE PORCINO NELL'INVECCHIAMENTO CUTANEO

Dott. Andrea Turchi, *Medico Estetico*

DOTT. ANDREA TURCHI
MEDICINA ESTETICA FUNZIONALE

OBIETTIVI:

L'invecchiamento cutaneo è un fenomeno biologico involutivo complesso che interessa la cute e principalmente la Matrice Extra Cellulare (ECM).
L'ECM è una rete dinamica tridimensionale di macromolecole che fornisce supporto strutturale alle cellule e ai tessuti. Le evidenze scientifiche dell'ultimo decennio hanno chiaramente dimostrato che l'ECM svolge ruoli regolatori importanti poiché permette la comunicazione tra cellule, le loro funzioni, proprietà e morfologia.
L'invecchiamento cutaneo crono e foto indotto ha inizio con una riduzione e naturale degradazione del collagene a partire dai 35 anni in su. Il collagene perde il suo allineamento e non supporta più l'adesione dei fibroblasti, che si trasformano in cellule senescenti. Motivo per cui un approccio infiltrativo a base di collagene suino può rivelarsi una terapia efficace.
Al fine di valutare l'effetto della biostimolazione del collagene porcino nei pazienti over 35 anni arrivati alla mia attenzione, sono stati selezionate 10 pz di età tra i 35 e i 55 aa.

MATERIALI E METODI:

10 pazienti sono state sottoposte ad infiltrazione di collagene suino 2 ml (MD-TISSUE), a livello intradermico, nel viso, collo e nella zona perioculare inferiore, per complessivi 4 trattamenti a cadenza bisettimanale. Il 70% delle pazienti ha avuto un netto miglioramento funzionale dell'area trattata.

Il grado di soddisfazione delle pazienti è stato valutato da scale di miglioramento estetico e immagine fotografica prima e dopo trattamento.

RISULTATI:

La bioristrutturazione dermica attraverso l'uso del collagene MD-TISSUE ha migliorato l'aspetto esteriore della pelle e la plasticità della matrice extracellulare.

Nei pazienti con presenza di rughe si è avuto un miglioramento dell'aspetto della ruga con visibile distensione del tessuto che ne ha migliorato tono ed elasticità.

PRE TRATTAMENTO | POST TRATTAMENTO

CONCLUSIONI:

L'uso del dispositivo medico a base di collagene suino permette di raggiungere aspetti naturali andando ad agire sulla biostimolazione, neosintesi di nuovo collagene, miglioramento del tono ed elasticità dei tessuti, che dai 30 anni in avanti perdono lucentezza, tono e volume soprattutto in aree del viso collo.

BIBLIOGRAFIA:

1. Salvatore L, Natali ML, Brunetti C, Sannino A, Gallo N. An Update on the Clinical Efficacy and Safety of Collagen Injectables for Aesthetic and Regenerative MedicineApplications. Polymers. 2023; 15(4):1020.

2. Randelli F, Menon A, Giai Via A, et al, Effect of a Collagen-Based Compound on Morpho-Functional Properties of Cultured Human Tenocytes. Cells. 2018 Dec 6;7(12):246.

EFFICACIA DELLA BIOSTIMOLAZIONE CON COLLAGENE INIETTIVO SUINO NEL TRATTAMENTO DELLE OCCHIAIE PERIOCULARI

Dott. Andrea Turchi, *Medico Estetico*

OBIETTIVI:

Le occhiaie possono avere cause genetiche, vascolari o esser determinate da stress ossidativo o foto esposizione. Sono caratterizzate da un'area scura, infossata e, talvolta, gonfia sotto gli occhi.
Le occhiaie sono classificate in pigmentarie (di colore marrone, date da accumulo di melanina), vascolari (di colore blu-violaceo date da visibilità dei vasi sanguigni sottocutanei) o strutturali (da svuotamento, appare ombreggiata, con perdita di volume del grasso periorbitale) e miste (pigmentazione, componente vascolare, svuotamento).
La richiesta di trattamenti sicuri, efficaci, minimamente invasivi ha consentito un trattamento a base di sostanze naturali, biorivitalizzanti e bioristrutturanti, come il dispositivo medico iniettivo di classe III a base di collagene suino che abbiamo utilizzato sulle nostre pazienti sia giovani che meno giovani.
La sintesi di nuovo collagene indotta dall'utilizzo del collagene esogeno restituisce tono ed elasticità ai tessuti, agendo anche nelle aree ipercromiche con cute assotigliata e spesso iperpigmentata.
L'utilizzo di un trattamento con collagene infiltrativo per via sottocutanea nella regione perioculare migliora la texture e l'aspetto estetico.

MATERIALI E METODI:

Sono state trattate 6 pz donne di età dai 30 ai 50 anni mediante iniezioni intradermiche che presentavano occhiaie connesse a stasi vascolare e in due casi dipendenti anche da ipermelanizzazione.
E' stato effettuato un ciclo di 5 infiltrazioni a cadenza settimanale utilizzando collagene suino.
Le prime 2 infiltrazioni sono state effettuate con MD- MATRIX (contenente acido citrico e nicotinamide) 1 vials 2ml per preparare la matrice. Le successive 3 infiltrazioni sono state effettuate con MD-TISSUE (contenente vitamine C, B1, B2,B6) 1 vials da 2 ml per agire sulla cute spesso iperpigmentata.
Il dispositivo MD- MATRIX è a base di collagene suino ed eccipienti come acido citrico (esfoliante con funzione di rinnovamento cellulare che va a contrastare le imperfezioni della pelle) e nicotinamide (antiossidante che influisce positivamente sull'afflusso di sangue al derma e sul microcircolo, migliora l'aspetto della pelle schiarendo e contrastando le macchie cutanee).
Il dispositivo MD-TISSUE è a base di collagene suino ed eccipienti come vit C (per la biosintesi di aminoacidi e collagene) gluconato di magnesio (acceleratore del metabolismo proteico), vit B1 (attivatore delle funzioni metaboliche delle cellule), vit B2(protettore del tessuto cellulare da danno ossidativo), vit B6 (per il bilancio energetico e per il metabolismo degli aminoacidi).

Il protocollo combinato dei 2 tipi di dispositivi permette di sfruttare l'azione del MD-MATRIX nel preparare la matrice extracellulare (ECM) ottimizzandone la sua struttura e successivamente con MD-TISSUE per intervenire sui tessuti, potenziandone la risposta rigenerativa e biostimolante.

La scala di miglioramento estetico ha visto un' evoluzione notevole con una soddisfazione della paziente in una scala da 0 a 10, pari a 8 e una soddisfazione dell'operatore medico pari a 10.

RISULTATI:

Nelle 6 pazienti si è ottenuto un risultato efficace nell'aspetto per evidente aumento di spessore dermico epidermico con minore evidenza dell'area venosa superficiale e riduzione dell'area ipercromica.

CONCLUSIONI:

Il dispositivo medico infiltrativo a base di collagene porcino rappresenta una promettente terapia per la biostimolazione perioculare in presenza di occhiaie. La sua azione su tono, compattezza e luminosità cutanea permettono di utilizzarlo da solo o anche in associazione ad altre terapie come peeling, filler, carbossiterapia, laser nelle zone in cui la quantità di collagene inizia la sua naturale degradazione.

BIBLIOGRAFIA:

1. Cheong S, Yang H, Hao C, Lu F, He Y. Correction of Infraorbital Dark Circles Using Autologous Adipose-Derived Collagen Filler: A Novel Regenerative Option. Aesthetic Plast Surg. 2024 Nov;48(22):4693-4701.

2. Chuang AD, Lin ET, Wu BQ, Lu ME, Chiang HM, Chu PN, Lin BS, Chang CC. Quantitative Assessment of New Frontiers in Dermatochalasis and Periorbital Hyperpigmentation Treatment: The Role of Cross-Linked Porcine Collagen. Aesthetic Plast Surg. 2025 Apr;49(8):2191-2201.

3. Randelli F, Menon A, Giai Via A, et al, Effect of a Collagen-Based Compound on Morpho-Functional Properties of Cultured Human Tenocytes. Cells. 2018 Dec 6;7(12):246.

TRATTAMENTO RIGENERATIVO CON COLLAGENE SUINO INIETTIVO PER IL RILASSAMENTO CUTANEO

Dott.ssa Michela Zazzaron, *Medico Estetico - Treviso*

OBIETTIVI:

La lassità cutanea di viso e corpo (braccia, ginocchia) è una condizione frequente, spesso correlata a chronoaging, photoaging, dimagrimenti importanti e variazioni ormonali. In tali aree la perdita di tono, volume, compattezza ed elasticità porta a questa condizione di invecchiamento cellulare della pelle. Il trattamento con dispositivo medico di classe III a base di collagene suino è stato proposto alle pazienti giunte alla mia attenzione come terapia biostimolante e rigenerativa utile a migliorare la qualità tissutale, considerando la naturale degradazione di collagene a partire dai 30/35 anni.

MATERIALI E METODI:

Sono state trattate 10 pazienti con lassità cutanea nella regione brachiale, ginocchia, collo, addome. Sono state trattate con un ciclo di 5 infiltrazioni a cadenza settimanale con totale di 6 ml per ciascuna infiltrazione:

- 4 ml MD-MATRIX (contenente collagene, acido citrico, nicotinamide) per creare una barriera di difesa contro i radicali liberi, contrastare il fisiologico invecchiamento del tessuto connettivo e agevolare il rassodamento del layer sottocutaneo.
- 2 ml MD-TISSUE (contenente collagene e vit C, B1, B2, B6 e gluconato di magnesio) con azione antiossidante e metabolica sulle cellule. Sono state valutate scala di valutazione della tonicità e analisi fotografica comparativa pre e post trattamento.

PRE TRATTAMENTO

POST TRATTAMENTO

RISULTATI:

Si sono ottenuti risultati soddisfacenti in termini di recupero della tonicità, miglioramento della struttura istologica della pelle, con un effetto volumizzante e di compattezza dermica. Questo risultato è stato determinato dall'azione rigenerativa del collagene e dalla sua capacità di adesione e migrazione cellulare. Il collagene nelle aree indicate contrasta il fisiologico invecchiamento cutaneo.

CONCLUSIONI:

Il trattamento con collagene suino infiltrativo si è dimostrato ben tollerato, costo-efficace rispetto ad altre terapie. È stato verificato un miglioramento clinico significativo e percepibile sia dal paziente che dal medico in termini di riparazione e rigenerazione dei tessuti.

BIBLIOGRAFIA:

1. Ni H, Liu C, Kong L, Zhai L, Chen J, Liu Q, Chen Z, Wu M, Chen J, Guo Y, Bai W, Zhang D, Xia K, Huang G, Pan S, Liao B, Ma K, Zhang LK, Cheng J, Guan YQ. Preparation of injectable porcine skin-derived collagen and its application in delaying skin aging by promoting the adhesion and chemotaxis of skin fibroblasts. Int J Biol Macromol. 2023 Dec 31;253(Pt 2):126718
2. Salvatore L, Natali ML, Brunetti C, Sannino A, Gallo N. An Update on the Clinical Efficacy and Safety of Collagen Injectables for Aesthetic and Regenerative MedicineApplications. Polymers. 2023; 15(4):1020.
3. Randelli F, Menon A, Giai Via A, et al, Effect of a Collagen-Based Compound on Morpho-Functional Properties of Cultured Human Tenocytes. Cells. 2018 Dec 6;7(12):246.

TRATTAMENTO NON INVASIVO DELLA ZONA PERIOCULARE CON COLLAGENE SUINO: DALLE RUGHE AL "SORRISO NELLO SGUARDO"

D.ssa Sonia Ciampa, *Medico Estetico Poliambulatorio Rimedical Rimini*

OBIETTIVI:

La regione perioculare è una zona del viso soggetta a invecchiamento, perdità di elasticità, microrugosità e alterazioni cromatiche.
Il trattamento della regione perioculare (come dark circles, borse edematose, discromie da deposito di melanina) è un aspetto chiave dell'estetica del volto, frequentemente soggetta a inestetismi sia in età giovanile, sia in età adulta.
L'obiettivo di questo lavoro è valutare l'efficacia del trattamento non invasivo della zona perioculare, soggetta a precoce invecchiamento, dove compaiono lassità, rugosità e perdita di tono.
L'approccio non invasivo con collagene suino può rappresentare una nuova soluzione efficace per la biostimolazione dermica, migliorando tono, idratazione e luminosità cutanea.

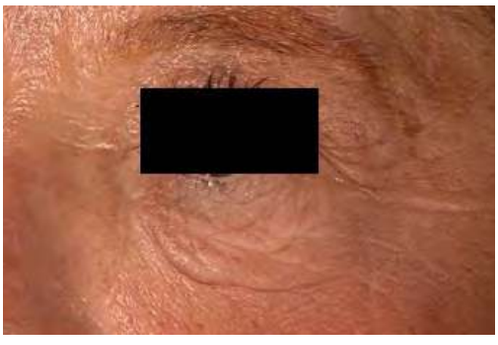

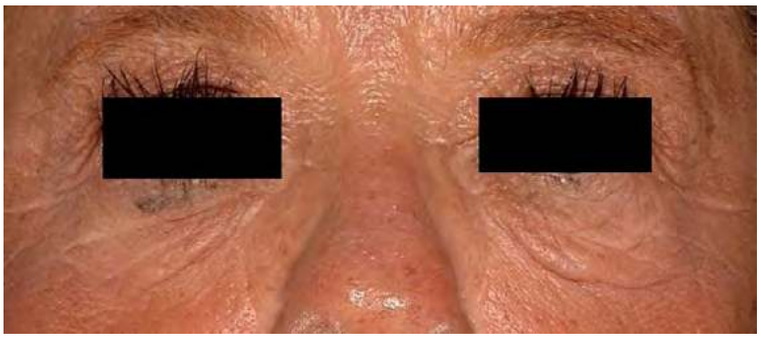

MATERIALI E METODI:

È stata utilizzata una metodica non invasiva mediante magnetoforesi di risonanza per il trattamento della zona periorbitale andando a veicolare transdermicamente il dispositivo medico di classe III a base di collagene suino, acido citrico e nicotinamide.
La magnetoterapia di risonanza è una metodica che permette la somministrazione dei principi attivi per via transcutanea in modo indolore attraverso l'utilizzo di campi magnetici a bassa intensità. Attraverso la magnetoterapia le informazioni chimico-elettriche dei dispositivi medici vengono veicolate ai tessuti trattati in maniera specifica e selettiva.
I 10 pazienti inseriti nello studio hanno inoltre assunto dermacollagene neorland ricco in esosomi, equiseto, vitamina C, E, B2 e niacina per os e applicato localmente un siero a base dello stesso collagene, vitamina C, vitamina E e acqua di fiori di Rosa Centifolia.
I pazienti sono stati trattati a cadenza settimanale per 5 sedute.
Dopo adeguata detersione cutanea il medical device oggetto dello studio (utilizzabile sia per via iniettabile che per via transdermica) è stato miscelato con un gel specifico ed applicato con spatola sulla cute del contorno occhi per veicolazione transdermica tramite magnetoforesi di risonanza.

RISULTATI:

Al termine del ciclo di trattamento è stata osservata una cute più tonica nella zona trattata, una rugosità statica ridotta e una significativa riduzione dei dark circles.
L'assenza totale di effetti collaterali ha reso il trattamento ben tollerato e facilmente eseguibile anche in periodo estivo.

CONCLUSIONI:

La veicolazione trandermica del dispositivo medico a base di collagene suino, acido citrico e nicotinamide mediante magnetoforesi si è dimostrata efficace nel migliorare la qualità cutanea della zona periorbitale, offrendo una soluzione sicura, efficace e ben tollerata dai pazienti.

BIBLIOGRAFIA:

1. Randelli F, Menon A, Giai Via A, et al, Effect of a Collagen-Based Compound on Morpho-Functional Properties of Cultured Human Tenocytes. Cells. 2018 Dec 6;7(12):246.

2. Randelli F, Sartori P, Carlomagno C, Bedoni M, Menon A, Vezzoli E, et al. The Collagen-Based Medical Device MD-Tissue Acts as a Mechanical Scaffold Influencing Morpho-Functional Properties of Cultured Human Tenocytes. Cells. 2020 Dec 8;9(12):2641.

S. Elenkova, J. Pozharashka

ACUMESOTHERAPY WITH GUNA MD-MATRIX IN PATIENTS WITH LOCALIZED ABDOMINAL ADIPOSITY

INTRODUCTION

The Localized Adiposity is not only an aesthetic problem, but a complex pathology – an external expression of numerous metabolic alterations in the tissue / connective matrix, adipose tissue / and the organic/endocrine, circulatory, nervous, immune/ systems.

MD-Matrix – ampoule 2 ml (Guna Spa, Milan, Italy), containing collagen and as excipients: citric acid + nicotinamide, is designed according to the conception of Physiological Regulative Medicine (PRM) in order to correct physiological imbalances in the tissue.

PURPOSE OF THE STUDY

To examine and evaluate the effects of simultaneous application of two established techniques – Acupuncture and Mesotherapy with MD-Matrix in patients with Localized Abdominal Adiposity.

PATIENTS AND METHOD

Inclusion criteria

Our investigation covered 23 healthy women aged between 27-53 with excess abdominal fat deposits.

No special diet was given to the patients.

It was only recommended to take once a week 1500 g. of fruits divided into 4 equal portions during the day.

From February 2011 to July 2011, ten sessions of Acupuncture + Mesotherapy were carried out once a week.

Subcutaneous injections at 5-10 mm depth, using needles 27G and injecting 0.2 ml MD-Matrix in the following acu-points: **Ren12, Kd16, St25, Sp15, GB26, Ren6**.

Measurements of the circumference on the level of the umbilicus was taken before starting the treatment, at the beginning of every next session and at the end of the therapy.

RESULTS

All patients have obtained an objective reduction of the localized abdominal fat deposits.

- 2 subjects (8.7%) reduction of umbilical circumference 3.0 cm.
- 4 subjects (17.4%) reduction of circumference 4.5 cm.
- 3 subjects (13.0%) reduction of circumference 5.5 cm.
- 7 subjects (30.4%) reduction of circumference 6.5 cm.
- 4 subjects (17.4%) reduction of circumference 7.0 cm.
- 1 subject (4.3%) reduction of circumference 8.5 cm.
- 1 subject (4.3%) reduction of circumference 9.0 cm.
- 1 subject (4.3%) reduction of circumference 11.5 cm.

CONCLUSIONS

The clinical evaluation provides important positive data regarding the effectiveness of Acupuncture + Mesotherapy with MD-Matrix in women with Localized Abdominal Adiposity.

A significant decrease of the umbilical circumference has been noted with an **average of 6.3 cm**.

– It can be concluded that this combination ensures synergistic results – correction of localized excess of fat deposits and restore of the physiological balance in the treated tissue. Additional benefits are the improved self-confidence and physiological comfort. ■

Abstract presented at the
5th International Medical Acupuncture Congress
5th-6th November 2011, Barcelona - Spain

First author

Dr. S. Elenkova, MD
– Center of Integrative Medicine
Sofia, Bulgaria

ACUMESOTHERAPY WITH INJECTABLE COLLAGEN IN PATIENTS WITH LOCALIZED ADIPOSITY OF THE KNEES

Elenkova Silvia, MD, Center of Integrative Medicine, Sofia, Bulgaria, e-mail: dr.elenkova@abv.bg
Pozharashka Joana, Center of Integrative Medicine, Sofia, Bulgaria, e-mail: pojarashka@gmail.com

KEY WORDS
- Localized adiposity
- Mesotherapy
- Local knee acupuncture points
- Injectable collagen MD Matrix

THE PROBLEM: The Localized Adiposity is not only an aesthetic problem, but a complex pathology – an external expression of numerous metabolic alterations in the tissues /connective matrix, adipose tissue/ and the organic /endocrine, circulatory, nervous, immune / systems.

- Is the accumulation of brown fat, rebellious to the physical activity in certain areas of the body that cause alterations in body contour.
- It is usually located in the abdomen ("lifeguard or rolls") to the sides of the legs (" riding pants"), shoulder and back of the arms, back ("hump"), inside of knees, etc.

FOUR FACILITATING ADIPOSITY FACTORS
- Alcoholic beverages: every gram of alcohol has 7 kilocalories.
- Smoking: Smokers have more fat in the abdomen than non-smokers.
- Sugar and fat: the combination tends to increase the volume of the abdominal area.
- Swimming in cold water increases the appetite and body fat accumulation as a mechanism for heat conservation. swimming is a very complete sport, but in very cold water can have "side effects".

THE HYPODERMIS is made up of adipocytes grouped in lobules approximately 1cm in diameter; they are separated by walls of connective tissue through which blood and lymph vessels run. From these walls others emerge surrounding the lobes with abundant micro capillaries resulting in a very vulnerable terminal structure.

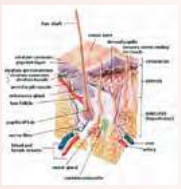

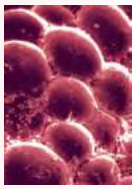

ADIPOCYTES/ELECTRONIC MICROSCOPY/

PATHOGENESIS OF LOCAL ADIPOSITY
There is not single opinion. The most popular pathogenetic models mentioned are:
- **Poor oxygenation** of tissues and accumulation of waste material and liquid in the connective tissue.
- **Disorders of lymph drainage** – adipocytes and the accumulated liquids push and spoil the connective tissue, break collagen fibers and block blood and lymphatic flow.
- **Hormonal influences** – fat distribution is regulated by **17 – beta estradiol**. Regarding the hormonal changes there is a greater predisposition for development of fat cells in women. In adolescence there is increased activity of the estrogen-dependent **lipoproteolipase**, which is who contributes triglycerides to the fat cells. The **lypogenic hormones** are mainly **insulin and estrogen**.

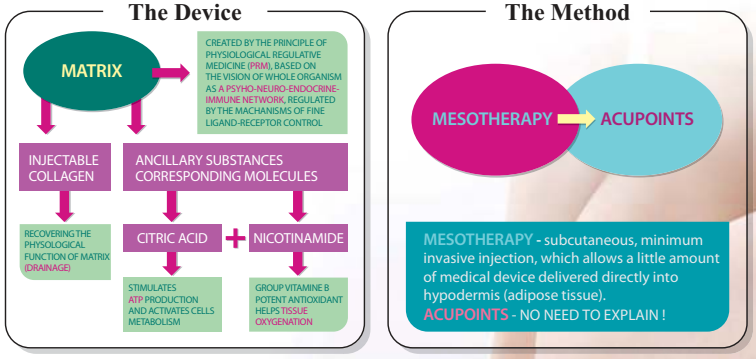

PURPOUSE: **To examine and evaluate the effects of simultaneous application of two established techniques – Acupuncture and Mesotherapy with Injectable Collagen in the treatment of adipose accumulations, located on the knees.**

DESIGN OF THE STUDY: **Our investigation covered 22 women with excess fat deposits on the knees, aged 25-51 years, answering the inclusion criteria. They were under our observation from October 2011 to March 2012. During this period ten sessions of Acu- mesotherapy were carried out once a week. Measurement of the circumference on the level of popliteal crease was taken before starting the treatment, in the beginning of every next session and at the end of the course.**

We were making subcutaneous injection at 5-10 mm depth, using needles 27G and injecting 0,3 ml Collagen /MD-Matrix/ in the following acu-points:

St-34, St-36, Sp-9, Sp-10, Liv-8,Bl-40 and 0,2 ml in St- 35

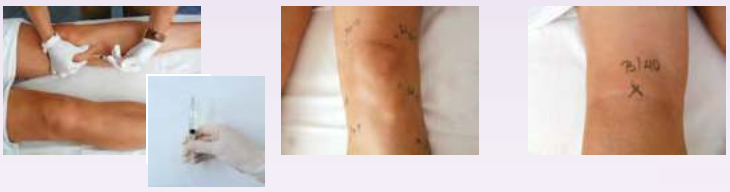

RESULTS: **All patients obtained objective reduction of the localized knee fat deposits.**

The decrease in knee circumference is statistically significant: F(2, 42) = 208,708, p<0.001, analyzed with Repeated measures analysis.

Repeated measures analysis:
Before treatment: mean 42.68sm,
After 5th session: mean 41.07sm,
After 10th session: mean 39.36sm

Histogram of the reduction after 10th session:

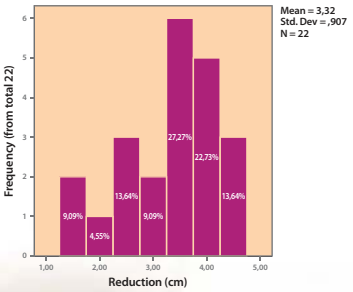

Reduction after 5th and 10th session:

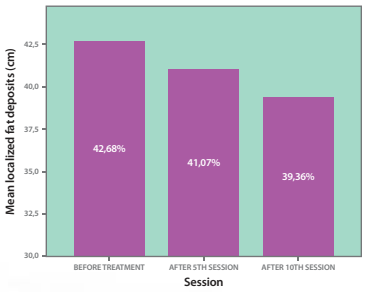

THE RESULTS BEFORE/AFTER THE TREATMENT

CONCLUSIONS: **This clinical evaluation provides positive data regarding the effectiveness of Acumesotherapy with Injectable Collagen in women with Localized Knee Adiposity. The significant decrease of knee circumference at an average 3,3 cm allows us to conclude, that this combination ensures synergistic results - correction of localized excess fat deposits and restore of the physiological balance in treated tissue.**
Additional benefits are reduction of the pain in patients with Hoffa's disease and improved self-esteem .

E. Falconi Klein

FACE REVITALIZATION - BIOLIFTING WITH MD-TISSUE

SUMMARY

In our society there is a major interest in the treatment of ageing skin with revitalizers that stimulate new collagen production and that can enhance face luminosity and freshness without damaging the health of the patients treated.
The aim of this study is to demonstrate the efficacy of the medical device MD-Tissue as a face revitalizer. Fifteen female volunteers have been treated with weekly injections for six consecutive weeks; the evaluation has concerned only the nasolabial folds.

– A photographic documentation with Visioface® Quick has been carried out and the volume of the wrinkle has been calculated; during the treatment period of the elasticity has also been measured. The Collagen Medical Device MD-Tissue has been perfectly tolerated by all volunteers.
It has proven an average capacity in the improvement of the skin elasticity and a good capacity in the reduction of the wrinkle volume.

KEY WORDS

SKIN AGING - FACE REVITALIZATION - COLLAGEN MEDICAL DEVICE MD-TISSUE, VISIOFACE® QUICK, ELASTICITY, WRINKLE VOLUME

SKIN AGING

The aging of the skin – especially the one of the face – is a growing concern for most people, regardless of their age.

Patients can be very young, looking for tips to prevent wrinkles, or they can be middle-aged, desiring to look younger or at least keep their appearance unchanged. On other occasions patients start treatments when they are elderly, and have finally decided to do something for themselves.

– Skin aging depends on several factors: biological senescence and genetic heritage (chrono-aging), photo-aging due to UV rays, and finally on lifestyle (diet, alcohol, smoking, pollution and oxidative stress).
The appearance of the aged skin varies depending on the prevalence of chrono- or of photo-aging (1, 2, 3): the senile skin is pale and dry, thin, floppy, hypo-elastic and finely wrinkled, whereas the photo-aged skin is rough, patched and crossed by deep wrinkles, the skin is anelastic and the horny layer is thickened; the smokers' skin is also sallow and dull.

WRINKLES AND THEIR PATHOPHYSIOLOGY

The causes that lead to the formation of the wrinkles are – in addition to chronological aging as a whole – the degradation of the elastic fibers and the alteration of the collagen ones (caused by the sun), muscle and joint movements, and the force of gravity.

The formation of wrinkles is affected by these factors to different extents and – consequently – also in the classification of the aging degree.
The classification of the signs of aging conducted by Kligman (1) can help to identify the various stages of the aging process: linear wrinkles, glyphic wrinkles, creases, lines of articulation, nasolabial folds (4).
Linear wrinkles result from linear contraction of the mimic muscles of the face, when they lose tone and elasticity. At first they are temporary folds and furrows, then they mark the face increasingly, following the muscle movement.

For instance, the "crow's feet", around the eyes; the "wrinkles of wonder", parallel to the front; the "thinker's wrinkles", vertical at the center of the eyebrows, the "smoker's wrinkles" that surround the mouth.
All gradually become more marked in relation to the photo-induced damage.
Glyphic wrinkles – which other authors define as skin texture – are lines that form square or rhomboid areas on the skin surface; with aging they become more evident, they are particularly noticeable on the cheeks of the elderly with photo-damaged skin.
Creases – better known as "the folds of

sleep" – develop late, caused by the head resting on the pillow while sleeping.
Their vertical course crosses the vertical mimetic muscle lines, especially on the forehead and cheeks.
The lines of articulation are those found in places where there is a hinge movement (ankles, elbows, wrists, etc.); existing since the birth, they become more marked and increase in other zones too (neck, trunk, etc.) with senility.
They are not very much considered from the point of view of cosmetology and dermatology, nevertheless.

Finally, the nasolabial folds, which have been taken into consideration in this article, and the folds of muscle-skin laxity that appear when the collagen and elastic texture is no longer able to counteract the force of gravity and present themselves as a falling of the skin due to the force of gravity.

The loosening skin is the outward visible result of the degradation of the connective tissue in which collagen, elastin, fibronectin and proteoglycans have lost their cohesion, their strength and ability to respond to elastic stimuli.
This phenomenon is connected to aging or to prolonged sun exposure, or even to weight loss following a state of obesity (4).
Revitalizers are very suitable for patients who want a natural treatment which does not change the facial expression.
The possibility of using a revitalizing such as **MD-Tissue** could offer many advantages. It is a product that has been planned for soft tissues, able to create a defense barrier against free radicals and to counteract the physiological aging of connective tissue (5).
These are all properties required for the use of a good tissue revitalizer.

Homeopathized collagen has been used since the 90s (Kollagen D6, D8) and after the first encouraging results, more revitalizing substances have been added.

Thus, the product **MADE** was born; it contains Collagen D8/D30, Hyaluronidase D8/D30 and Magnesium D6 (6).
Collagen D8/D30 works by stimulating the production of endogenous collagen, because – according to the law of the Arndt-Schultz reverse effect – weak stimuli (diluted doses) excite the biological activity.
The Hyaluronidase D8/D30, acting with the mechanism of the inverse effect, encourages greater compactness of the basic substance reducing wrinkles and toning the skin.
Magnesium D6 stimulates the production of exogenous collagen too.
– MADE also contains enzymatic catalysts, which act on the cellular respiration, drainers and organotherapy medicines with toning and revitalizing effects (6).

THE TUNNELING TECHNIQUE

Tunneling represents an infiltrative technique which consists in introducing the needle (in this study it was used the 27G needle) for its entire length almost tangentially to the skin surface, so to take wrinkles or nasolabial folds for their entire length.
Once introduced the needle, one starts to inject the substance and simultaneously pulls the syringe in a retrograde sense until the needle comes out.

– The purpose of this paper is to demonstrate the effectiveness of the medical device MD-Tissue, measuring objective parameters before, during and after the treatment of fifteen volunteers aged between 33 and 50 years.

In addition to the photographic documentation of the wrinkles with the photographic method Visioface® Quick, measurements of skin elasticity are performed with the elastomer.
All the equipment above described was kindly made available by BIOBASIC Europe Srl, Milan (Italy).

MATERIAL AND METHODS

– MD-Tissue

Fields of application known so far:
MD-Tissue is intended to improve the movement, helping to contain the physiological deterioration of joints and tissue and counterbalance the effects of a variety of causes including:
- Aging
- Postural defects
- Concomitant chronic diseases
- Trauma and injuries
- Polluting agents.

MD-Tissue is a medical device useful for facilitating mobility, counteracting the physiological aging of connective tissue, whose primary therapeutic treatment consists in the following functions:
1. Barrier
2. Lubricant
3. Mechanical support in the case pharmacological therapy.

– We recommend the use of MD-Tissue to be undertaken by qualified health professionals.

– Treatment protocol

Two treatments for the first 2 weeks, 1 treatment until improvement of symptoms (8-10 sessions on average).
If necessary, continue with one treatment every other week for a maximum of 10 sessions. Chronic pathologies: continue with 1 treatment a week for 1 month until improvement of symptoms, and subsequently 1 treatment a month.
- via intradermal injection: the area of application must be sterile; introduce the needle to a depth of 1-3 mm.
- via periarticular injection: the area of application must be sterile; introduce the needle in the proximity of the joint to a depth of 2-4 mm.

– Method of administration

For this use of the medical device, it is recommended to use the following materials and accessories:
- Material to ensure skin asepsis: dispo-

sable gloves, iodine based solution, alcoholic solution, sterile gauzes, ethyl chloride spray.
- Sterile needles (27G)
- Syringes (5 or 10 cc), depending on the amount of solution to be injected.

– Contraindications / Side Effects

No case of hypersensitivity to MD-Tissue has been reported.
Patients with known hypersensitivity to the component or the excipients must be previously undergo injecting test in the arm and kept under observation for one hour.

– Protocol applied for revitalization with MD-Tissue

Before proceeding with the treatment all the volunteers signed an informed consent. Then an allergological test with intracutaneous injection of a small amount of MD-Tissue was performed on all the volunteers in order to exclude a possible sensitization.

None of the 15 volunteers had any adverse reaction to MD-Tissue.

– After a phase of clinical observation lasting 30 minutes – which is generally sufficient to exclude immediate type I allergic reactions – basal measurements have been taken (time 0, T0) by performing a measurement of the skin elasticity of the **nasogenian fold** and a photograph of the face performed with the Visioscan® was also taken.
It was decided to apply a pattern that is frequently chosen in various protocols for anti-aging revitalization of the face. The injective treatment with MD-Tissue was performed once a week for 6 consecutive weeks.
At each session it was injected intradermally a 2ml vial of MD-Tissue in the nasogenian folds, following linearly the nasogenian fold with the tunneling technique.
Some volunteers have called for the application of an anesthetic cream prior to receiving this treatment.
The needle used was 27G.

After the 3rd session and prior to the 4th session, intermediate measurements (time 3 weeks, T3) were taken with photo-documentation and measurement of the elasticity, so to be able to better assess the progress of the treatment.
At the end of the treatment (after the 6th session) – 7 days after the last treatment – the latest measurements were carried out, always with photo-documentation and measurement of the elasticity.

– Self-evaluation form

At the end of the treatment, the volunteers filled out a self-evaluation form. The votes are comprised between 0 and 10, where 0 is equivalent to "not at all" and 10 to "very much." The evaluation is expressed spontaneously, in writing and kept reserved by the patient to avoid any influence from the doctor.

The questions that have been chosen for this experiment are the following:

1. To what extent do you think that the product reduces the visibility of the expression lines?
2. To what extent do you think that the product reduces the visibility of micro wrinkles?
3. To what extent do you think that your wrinkles are less deep?
4. To what extent do you think that the product increases skin elasticity?
5. To what extent do you think that the product increases your skin brightness?
6. To what extent do you think that your skin looks fresher / revitalized?
7. To what extent do you think that that the product increases your skin firmness?
8. To what extent do you think that the product increases your skin smoothness?
9. To what extent do you think that the product improves your skin texture?

Long term skin elasticity

Volunteer n.	t0	t 3 weeks	t 6 weeks
1	0,8123	0,8129	0,7092
2	0,6720	0,6786	0,7213
3	0,8785	0,8591	0,8088
4	0,6879	0,7143	0,7398
5	0,6906	0,7990	0,6931
6	0,7642	0,8412	0,8526
7	0,7500	0,8452	0,8400
8	0,7654	0,8168	0,8000
9	0,8265	0,8022	0,8387
10	0,8406	0,8300	0,8377
11	0,7721	0,8128	0,6633
12	0,7893	0,8084	0,8280
13	0,8150	0,7738	0,6606
14	0,7686	0,8254	0,6812
15	0,8030	0,8138	0,8067
Average	0,776	0,802	0,765
Dev. STD	0,0584572575	0,0480712665	0,0716924682
	Δ%	3,4	-1,3

TAB. 1
Long term skin elasticity.

10. To what extent do you think that your skin looks healthier?
11. To what extent do you think that the product gives your skin a "comfortable" feeling?

In the interpretation of the results it was decided to unify some votes to avoid data loss.
– The votes 9 and 10 are considered "very good"; 7 and 8 "good"; 6 "fair"; 3, 4 and 5 "poor".

– Skin elasticity

Skin elasticity is defined as the ability of the skin to stretch without breaking down, then returning to its original shape.
It has been measured with the elastomer (Cutometer® MPA 580, Courage-Khazaka Electronic GmbH, Koeln, Germany).
Applied to the skin, this device performs a suction of a part of the skin and the height reached by the aspirated layer refers to its degree of tensile distensibility; repeating several times the same maneuver, a further increase of skin distensibility can be observed – defined as tensile stretching, which is evaluated and recorded by the device.
The latest and most refined dermatological-physiological research could find that distensibility reflects the state of health of the collagen fibers of the dermis and that the recovery distensibility briefs about the conditions of the elastic fibers (4).

– Photographic documentation

The photographic documentation was performed with the computer system Visioface® Quick (full face photo analysis), CK electronic GmbH Koeln (Germany).

RESULTS

– Results of the measurement of skin elasticity

The results of the measurements of skin elasticity carried out on 15 volunteers at T0 (before treatment with revitalizing MD-Tissue) at T3 (1 week after the 3rd treatment, i.e before the 4th) and at T6 (1 week after the 6th and final treatment) are presented.
– The measurement was always performed on the nasogenian folds.
TAB. 1 lists all the numerical results of the 15 volunteers with their values at T0, T3 and T6.
– Overall, there was a slight increase in skin elasticity after 3 weeks of treatment, and after 6 weeks, the values return almost to baseline. The average of the values which initially was 0.776 increases on average to 0.802 after 3 weeks and then lowers again to 0.765.
After 3 weeks of treatment, 11 out of 15 volunteers (73.33%) show greater elasticity compared to the beginning.
Only 4 volunteers (number 3, 9, 10, 13) (26.33%) show a lowering of elasticity after the first three treatments.
After 6 weeks of treatment 9 voluntary out of 15 (60%) have greater elasticity than at the beginning, while 6 volunteers (number 1, 3, 10, 11, 13, 14) (40%) have a lowering of the elasticity under values of T0.
TAB. 2 represents graphically the results recorded by the volunteers (1-15).

– Results of photographic documentation Visioface® Quick

The volume and depth of wrinkles were studied with Visioface® Quick and the data processing was performed with the program Skin Surface Analyzer SSA.
From the front picture of the complete face it is chosen a small area located on the right or left nasogenian fold of each patient, this selected rectangular area corresponds to the "surface" of the wrinkle.
The "depth" of the wrinkle is measured in AU (Adimensional Unit).
It is a measurement scale created on a colorimetric basis to give depth to the selected area.

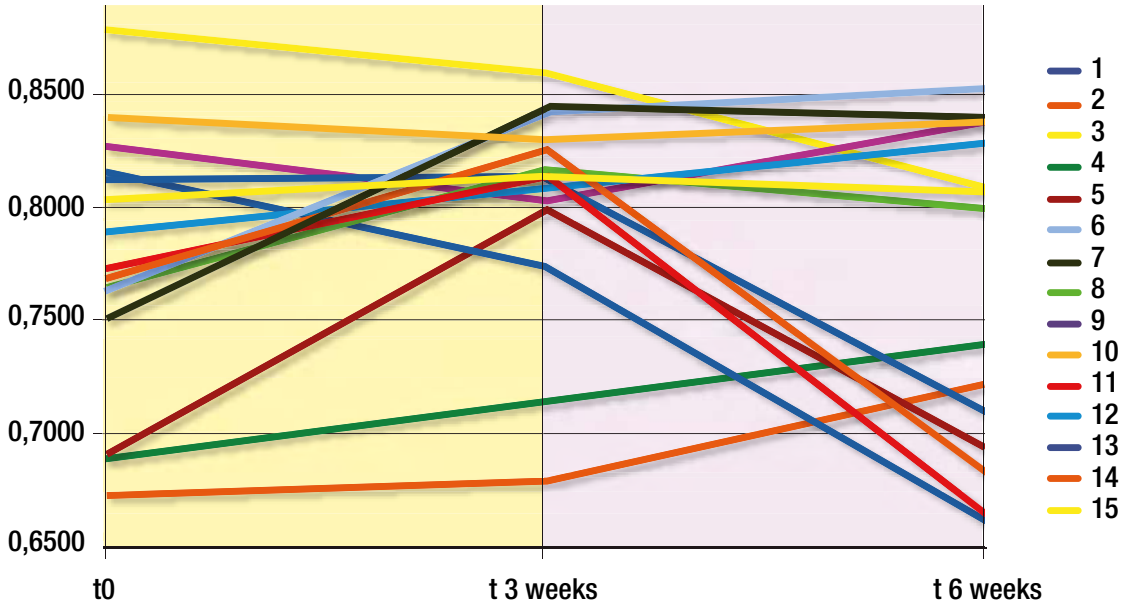

TAB. 2
Skin elasticity, graphical representation for each patient.

Volunteer n.	Wrinkle volume mm² X A.U. t0	t 3 weeks	t 6 weeks	%
1	0,4500	0,4500	0,3200	-28,9
2	0,2400	0,2000	0,2200	-8,3
3	0,1000	0,0900	0,0900	-10,0
4	0,1300	0,1600	0,1000	-23,1
5	0,8100	0,8500	0,7200	-11,1
6	0,2800	0,2300	0,2400	-14,3
7	0,2300	0,2300	0,1900	-17,4
8	0,2100	0,2500	0,2000	-4,8
9	0,1700	0,1900	0,1700	0,0
10	0,0800	0,0900	0,0800	0,0
11	0,3800	0,3600	0,3200	-15,8
12	0,1100	0,1000	0,1000	-9,1
13	0,5300	0,4000	0,4800	-9,4
14	0,2200	0,2400	0,2000	-9,1
15	0,1600	0,1500	0,1200	-25,0
Average	0,273	0,266	0,237	
Dev. STD	0,19722	0,19449	0,17182	
	Δ%	-2,7	-13,4	

TAB. 3
Wrinkle volume mm² 2 X A.U. with decrease percentage of each patient after 6-week treatment.

The "volume" of the wrinkle is the result of the following calculation:
Volume of the wrinkle (mm (2)) = AU x height (mm) x width (mm) x depth.

The volume of wrinkles was reduced by a total of 2.7% after 3 weeks and 13.4% after 6 weeks of treatment.
The values ranged from 0% to 28.9%.

– Results of self-assessment

Here below are shown the 11 questions along with the opinions expressed in votes and in percentage to which the 15 patients of the trial replied:

1. To what extent do you think that the product reduces the visibility of the expression lines?
   – The ability to reduce the visibility of the expression lines is considered by 80% of patients "good", by 6.67% "fair" and by 13.33% "poor".
2. To what extent do you think that the product reduces the visibility of micro wrinkles?
   – The ability to reduce the visibility of micro wrinkles is considered by 13.33% of patients "very good", by 53.33% "good", by 20% "fair" and by 13.33% "poor".
3. To what extent do you think that your wrinkles are less deep?
   – The perception of less deep wrinkles is for 6.67% of patients "very good", for 80% "good" and for 13.33% "poor".
4. To what extent do you think that the product increases the skin elasticity?
   – The increase in the skin elasticity is perceived by 86.67% of patients to be "good" and by 13.33% "fair".
5. To what extent do you feel that the product increases the brightness of your skin?
   – The increase in brightness is held "very good" by 13.33% of the patients, "good" by 66.67%, "fair" by 6.67% "fair" and "poor" by 13.33%.
6. To what extent do you think that your skin looks fresher / revitalized?
   – The perception of a fresh and revitalized skin is for 13.33% of patients "very good", for 66.67% "good" and for 20% "fair".
7. To what extent do you think that the product increases your skin firmness?
   – The increase in firmness is considered by 6.67% of patients "very good", by 73.33% "good" and by 20% "fair".
8. To what extent do you think that the product increases your skin smoothness?
   – The increase in smoothness is perceived by 6.67% of patients as "very good", by 60% "good" and by 33.33% "fair".
9. To what extent do you think that the product improves your skin texture?
   – The improvement in the skin texture is considered by 6.67% of patients "very good", by 46.67% "good" and by 46.67% "fair".
10. To what extent do you think that your skin looks healthier?
    – The perception of a healthier skin is for 6.67% of patients "very good", for 80% "good" and for 13.33% "fair".
11. To what extent do you think that the product gives your skin a

"comfortable" feeling?
– The perception of a sense of "comfort" is for 6.67% of patients "very good", for 73.33% "good", for 13.33% "fair" and for 6.67% "poor".

DISCUSSION

The aim of this study was to demonstrate the effectiveness of the medical device MD-Tissue as facial revitalizer.
15 patients – 33-50 years – were evaluated; first they underwent an allergy test with the provocation of a small intracutaneous wheal to exclude sensitization to the product.
MD-Tissue showed an acceptability of 100%, none of the patients experienced discomfort or side effects.
Consequently, they were administered weekly injections of MD-Tissue (2.0 ml), exclusively in the nasogenian folds. At the beginning of the treatment (T0), after 3 weeks (T3) and after 6 weeks (T6) a photographic documentation was performed using Visioface® Quick and the measurement of elasticity using the elastomer (Cutometer Courage - Khazaka).
At the end of the treatment the patients completed a self-evaluation questionnaire.

After 3 weeks of treatment the elasticity values showed an improvement of 73.33% and have achieved a total improvement of 3.4%; after 6 weeks of treatment they stabilized at 60%.

In order to achieve more indicative values, further measurements and – above all – a higher number of patients may be required.

However, the effect is present and elasticity in this work was higher after 3 weeks than after 6 weeks of treatment.

As for the photographic documentation obtained through the device Visioface® Quick and the data calculation achieved with the Skin Surface Analyzer SSA, results were highly positive.
The overall improvement of the patients, with a lowering of the wrinkle volume calculated by the Skin Surface Analyzer, was of -2.7% after 3 weeks and -13.4% after 6 weeks with peak improvements in the depth of wrinkles even reaching 28.9%.
– This very satisfactory result is also reflected in the data interpretation found in the patients' self-assessment questionnaire and in their happiness:

80% considered "**good**" the reduction of the visibility of the expression lines; they considered that the wrinkles on the face are less deep, and their skin healthier.
86, 67% considered "**good**" the increase in elasticity; **73.33%** judged as "**good**"; **6.67%** as "**very good**" the increase in the skin compactness; they also thought that the product gives a feeling of comfort.
66.67% considered "**good**" and **13.33%** "**very good**" the increase in skin brightness; they also thought the skin looked fresher and more revitalized.

In conclusion we can confirm that the medical device MD-Tissue revealed to be a reliable and safe product for the face revitalization.
– This can lead to several different uses in aesthetic medicine. The fluid texture of the product is definitely very suitable for the treatment of the neck, décolletage and back of the hands.
Face applications can include several techniques such as the treatment with micro wheals, injections in acupuncture points, eye zone and forehead rejuvenation. ■

References

1. Kligman L. - Photoaging: manifestations, prevention and treatment. Clin Geriatr Med **1989**;5: 235-251.
2. Gilchrest B.A. - Skin aging and photoaging: an overview. J Am Acad Dermatol **1989**; 21: 510-513.
3. Kang S., Fisher G.J., Voorhees J.J. - Photoaging: pathogenesis, prevention and treatment. Clin Geriatr Med **2001**; 17: 643-659.
4. Fracassi P., Marottoli M.S. - Dizionario di Dermocosmesi. Tecniche nuove, **2006**.
5. Milani L. - Un nuovo e raffinato trattamento iniettivo delle patologie algiche dell'apparato locomotore. La Med. Biol., **2010**/3; 3-15.
6. De Bellis M. - Omeomesoterapia in medicina estetica, Scuola di Omeopatia-Omotossicologia e Discipline Integrate. Dispense AA. **2011-2012**.

Acknowledgements

The author thanks the BIOBASIC EUROPE SRL staff for their collaboration as well as for the use of their devices.

Author

Dr. E. Falconi Klein, MD
– Specialist in Dermatology
– Specialist in Allergology
Via Mauro Macchi, 42
I – 20124 - Milano

CLINICAL

G. Felloni

DERMOAESTHETIC FACIAL MEDICINE – INTEGRATED THERAPY

SUMMARY

Ageing is a generalised process that affects all organs; however, it is common to refer to the skin when talking about biological ageing. Psychological experience, chrono- and photo-aging, and skin are closely related. Stress, which is at the root of the alterations in the systems, leads to a chronic inflammatory state that disrupts the balance of organs, particularly the skin, resulting in the appearance of blemishes and wrinkles.
The skin is the largest organ in the human body and is in close connection with the Autonomic Nervous System: muscular tightening, which constricts the blood vessels resulting in less O_2 supply to the skin Tissues, and the excessive production of cortisol, correlate to the occurrence of pathologies and kinesthetics.
Unlike classic aesthetic medicine, which only treats the blemish without considering the person as a whole, the integrated multi-systemic and multi-level approach places the underlying causes of the blemish at the centre, acting mainly on the basic chronic inflammation to recover, reactivate and maintain the 'youthfulness', health and quality of the skin.

– The multi-systemic approach involves the use of biological drugs that can 'talk' to the cells and bioregulate them, allowing a state of global well-being to be achieved along with the aesthetic result and to enhance all the other treatments in the therapeutic protocol.

– Twenty female patients aged between 35 and 70 years were enrolled and underwent several multilevel steps: bio-detoxification (by means of an oral drainage and hydration therapy of the extracellular matrix, a systemic anti-ageing therapy and a body detoxification); biostimulation (by means of a local infiltrative therapy), accompanied in some cases by radiofrequency intradermal needle therapy, the application of biorevititalising acids and carboxytherapy. Both steps involve solutions acting at multiple levels due to the effect of BrSM natural multi-components capable of modulating the physiological mechanisms regulating ageing and Made, Guna-Collagen, and MD-Tissue. The effects of the therapy were assessed by means of a self-assessment questionnaire by the patients and with photographs.

KEY WORDS

AGEING, INFLAMMAGEING, WRINKLES, GUNA-COLLAGEN, MD-TISSUE

"One does not become old because a certain number of years have rained down upon us: one becomes old because one has abandoned one's ideals.
You will stay young as long as you stay receptive.
Receptive to what is beautiful, good and great.
Receptive to the messages of nature, of man, of the infinite".

Gen. Douglas A. McArthur (1880-1964)

INTRODUCTION

The skin is a constantly changing organ that performs numerous functions:
- coating and protection from external agents
- regulation of body temperature
- sending tactile and pain information to the Nervous System
- immune defence
- production of vitamin D
- elimination of toxic substances.

The skin microbiome, which is in continuous communication with the gut microbiome, is dynamic and changes over time; its stability is lower than the intestinal one, probably due to the greater exposure to extrinsic varying factors as genotype, gender, age, environment, climate, geographic area, lifestyle, work activity, personal hygiene, concomitant diseases, immune activity, and inflammation.

– The skin is a very complex organ that acts as a protective barrier against the external environment.

It is the largest organ in the human body; its average surface area is between 1.6 and 1.85 square metres; the skin surface is characterised by the presence of folds, ridges and orifices.

The pattern of the texture of the palmar lines is genetically determined (arcs, loops, swirls). During embryonic development they begin to take shape before the onset of hand movements (around week 11 of gestation), do not change throughout life, have a high discriminating power and uniqueness and serve as a clinical-diagnostic aid in certain Syndromes due to chromosomal aberrations.

The **Extracellular Matrix (ECM)** of the dermal connective Tissue contains glycosaminoglycans (hyaluronic acid,

DIFFERENCES BETWEEN INTRINSIC AND EXTRINSIC SKIN AGEING

CHARACTERISTICS	INTRINSIC AGEING	EXTRINSIC AGEING: PHOTO-AGEING
SKIN APPEARANCE	smooth surface, deepening expression lines, moderate loss of elasticity	knotty and thickened surface with spots tending to yellow, deep wrinkles, significant loss of elasticity
EPIDERMIS	soft and radiant	marked acanthosis, cellular apathy
ELASTIC TISSUE	increased, normal appearance	increased, degenerated into amorphous clusters
COLLAGEN	thickened, non-parallel bundles	decrease in collagen bundles and fibres: transformation from soluble to insoluble collagen
GLUCOSAMINOGLYCANS, PROTEOGLYCANS	slightly smaller	markedly increased
RETICULAR DERMIS	softer, decreased and inactive fibroblasts, decreased mastocytes, inflammation absent	thickened with elastosis phenomena, increased fibroblasts, hyperactive, mast cells markedly increased, infiltrated with mixed inflammation
PAPILLARY DERMIS	absent in the border areas with the dermis	solar elastosis

TAB. 1

chondroitin sulphate and dermatan sulphate); hyaluronic acid is distributed throughout the connective fibres in the spaces between the fibres.

– These molecules contribute to the elastic properties of the skin.

The subcutaneous Tissue (hypodermis) is the deepest layer and is connected to the dermis by septa of fibrous connective Tissue; it consists of adipose Tissue and collagen; there are also larger blood vessels, lymph vessels and nerves.

– With age, the skin becomes pale and thin with less tolerance to solar radiation exposure due to a decrease in the number of melanocytes; the decline in sebaceous and glandular activity leads to dryness and the appearance of wrinkles due to the loss of elastic fibres, reduced vascular supply and lower sexual hormones.
There is the onset of solar lentigo, seborrhoeic and actinic keratoses and telangiectasias.

There is a chrono- and photo-ageing (TAB. 1); the latter mainly affects areas exposed to sunlight.
– Ultraviolet rays act, partly directly and partly mediated by the production of free radicals, on RNA, DNA, proteins, cell membrane and cytoplasmic enzyme phospholipids.
– Free radicals attack collagen and determine cross-linking bonds between fibres in the dermis, making them less elastic; they also attack hyaluronic acid, lowering its quality and functions.

Certain types of wrinkles are classified as:
– linear
– graphic
– creases
– naso-labial.

The state of health of the stomach, intestines, kidney, liver, etc., can be 'read' from the particular signs on the face; this proves that a comprehensive, integrated anti-ageing medicine is required, considering not only local problematic issues, but also the person in his or her entire 'being'.

"Every problem you recognise is but a tiny dot on the radar screen of your well-being. Every time you experience a difficulty, homeostasis is working for you to bring you back into perfect balance. Your role is simply to relax and allow nature to take its course".
(Alan Cohen - writer)

Stress, underlying the alteration of the organic systems, leads to a chronic inflammatory state that causes cortisol levels to rise in an attempt to manage and extinguish Chronic Low Grade Inflammation.
Furthermore, of great importance is the Gut-Brain Axis, in which the gut microbiota is considered the second brain that is subsequently in close communication with the skin's microbiota.

The skin's microbiota actively participates in the dual protective function of the skin, as a physical and immune barrier that hinders the development of harmful bacteria, generating an environment which is hostile for their development; with its activity of degrading skin surface lipids, it also protects against the immunosuppressive action that UV radiation causes in the skin.

It is important to maintain a balanced composition of the microbiota in order to avoid the colonisation of harmful bacteria; when this balance is disrupted, inflammatory problems, infections, allergies and autoimmune diseases emerge.
– Recent studies have shown that the imbalance and destruction of skin microbial populations correlates with the worsening of existing pathological conditions (e.g. Atopic Dermatitis, Acne, Psoriasis).

– Based on this evidence, scientific re-

search has started to focus on the study of new cosmetic products containing bacteria which is useful in combating the skin disorders caused by pathogens.

When talking about PNEI regulatory Systems, it is possible to understand how stress is at the basis of alterations in these systems and the cause of Chronic Low Grade Inflammation, and how adaptogenic substances reduce the load caused by stress and are a valuable aid for an organism seeking a balance of health.

Due to its function as a protective interface between the inside of the body and the highly contaminated external environment, the skin is densely colonised by a diverse and active microbiota, a complex and dynamic ecosystem inhabited by bacteria, viruses, fungi and archaea. – These, collectively referred to as the 'skin microbiota', are fundamental to skin physiology and immunity. Interactions between skin microbes and the host can 'fall' anywhere along the *continuum* between mutualism and pathogenicity.

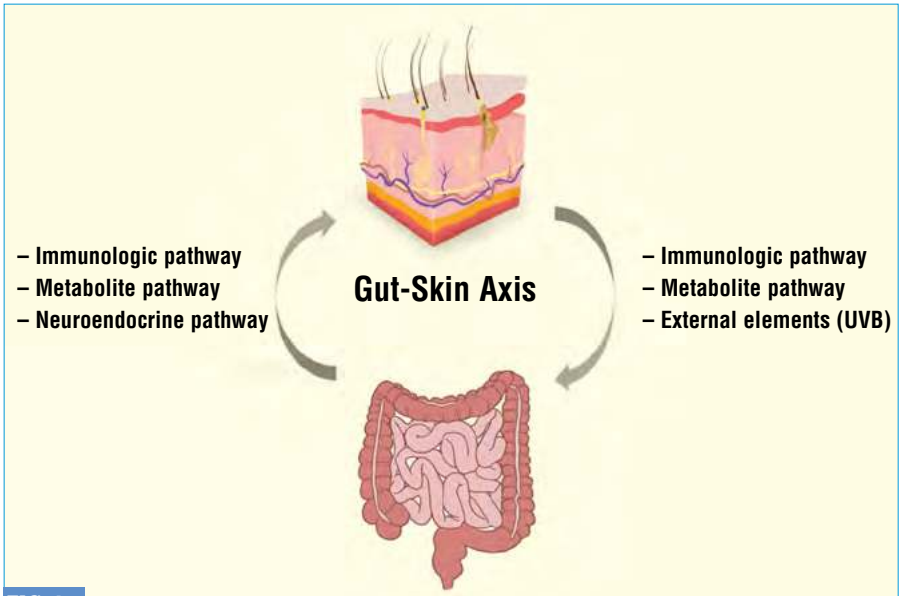

FIG. 1

Gut-Skin Axis.

Park D.H. *et* Al. – Comparative Analysis of the Microbiome across the Gut–Skin Axis in Atopic Dermatitis. Int. J. Mol. Sci. **2021**, 22, 4228. https://www.mdpi.com/1422-0067/22/8/4228

Although cause and effect are generally difficult to determine with certainty, changes in the skin microbiota clearly play a role in the pathobiology of multiple skin diseases and aesthetic disorders.

The skin microbiota is of great importance for human health and wellbeing; it is involved in several skin diseases such as Psoriasis, Eczema, Contact Dermatitis, food Allergies, Seborrotic Dermatitis, Acne rosacea and it plays an im-

FIG. 2 **Multi-systemic medicine.**

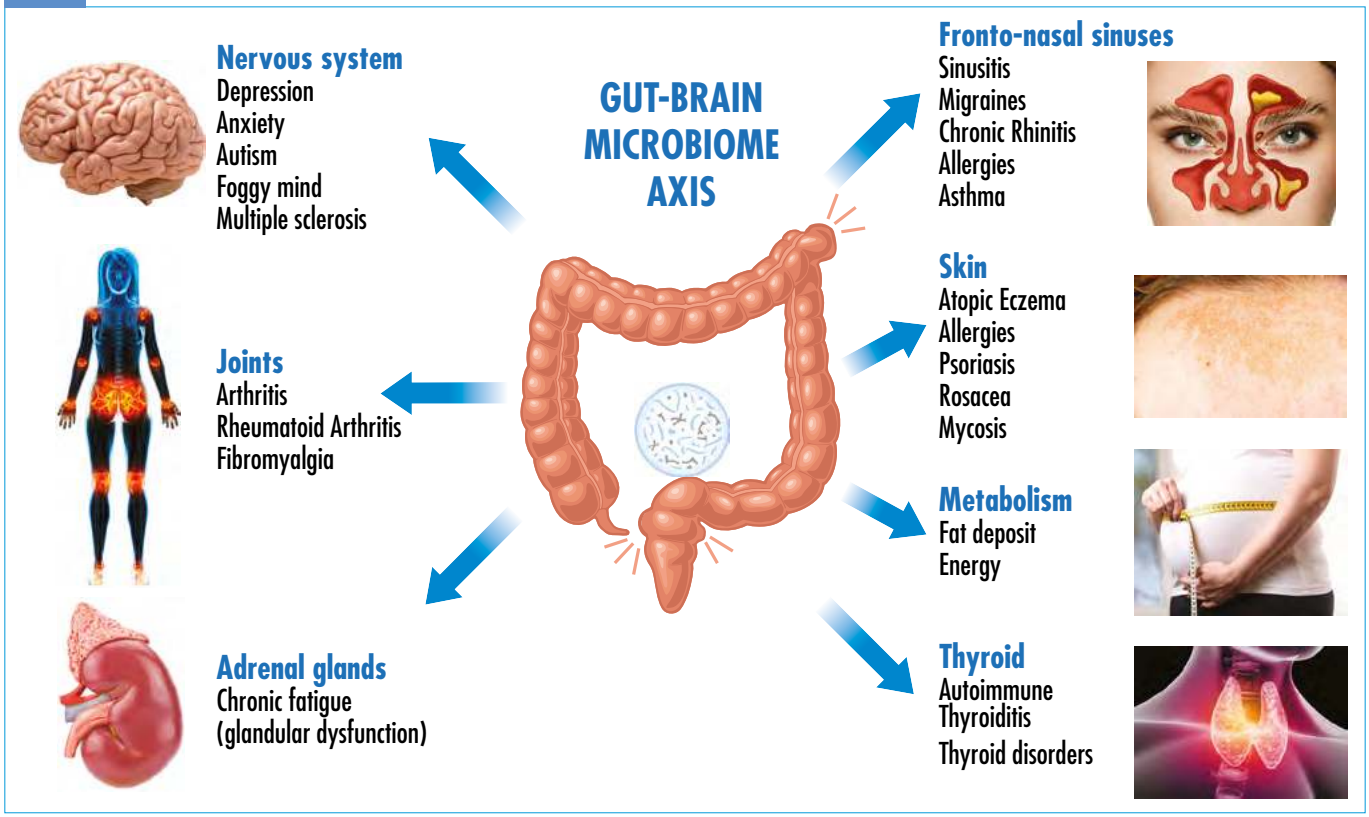

FIG. 3

Female, 40 years old. Slight skin laxity in the neck and "Venus rings" wrinkles; the patient underwent 4 sessions of biostimulation with Made (micro-injections); each session was performed every 2 weeks.

portant role in wound infections; it also plays an essential role in skin ageing, hence the importance of a **comprehensive** and **integrated therapeutic approach** that will act both topically and systemically with more physiological and natural methods.

– A crucial role in the onset of Acne, for example, is certainly played by *Propionibacterium acnes*, whereas atopic dermatitis involves *Staphylococcus epidermidis* and *Staphylococcus aureus*.

– Several ongoing studies aim at restoring the balance of the skin's microbiota and the subsequent well-being of the individual by means of skin therapies with prebiotics or probiotics and the use of thermal waters in subjects with Psoriasis.

For some dermatological diseases, a link has been shown with **intestinal dysbiosis** characterised by poor microbial biodiversity which is quite similar to that seen in patients suffering from Irritable Bowel Syndrome (IBS).
In many cases, the administration of certain strains of probiotics led to a lessening of intestinal and systemic inflammation and, subsequently, an improvement in skin symptoms.

– Such evidence demonstrates the existence of a true **'Gut-Skin Axis'** (FIG. 1).
The visceral brain presides over the vital functions of survival and is able to store stress and emotions, while the CNS regulates cognitive and relational function.

The gut produces neurotransmitters and psychoactive substances that influence moods (serotonin, endorphins) and the Gut-Brain Axis; consequently, the skin comprises direct links between these organs with reciprocal influences.

It is essential to rebalance the gut microbiome to achieve positive, enhanced and long-lasting effects on the skin.
The connection between gut and brain is via the vagus nerve and the release of serotonin (secreted mainly in the gut), melatonin, tryptophan, GABA, and Peptide YY*.
Oxytocin is also produced in the brain, but its formation can be favoured, via the vagus nerve, by a balanced microbiota and in particular by *Lactobacillus reuteri*.

Performing the function of support, union and protection between the different Tissues are the connective Tissues, within which ECM is present in abundance.
– To put it simply, the ECM has the fundamental purpose of connecting the various cells in the body. Its most abundant component is **collagen**.
Another of the components of the ECM is the so-called **Fundamental Substance (FS)**, a colloidal gel-like structure that is deposited in the interstices of the fascial structure or 'Fascial System'.
A particular feature of the FS is that inside there are structural elements such as lymphatic vessels, fibroblasts and fibrocytes, axons and arterio-venous capillaries. It is particularly the presence of all these elements that gives the ECM the articulated capacity to communicate at a distance between organs and apparatuses, albeit very different ones.

When an acid-base imbalance occurs, the composition of the FS is modified, becoming less fluid, reducing some of its most important functions, including its lymphatic drainage capacity, venous-capillary interchange and the plasticity of the Fascial System.

– In addition, it should be noted that the ECM also contains toxic metabolites.
The latter, together with the different state of FS and its ionic concentration, de-

* **Editor's note**: Peptide YY is a hormone produced by the L-cells of the mucosa of the ileum and colon.

termine both the reactive modes and the development of certain characteristics of the individual, as well as ageing and the involvement of the Immune, Hormonal and Vegetative Nervous Systems.

• It is mainly the Lymphatic System that ensures the efficiency of the ECM.

Not all of the capillary transudate fluid re-enters the vessels: 10% of it (≈ 3 L/day), is deposited in the Tissues, turning into interstitial fluid.

– Therefore, it is essential that the Lymphatic System is able to operate at its best in the re-circulation of proteins and fluids: only in this way can correct homeostasis be maintained and fluids be prevented from accumulating in the ECM.

– When the excretory organs fail to adequately eliminate acidic waste, it accumulates in the ECM, which reacts through a general detoxification action, like a *metabolic sponge*.

The accumulation of acidic residues, resulting from catabolism, will however take place at the expense of the transformation of colloidal substances from the sol to the gel state; the functions of

BEFORE AFTER

BEFORE AFTER

BEFORE AFTER

FIG. 4

Females, 65-67 years old. Severe degree of skin ageing.
– Six multilevel biostimulations were carried out on a weekly basis with Made + Guna-Collagen in a cocktail, followed by MD-Tissue; patients were then subjected to laser CO_2 treatment fractionated with double-pass and radiofrequency intradermal needling to complete the therapeutic procedure.
Maintenance with multi-level biostimulation, 2/month.

FIG. 5

Female, 65 years old. Increased evidence of advanced ageing in the middle-lower third with pronounced perioral micro-wrinkles and deep wrinkles in the nose-genius area; 3 sessions of biostimulation with MD-Tissue every 2 weeks were carried out.

FIG. 6

Female, 53 years old. Skin laxity on the inner side of the arm; 3 biostimulations every 2 weeks with Made + Guna-Collagen in a cocktail preceded by carboxytherapy.
– The patient continued with multi-level biostimulation and without needles in the same session, maintaining carboxytherapy, 1/month.

the ECM, together with the exchanges between cell and matrix, will tend to slow down.
The centrifugal force produced by the blood circulation pushes all the denser and heavier substances towards the periphery of the organism; skin changes caused by external irritation are rarer than those caused from within due to toxemia.

– The skin is thus to be considered as a draining organ that comes to the aid of the kidney, liver and lymphatic system.

Lymphatic drainage, **liver detoxification**, the **functionality of the ECM, intestinal microbiome,** and **acid-base rebalancing** are therefore fundamental.

The studies of Candace Pert, author of *"Molecules of emotion. Why you feel the way you feel"* have been able to ascertain the link between emotions and physiology, so much so that they claim that: *"this more holistic approach complements the reductionist view, expanding it rather than replacing it, and proposes a new way of understanding health and disease, not only to us scientists but also to laymen. We could define the entire system as a psychosomatic network of information, linking the psyche, comprising all that is non-material in nature, such as mind, emotions and soul, to the soma, which is the material world of molecules, cells and organs. Mind and body, psyche and soma"*.

▶ Unlike classical aesthetic medicine in which we intervene by directly treating the imperfection, without considering the person as a whole, **the multi-systemic approach** mainly targets the causes at the origin of the blemish, acting on the chronic inflammation to recover, reactivate and maintain the "youthfulness", health and quality of the skin (FIG. 2).

– This innovative approach for the patient acts on cellular vitality and restores the physiological balances that sustain them.
Blemishes are considered the reflection of an imbalance in the entire organism; by acting on the real causes of ageing and related phenomena, a state of global well-being can be achieved.
We are aiming for a person's harmony and psycho-physical well-being; **nutrition**, **nutraceutics**, **water** and **exercise** play a very important role.

– There are two distinct therapeutic steps that can be applied successively or in parallel.
STEP 1: bio-detoxification, through systemic oral therapy, aimed at draining toxins from the ECM, systemic anti-aging therapy and body detoxification, when necessary;
STEP 2: biostimulation through local injection therapy, aimed at biostimulating cellular turnover processes.

Both steps provide solutions that act at multiple levels through the effect of multi-component/multi-target natural medicines capable of modulating the physiological mechanisms that regulate ageing, without side effects.
STEP 1 can be enhanced by low-dose signal molecules capable of stimulating Tissue trophism.
STEP 2 is multi-layered through **low-dose multi-component/multi-target drugs** and **Collagen Medical Devices**, which are able to modulate the physiological mechanism leading to ageing; the latter act as scaffolds of the ECM, able to replace a structural vacuum.

– For a customised therapeutic strategy, they can be used individually or both, at several levels.

MATERIALS AND METHODS

• Systemic therapeutic protocol:
– Proflora, 1 sachet/day; it is a symbiotic food supplement containing 6 different probiotic bacterial strains that promote the natural well-being of the intestinal microflora;
– Guna-Matrix, 20 drops x 2/day + **Guna-Lympho**, 20 drops x 2/day x 2 consecutive months.
Repeat Guna-Matrix cyclically throughout the year.
– Lipidic Vitawin C, 3 capsules/day to be taken at main meals x 2 consecutive months.

• Local therapeutic protocol:
– Guna-Collagen, 1 fl + **Made**, 1 fl; weekly infiltrative therapy for at least 5 consecutive weeks, in a mesotherapeutic mode by means of an injector with the needle depth controlled by a computerised system, or by means of manual mesotherapy injections.
– In some patients where the ageing process needed deeper action, **MD-Tissue** was injected in the same way.

The infiltrative technique is the microinjection technique, which is very suitable for reaching the dermal layer.
– The 30G needle is inserted very slowly and constant pressure is applied to the syringe plunger until a small white intradermal papule appears.
Depending on skin ageing, these treatments were accompanied by sessions of **carboxytherapy** [preceding biostimulation (STEP 2) and performed in the same session], with **needle-free biostimulation** and more invasive techniques such as the **fractioned CO_2 laser** and **intradermal needle-assisted radiofrequency**.

– Carboxytherapy consists in the subcutaneous administration of medical CO_2 in a gaseous state; it produces vasodilation and reactivation of the microcirculation, improves blood flow and skin metabolism, and increases tissue oxygenation.

– Needle-free biostimulation by means of peeling based on 33% trichloroacetic acid, kojic acid and hydrogen peroxide preceded by skin microneedling was generally carried out after micro-injections of the multi-level medicine products to enhance their effects.

– Treatment with the fractional CO_2 laser involves the execution of many tiny (a few microns) holes by means of a laser beam that reaches the dermis; it causes heating that generates the formation of young collagen.

The presence of new collagen results in the rejuvenation of the skin surface, from which corneous cells are removed, and the dermis, which thus acquires greater lustre and tone.
– Biostimulation treatments generally precede laser sessions to make the surface fertile and healthy in order to enhance their effects.

– Intradermal needle radiofrequency is the new generation microneedling device that offers immediate and long-term results, with well-tolerated sessions and very short recovery times.
This minimally invasive treatment helps stimulate natural collagen production and is effective in improving facial and neck wrinkles and acne scars.

Collagen synthesis stimulation and induction treatments, better known as

FIG. 7

The patient underwent 5 sessions of biostimulation with Made (microinjections) on a weekly basis using the needle gun and 1 session of fractioned CO_2 laser in "soft" mode: thanks to the BrSM medication, an optimal result was achieved, maintained and enhanced with the CO_2 laser, using parameters far below classical non-surgical blepharoplasty treatments.

FIG. 8

Female, 53 years old. The patient underwent 5 sessions of carboxytherapy followed by biostimulation on a weekly basis; there was a significant decrease of micro- and macro-wrinkles, especially in the periocular area; texture healed.

FIG. 9

Female, 50 years old. Medium to severe chrono- and photo-ageing on the neck.
– Four biostimulation sessions were carried out followed by multi-layer application with manual acid massage (needle-free biorevititalisation) on a weekly basis.

skin resurfacing, are among the safest and most popular.

Skin microneedling requires the use of disposable needles that gently penetrate the dermal-epidermal Tissue at specific depths; it stimulates the release of multiple growth factors that induce neo-collagenesis and neo-elastogenesis in the treated area via a cascading effect.
It is a dermo-epidermal renewal treatment that does not damage the epidermis, is not selective on melanocytes and does not cause post-inflammatory pigmentation.

Biostimulation can precede radiofrequency by a few weeks or can be performed in the same session, after letting the Tissues cool down with a soothing mask; the multilevel treatment acts as an aid in recovering the discomfort produced by radiofrequency and 'educating' the tissues to a rapid functional recovery with an enhanced effect.

– All these multilevel treatments result in different effects:
1) anti-inflammatory action
2) local circulation stimulation
3) Tissue stimulation
4) collagen production stimulation
5) wrinkle reduction
6) skin firming
7) bioscaffolding action.

At the end of each treatment, approximately 1 ml of a beauty gel was applied *in situ* with a gentle manual massage to penetrate the product.

– The evaluation of the results was based on the patients' satisfaction using the PAIS scale (Editor's note: The Psychosocial Adjustment to Illness Scale) and photographs.

RESULTS

This study shows that BrSM therapy, nutraceuticals and the multi-system approach are effective and highly efficient

in both the prevention and treatment of skin ageing.

– Patients report markedly improved well-being and general psycho-physical health compared to the start.

The total absence of adverse reactions and the results obtained ensured excellent compliance with both outpatient and home therapy.

– The study shows that the protocols applied are effective and safe in treating skin ageing (FIGG. 3-10).

DISCUSSION

Patients maintain their results through some basic daily activities: a proper diet, calorie restriction, macronutrient allocation, customised nutraceuticals, hormones, anti-free radical antioxidants, average aerobic and anaerobic exercise, stress management, self-care, sexual performance and socialising.

– Human beings are constantly changing; the processes of growth and ageing are the most striking examples of this reality.
Becoming aware of one's own evolution, of the rhythms and interconnections that keep a body alive, means learning to understand and to take care of oneself in order to achieve inner and outer harmony.

From the above, it is easy to understand the importance of a comprehensive and patient-friendly approach: doctors must not limit themselves to a single blemish, but... must look beyond the skin.

The secret to staying 'young' and healthy is to provide the body with the necessary tools to activate the regeneration and functional recovery processes.

FIG. 10

Female, 53 years old. The patient underwent 3 sessions of biostimulation, 1 session every 2 weeks; at the last session, needle radiofrequency was also used.

Essential References

– Barabási A.L., Oltvai Z. – Network biology: understanding the cell's functional organization. Nat Rev Genet 5, 101-113; **2004**.
– Bianchi I. – Argomenti di Omotossicologia. Vol. 1. Guna Ed.; **1987**.
– Bianchi I. – Approccio omotossicologico alla patologia del Tessuto connettivo. La Med. Biol., **1996**/3; 11-24.
– Cainelli T. *et* Al. – Manuale di Dermatologia medica e chirurgica. McGraw-Hill Education; **2017**.
– Cazzavillan S., Santangà D. – Inflammaging. Tecniche Nuove Editore; **2020**.
– Compostella R. – Ayurveda maharishi. Tecniche Nuove Editore; **2018**.
– Corman L. – Viso e carattere. Iniziazione alla morfopsicologia. Mediterranee Edizioni; **2003**.
– De Bellis L., Poli A. – Alimentazione, nutrizione e salute. Edises; **2019**.
– De Bellis M., Frasca N. – Terapie delle rughe e del rilassamento cutaneo con iniezioni intradermiche di un farmaco omeopatico complesso (MADE®) - Risultati di uno studio multicentrico su 681 pazienti. La Med. Biol. **2004**/2; 7-19.
– Del Prete M., Lozzi A. – *Low dose Medicine* ed Infiammazione. IPSA Editore; **2017**.
– Mastrodonato F. – Medicina Biointegrata. Tecniche Nuove Editore; **2001**.
– Maggio C. – 100 anni da giovane. Edizioni L'età dell'Acquario; **2012**.

- Milani L. – Terapia dell'invecchiamento della matrice: la ricarica dell'orologio biologico. La Med. Biol., **2004**/4; 17-25.
- Perra A. – L'universo della matrice extracellulare. Advanced Therapies; **2018**.
- Pignatti M. – Dermobiotica. Alimentazione, microbiota, pelle. Minerva medica Ed.; **2018**.
- Pinoli L.M. – Terapia *low dose*, nutraceutica fisiologica ed alimentare dell'Infiammazione Cronica Sistemica di Basso Grado. La Med. Biol., **2016**/3; 37-46.
- Schiff M. – La memoria dell'acqua. Edizioni Andromeda; **2011**.
- Zanghirati W. – Fondamenti di fitoterapia. Istituto Medicina Naturale di Urbino; **1997**.

Fig. 2: (recomposed)
Source: Manera S. – Cervello intestino, un legame indissolubile. p. 94. Macro Edizioni, 2021.

Author

Dr. med. Giulia Felloni

- Level II Master in Aesthetic Medicine; Level II Master in Cosmetic Dermatology; Level II Master in Dermatological and Aesthetic Laser Therapy; Level II Master in Integrated Anti-Ageing Therapy
- Specialist in Nuclear Medicine and Radiotherapy

Via Don Giovanni Bosco, 7/C
I – 44122 Ferrara

Healthspan versus Lifespan
Il ruolo della Medicina Estetica

SIME 2025 | 46° CONGRESSO Società Italiana di Medicina Estetica | 20° CONGRESSO aimaa Accademia Italiana di Medicina Anti-Aging

16, 17, 18 MAGGIO
Roma Convention Center La Nuvola

MEDICAL DEVICE A BASE DI COLLAGENE, MD-TISSUE, NEL RINGIOVANIMENTO CERVICO-FACCIALE

Dott. Egidio Riggio, *Dirigente medico in Chirurgia Plastica presso l'IRCCS Istituto Nazionale dei Tumori Milano*

INTRODUZIONE E OBIETTIVI:

La cute invecchia perdendo tono ed elasticità con netta riduzione della matrice extracellulare dermica essenzialmente a causa di minor sintesi di collagene dopo i 35 anni e aumento della degradazione di collagene per l'azione proteolitica di enzimi MMPs (metalloproteinasi di matrice) che degrada il collagene di tipo I e III. Differentemente, nella cute giovanile non esposta a raggi solari, sintesi di collagene e sua degradazione sono in equilibrio fisiologico conservando l'integrità della pelle. Il collagene eterologo funge da bioscaffold stimolando migrazione e produzione dei fibroblasti. Un trattamento iniettivo a base di collagene porcino di tipo I può trovare indicazioni terapeutiche, usato singolarmente o associato ad altri metodi nel distretto viso-collo per trattare: rughe; ristrutturazione del connettivo sottocutaneo e perivascolare e del trofismo connettivale danneggiato da inquinanti esogeni/dismetabolismi.

MATERIALI E METODI:

Una serie di 12 pazienti (età media 53; 45-70) affetti da rughe al collo (8), barcode (5), fronte (3), guancia (2), sono stati trattati con iniezioni di collagene tipo I, dispositivo medico di derivazione porcina, MD-TISSUE a basso peso molecolare integrato con vit.C+B1–B2–B6 e gluconato di magnesio con tecnica di tunnellizzazione retrograda mediante aghi 27-30 gauge, con sessioni multiple da 2 a 6 per anno (media 3), distanziate 3-8 settimane.

PRE TRATTAMENTO

COLLAGEN

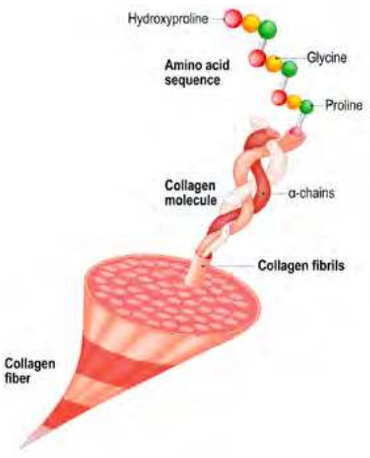

POST TRATTAMENTO

RISULTATI:

In tutti i casi il miglioramento estetico delle rughe è stato ottenuto mediante obiettivo confronto fotografico pre-post e mediante valutazione grado di soddisfazione delle pazienti in una scala da 0 a 10 con media di 8,5. In alcuni casi e in singole sessioni il prodotto è stato associato in sedi contigue ma non nelle medesime del collagene ad altri trattamenti topici.

CONCLUSIONE:

La biostimolazione con collagene come medical device di classe-III contiene il deterioramento fisiologico della cute e del tessuto connettivo sub dermico, con ottimale rapporto costi/benefici e complicanze prodotto-correlate di alcun rilievo clinico.

REFERENZE:

1. Ruiu DE. Advanced Therapies 2012; 1: 30-39
2. Falconi Klein E. Face Revitalization – Biolifting with MD-Tissue. Physiological Regulating Medicine 2012; 15-20
3. Aamodt JM, Grainger DW. Extracellular matrix-based biomaterial scaffolds and the host response. Biomaterials, 2016; 86, 68–82.
4. Rinaldi F, Pinto D, Trink A, Giuliani G, Sparavigna A. In vitro and in vivo Evaluation on the Safety and Efficacy of a Brand-New Intracutaneous Filler with α1-R-Collagen. Clin Cosmet Investig Dermatol. 2021;14:501-512. https://doi.org/10.2147/CCID.S295618
5. Gardeazabal L, Izeta A. Elastin and collagen fibres in cutaneous wound healing. Exp Dermatol. 2024;33(3):e15052. doi: 10.1111/exd.15052. PMID: 38483134.
6. Salvatore L, Natali ML, Brunetti C, Sannino A, Gallo N. An Update on the Clinical Efficacy and Safety of Collagen Injectables for Aesthetic and Regenerative Medicine Applications. Polymers. 2023; 15(4):1020. https://doi.org/10.3390/polym15041020
7. Randelli F, Menon A, Giai Via A, Mazzoleni MG, Sciancalepore F, Brioschi M, Gagliano N. Effect of a Collagen-Based Compound on Morpho-Functional Properties of Cultured Human Tenocytes. Cells. 2018; 6;7(12):246. doi: 10.3390/cells7120246.

Rehabilitacion (Madr). 2021 Sep 3; S0048-7120(21)00059-1. doi: 10.1016/j.rh.2021.04.001.
Online ahead of print.

[Efficacy of collagen infiltrations in the pelvic pain caused by episiotomy and caesarean scars. Pilot randomized clinical trial]

[Article in Spanish]

G Romero-Cullerés[1], A Amela-Arévalo[2], C Jané-Feixas[3], A Vilaseca-Grané[4], A Arnau[5], N Torà[5]

Affiliations PMID: 34489100 DOI: 10.1016/j.rh.2021.04.001

1 Servicio de Medicina Física y Rehabilitación, Althaia Xarxa Assistencial Universitària de Manresa, Manresa, Barcelona, España
2 Facultat de Ciències de la Salut, Universitat de Vic-Universitat Central de Catalunya (UVicUCC), Manresa, Barcelona, España
3 Servicio de Ginecología y Obstetricia, Hospital de Igualada, Igualada, Barcelona, España
4Servei d'Atenció a la Salut Sexual i Reproductiva (ASSIR) Bages, Centre d'Atenció Primària Bages, Manresa, Barcelona, España
5 Unitat de Recerca i Innovació, Althaia Xarxa Assistencial Universitària de Manresa, Manresa, Barcelona, España

Abstract

Background and aims: Pelvic pain is a frequently consulted symptom in pelvic floor rehabilitation units. The aim of this study was to evaluate the efficacy of collagen infiltrations in pain and the appearance of scars from perineal tears, episiotomies and caesarean sections.

Material and methods: Pilot randomized, controlled and single-blind clinical trial. Control group (CG) patients received conventional rehabilitation treatment. Additionally, those in the intervention group (IG) received 3-5 collagen infiltrations. The patients were evaluated at baseline and 6 weeks post-intervention. The main outcome was pain and it was evaluated with the Visual Analog Scale and McGill Pain Questionnaire. As secondary outcomes, the appearance of the scar was evaluated by Vancouver Scar Scale and the Patient Scar Assessment Scale. A sample of 15 women was analysed, 8 in the CG and 7 in the IG.

Results: The mean age was 33.1 years (SD 4.1). The intragroup analysis showed a significant decrease of the Visual Analog Scale punctuation and total McGill Pain Questionnaire score and the PRI-Emotional dimension of the McGill Pain Questionnaire. In the IG, a significant decrease was also observed in the PRI-Sensorial and PRI-Evaluative dimensions in comparison with baseline situation. In both groups, a significant improvement in the appearance of the scar was observed. In the intergroup analysis, a greater decrease in pain was observed in PRI-Sensorial subscale of the McGill Pain Questionnaire in the IG (-15.1 vs. -6; P=.040).

Conclusions: Collagen infiltrations may improve pain and the appearance of painful scars.

Keywords: Caesarean section; Cicatriz de cesárea; Collagen; Colágeno; Dolor pélvico; Episiotomy; Episiotomía; Infiltración; Infiltration; Pelvic pain; Rehabilitación; Rehabilitation.

Introduction

Pelvic pain (PP) is a frequent symptom of consultation in pelvic floor rehabilitation units after being treated in other services (Gynaecology, Urology, General Surgery and Digestology). It can affect more than 15% of women and only 30% of cases are attributable to gynaecological causes[1]. PP is a non-cyclic hypogastric pain that interferes with quality of life, being an important cause of discomfort, anxiety, increased visits to the doctor and surgery. It fundamentally affects women, in the absence of infectious and/or tumoral disease[2,3]. One of its causes is secondary to episiotomy or caesarean section scars. The incidence of postpartum PP due to episiotomy varies from 39% to 69%[4,5], remaining persistent in 6% to 10% at 12 months [5-7]. In caesarean sections, the frequency of immediate pain reaches 85-90% and persistent pain ranges between 8-22%[7,8]. There are different options in the therapeutic approach to painful scars: from silicone injections,

corticosteroids, subdermal procaine, immunomodulators, radiotherapy, laser therapy, cryotherapy, topical vitamin E, topical retinoid, colchicine, antihistamines or physiotherapy until surgery [9-11]. Physiotherapy treatments include ultrasound, transcutaneous nerve stimulation, as well as pelvic floor exercises and manual techniques. Massage of the scar, once the inflammatory phase has elapsed and complete repair of the dehiscence, improves flexibility and blood supply, and prevents possible adherence of the scar. [12-15]

There is little evidence of the efficacy of treatment with local infiltrations. Local collagen injections have recently been introduced. It is a health product based on purified type I collagen, together with ascorbic acid, magnesium gluconate, pyridoxine hydrochloride, riboflavin and thiamine hydrochloride. Type I collagen confers plasticity and flexibility in the final process of wound healing. The application of collagen in painful scars can confer these properties early and, therefore, reduce pain. There are different types of collagen infiltrations whose efficacy has been proven in disorders of the musculoskeletal system[16-18] such as myofascial pain syndrome[19,20] or atypical fascial neuralgia, and as a rejuvenating treatment[16]. However, its efficacy in the treatment of painful scars has not been evaluated. The aim of this study was to evaluate the efficacy of collagen injections on the pain and appearance of painful scars from perineal tears, and/or caesarean sections compared to conventional treatment with rehabilitation.

Material and methods

Design

Randomized, controlled, single-blind pilot clinical trial of patients with PP secondary to painful scars or caesarean sections. The protocol was approved by the Clinical Research Ethics Committee of the Fundació Unió Catalana d'Hospitals (code CEI17/73) and registered in clinical-trials.gov (NCT04112888). The study was conducted in accordance with current legal and regulatory requirements and following international ethical guidelines for research involving human beings. The results have been reported in accordance with the CONSORT 2010 statement.[21]

Study subjects

The study sample was obtained from patients referred between the months of April 2017 and May 2018 to the Pelvic Floor Rehabilitation consultation of our center, due to PP secondary to painful scars from both episiotomy and caesarean section. Women between 18 and 45 years old with a history of caesarean section or episiotomy delivery, with pain in the scar, who agreed to participate in the study and signed the informed consent were included. Women with PP due to other causes, mental or cognitive disorders, pregnancy, pacemaker carriers, treatment with oral anticoagulants, local infections, presence of episiotomy granuloma, total or partial denervation of the pelvic floor, and neurological diseases were excluded.

Randomization

Random assignment to the group control (CG) or intervention group (IG) was performed at the baseline visit. A list of 8 blocks with 2 patients per block was generated using a random sequence generation software (http://www.randomization.com). This process was the responsibility of the Unitat de Recerca i Innovació.

Study groups

The CG patients received conventional treatment of 8 individual rehabilitation sessions of 45 min. Two weekly sessions were scheduled for 4 weeks. The techniques of massage therapy, muscle stretching, fascia work were performed by the same physiotherapist specialized in pelvic floor. Scar massage therapy is a massage that consists of moving the tissues in all directions. Longitudinal and circular movements were made to release the tension, horizontal and vertical zigzag movements forming an «S», small pinches lifting the skin around the scar and, finally, rolling. Myofascial work consists of the relaxation of the fasciae to treat soft tissues that have suffered trauma, such as a scar. Work was done at the level of deep planes by means of

crossed hands/fingers or by placing one hand on top of the lesion and the other at the level of the sacrum, seeking restriction and causing sliding to improve mobility. Iliac psoas, piriformis, gluteal and hamstring stretches were performed. IG patients received the same rehabilitation treatment as CG patients. Additionally, IG patients received 3 (in case of episiotomy) to 5 (in case of caesarean section) injections of MD-Tissue® collagen into the scar once a week. Infiltrations of 2 ml (one vial) of collagen were performed in the episiotomy scars and 4 ml (2 vials) in the caesarean scars. Based on clinical criteria, it was decided to perform 3 to 5 infiltrations, which is the minimum number of infiltrations in order to be able to objectify clinical responses, performing more infiltrations and larger volumes in caesarean sections as they are larger. The rehabilitation doctor performed the intradermal infiltration using the tunnelling technique.

Procedure

The baseline assessment was carried out by the rehabilitation doctor. The demographic and clinical information of the patient (age, pathological and gynaecological-obstetric history) was collected, a basic examination of the pelvic floor was performed, evaluating the capacity for voluntary vaginal contraction (modified Oxford scale) and the areas to be infiltrated were located. For the subjective assessment of pain, the visual analogue scale (VAS)[22] and the McGill Pain Questionnaire (MPQ, «McGill pain questionnaire»[23]) validated in Spanish by Lázaro *et al.*[24] were used. To assess the appearance of the scar, the rehabilitation physician used the Vancouver Scar Scale (VSS) and the patient used the Patient Component of the Patient Scar Assessment Scale (PSAS) of the Patient and Observer Objective Assessment Scale.[25,26] An initial photograph of the scar was taken. Patients were reassessed 6 weeks postoperatively by a midwife blinded to group assignment. Information was collected through the VAS, the MPQ, the VSS and the PSAS, adding the subjective perception of scar improvement using the clinician's (CGI-I) and patient's (PGI-I) global impression scales.[27,28] A new photograph of the scar was taken to compare it with the baseline. Initially, 30 patients were evaluated for eligibility, of which 14 (46.7%) were excluded. Of the remaining 16, 8 were assigned to the CG and 8 to the IG. One patient moved from home before the post-intervention visit, so finally 8 in the CG and 7 in the IG were analysed (Fig. 1).

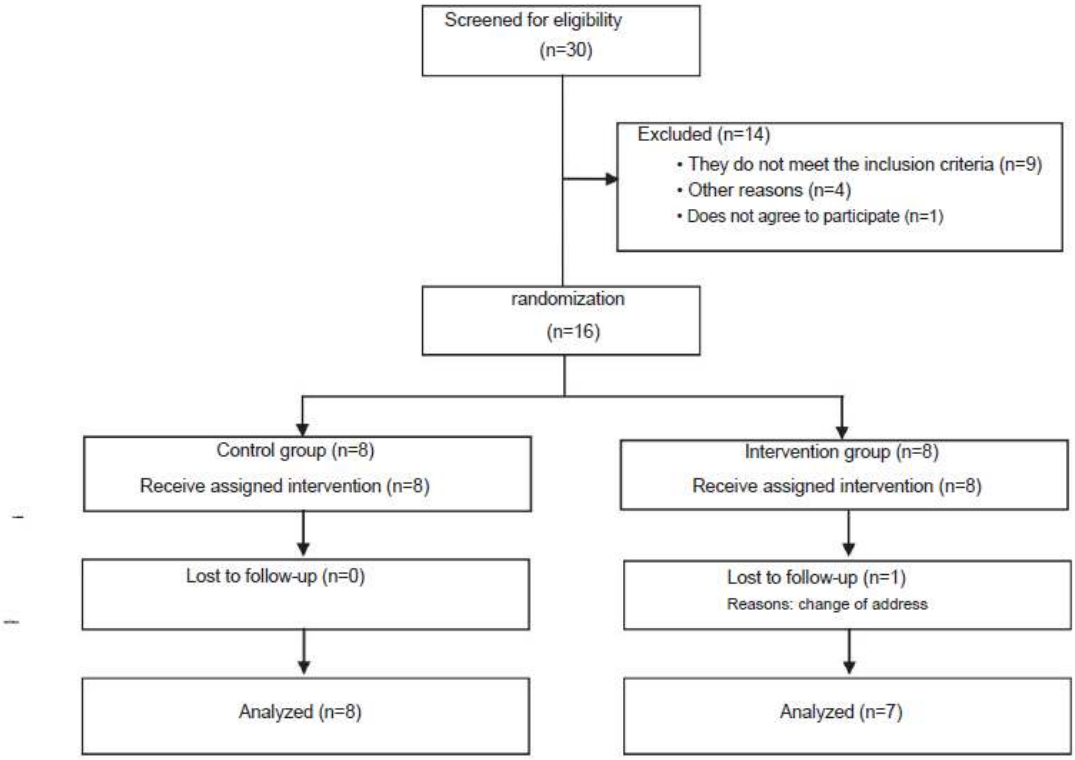

Figure 1 Flow chart.

Primary and Secondary Dependent Variables

The primary dependent variable was pelvic scar pain according to VAS and MPQ. The VAS makes it possible to measure the intensity of pain, which is described by a 10-cm horizontal line whose ends are the extreme expressions of pain. Score from 0-10. The MPQ is made up of 64 descriptors distributed in 19 subclasses (12 sensory, 3 miscellaneous-sensory, 3 emotional and an evaluative). Each of the descriptive terms is assigned a number or range that allows a score to be obtained according to the words chosen, thus obtaining the Pain Rating Index (PRI). Likewise, it allows assessing qualitative and quantitative characteristics of the pain experience by dividing the global results into three subscales: PRI-Sensory (12 subclasses), PRI-Emotional (3 subclasses) and PRI-Appreciative (1 subclass). As secondary dependent variables the appearance of the scar and the CGI-I and PGI-I were evaluated. VSS and PSAS were used to assess the appearance of the scar. The VSS evaluates 4 characteristics of the scar, such as pigmentation, vascularity, flexibility and height. The score range is between 0 and 10; the higher the score, the worse the healing. The PSAS allows to evaluate, on a numerical measure and subjectively, the symptoms related to pain, itching, colour, stiffness, thickness and relief. Each of the 6 questions has a value from 1 to 10, with a score of 10 being the worst scar imaginable or the worst feeling, and a score of 1 being normal skin. For the assessment of the global improvement after the intervention, the PGI-I scale was used, which describes the patient's perception of improvement between the categories of: much better, much better, a little better, no change, a slightly worse, much worse and much worse. The CGI-I describes the perception of improvement by the physician responsible for the treatment between the categories of: much better, better, no change, worse and much worse.

Statistical analysis

Continuous variables are summarized with the mean and standard deviation. Categorical variables are expressed in absolute value and relative frequencies. For the analysis of homogeneity of the baseline characteristics of both groups, the Student's t test was used to compare means with a normal distribution, and the Mann-Whitney U test for variables with a non-normal distribution. Fisher's exact test or Monte

Carlo's exact method was used for the comparison of proportions. For the efficacy analysis, the difference between the value obtained in the post-intervention assessment (6 weeks) and the baseline value of the main and secondary dependent variables was calculated for each one of the groups, together with its 95% confidence interval. Student's t test was used to compare the difference in means with normal distribution and the Mann-Whitney U test for variables with non-normal distribution. Cohen's d was calculated as a measure of effect size. A value ≤ 0.2 is considered a small effect, a d around 0.5 as a moderate effect and a d ≥ 0.8 as a large effect. For the comparison of the impression scales of global improvement post-intervention between the CG and IG used the exact Montecarlo method. The level of statistical significance used was 5% bilateral ($p < 0.05$). Data was analysed using IBM®SPSS®Statistics for Windows version 25 (IBM Corp, Armonk, New York, USA) and R® version 3.3.2 (R Foundation for Statistical Computing, Vienna, Austria).

Results

Baseline characteristics (Table 1) were similar in both groups, with a mean age of 33.1 (SD 4 ,1). The proportion of caesarean sections was higher in the CG than in the IG (50.0 vs. 28.6%; $p = 0.608$). The subjective perception of baseline pain according to the VAS was higher in the CG than in the IG (7.5 vs. 5.7; $p = 0.021$). Table 2 shows the differences in the means between the post-intervention assessment and the baseline for each one of the groups. In the intragroup analysis, a significant decrease in pain (VAS, MPQ, PRI-Emotional) and a significant improvement in wound healing (VSS) were observed in both groups. In the IG, a significant decrease was also observed in the PRI-Sensory and the PRI-Value. In the intergroup analysis, a statistically significant difference was observed in the PRI-Sensory subscale ($p = 0.040$). The decrease in the PRI-Sensory score was higher in the IG compared to the CG: −15.1 (−22.2 to −8.1) vs. −6 (−12.6 to 0.6). No significant differences were observed in the rest of the scales. However, despite the fact that a significant decrease in pain was observed in both groups according to the overall score obtained on the MPQ, this was higher in the IG (Cohen's $d = −1.02$). The decrease in the MPQ score in the IG was −17.4 (−25 to −9.9) vs. −8.4 (−16.3 to −0.4) of the CG. Table 3 shows the PGI-I and the CGI-I after the intervention according to the study group. The proportion of patients who scored much or very much better was lower in the CG than in the IG (50.0 vs. 71.5%; $p = 0.814$). The clinician rated 87.7% of the patients in the CG and 100% of those in the IG as much or very much better ($p = 1.000$). None of the patients presented complications or adverse reactions due to infiltrations.

Table 1 Baseline characteristics

	Control n = 8	Intervention n = 7	p
Age (years), "mean (SD)	34,5 (3,7)	31,4 (4,1)	0,152
Primiparous, n (%)			
No	7 (87,5) 1	7 (100,0) 0	1,000
Yes	(12,5)	(0,0)	
Birth rate, n (%)			
Vaginal	4 (50,0) 4	5 (71,4) 2	0,608
Caesarean section	(50,0)	(28,6)	
Instrumental, n (%)			
No	1 (25,0) 3	2 (40,0) 3	1,000
Yes	(75,0)	(60,0)	
Oxforda, n (%)			
0 a 2	2 (50,0) 2	3 (60,0) 2	1,000
3 a 5	(50,0)	(40,0)	
Pain in relationships, n (%)			
No	4 (50,0) 4	2 (28,6) 4	0,608
Yes	(50,0) 0	(57,1)	
not relations	(0,0)	1 (14,3)	
Pelvic pain, mean (SD)			
EVA	7,5 (0,9)	5,7 (1,4)	**0,021**
McGill Pain Questionnaire	28,9 (8,0)	31,1 (4,8)	0,525
PRI-Sensorial	23,6 (8,3)	26,1 (2,5)	0,456
PRI-Emotional	2,5 (1,7) 2,8	2,7 (2,1) 2,3	0,867
PRI-Valuation	(1,2)	(0,5)	0,463
Lesion appearance, mean (SD)			
Vancouver Scar Scale	5,5 (1,9)	4,6 (1,9)	0,356
Patient Scar Assessment Scale	34,0 (9,9)	25,4 (11,2)	0,109

The data highlighted in bold corresponds to a statistically significant difference
SD: standard deviation; VAS: visual analog scale; PRI: *Pain Rating Index*. a In case of vaginal delivery.

Discussion a significant decrease in the global assessment of the pain of the pelvic scars and an improvement in the healing of the lesion. The decrease in pelvic scar pain in the PRI-Sensory subscale was significantly greater in the IG patients.

Pain intensity scales are capable of determining changes in the same patient over time, but they have little ability to compare between subjects[29]. The VAS of pain is not very sensitive in the assessment and description of pain, the MPQ being more specific in this case in the evaluation of improvement in pain. The use of more specific scales/questionnaires can help us in the assessment of patients with any type of pain[30] The PP of perineal tear scars, episiotomies and/or caesarean sections is a frequently underdiagnosed and undertreated condition. A greater awareness of health professionals is required so that they ask about and assess the pain

Table 2 Primary and secondary dependent variables at baseline and post-intervention

	Basal, media (DE)		Post-intervention, mean (SD)		Differences between postintervention and baseline [95% CI]a		p*	d of Cohen
	Control n = 8	Intervention n = 7	Control n = 8	Intervention n = 7	Control n = 8	Intervention n = 7		
EVA	7,5 (0,9)	5,7 (1,4)	4,0 (3,1)	2,1 (2,4)	−3,5 [−6,3 a −0,7]	−3,6 [−6,3 a −0,9]	0,966	−0,02
McGill Pain Questionnaire	28,9 (8,0)	31,1 (4,8)	20,5 (15,4)	13,7 (8,9)	−8,4 [−16,3 a −0,4]	−17,4 [−25 a −9,9]	0,071	−1,02
PRI-Sensorial	23,6 (8,3)	26,1 (2,5)	17,6 (13,8)	11,0 (7,7)	−6 [−12,6 a 0,6]	−15,1 [−22,2 a −8,1]	0,040	−1,18
PRI-Emotional	2,5 (1,7)	2,7 (2,1)	1,1 (1,0)	1,1 (1,3)	−1,4 [−2,7 a −0,04]	−1,6 [−3,1 a −0,1]	0,817	−0,12
PRI-Valuation	2,8 (1,2)	2,3 (0,5)	1,8 (0,9)	1,6 (0,5)	−1 [−2,3 a 0,3]	−0,7 [−1,2 a −0,3]	1,000	0,25
Vancouver Scar Scale	5,5 (1,9)	4,6 (1,9)	3,4 (2,9)	1,7 (2,0)	−2,1 [−4 a −0,2]	−2,9 [−4,7 a −1,1]	0,613	−0,34
Patient Scar Assessment Scale	34,8 (9,9)	25,4 (11,2)	23,1 (18,3)	13,1 (16,1)	−11,6 [−25,4 a 2,2]	−12,3 [−26,6 a 2]	0,938	−0,04

Data highlighted in bold correspond to statistically significant differences
SD: standard deviation; VAS: visual analog scale; 95% CI: 95% confidence interval; PRI: *Pain Rating Index*.
a Difference of intragroup means together with their 95% confidence interval.
* p of the contrast of the intergroup mean difference.

Table 3 Impression scales of global improvement of postoperative patient / clinician

	Control n = 8	Intervention n = 7	p
PGI I			
Much Much better	2 (25,0)	2 (28,6)	0,814
Better	2 (25,0)	3 (42,9)	
A bit better	4 (50,0)	2 (28,6)	
CGI-I			
Much better	3 (37,5)	3 (42,9)	1,000
Better	4 (50,0)	4 (57,1)	
No change	1 (12,5)	0 (0,0)	

CGI-I: Clinician's Global Impression of Improvement Scale; PGI-I: impression scale of global improvement of the patient.

caused by these scars in women who have recently given birth, since a delay in diagnosis can cause a chronification of this pain and the consequent central sensitization, dificultivating the treatment and reducing the effectiveness of actions at the local level. This pilot study has shown a greater reduction in pelvic scar pain in temporal-spatial terms (PRI-Sensory subscale) in the IG. A large effect is also observed in the global MPQ score in favour of the IG, although the difference is not statistically significant, possibly due to the lack of statistical power as it is a pilot study with a small sample of patients. This small sample is clearly a limitation of the study, as well as the fact that it was not possible to carry out a blinded study. The fact that the intervention was not masked, and that the patient was aware of the group to which she was assigned could have led to a problem of social desirability in her responses so that they were seen as favourable by the health professional. As a pilot study, it was decided to compare with the Rehabilitation treatment commonly used without carrying out an infiltration with saline solution as a placebo or compared with other infiltrated treatments (glucocorticoids, local anaesthetics), thus being able to be carried out in future lines of research. The results obtained point to a new line of treatment for the approach of these scars and an unknown use of type I collagen. To date, there is no previous evidence of the use of collagen in painful scars, but more studies are required to establish the line of treatment in which the use of collagen can be placed. Double-blind comparative studies with placebo in which physiological saline is infiltrated, and comparative studies with other types of interventions such as infiltrations with substances such as glucocorticoids or local anaesthetics, are required. In addition, specific studies are required to determine the amount of collagen and the number of infiltrations that would be most appropriate for each type of scar, the effect depending on the time of evolution of the scar. Likewise, it is necessary to know the long-term efficacy of collagen infiltrations in the evolution of the appearance of scars in case repetition of these infiltrations is necessary.

Conclusions

Collagen infiltrations could improve PP in painful scars and their appearance in comparison with conventional rehabilitation treatment. Further studies are required to establish its efficacy and cost-effectiveness and its role in the routine treatment of painful scars.

Conflict of interest

The investigators of this study did not receive any type of financial compensation for conducting the study. The Oyasama laboratory provided the MD-Tissue® collagen vials used free of charge.

Bibliography

1. Romero Cullerés C, Tejero Sánchez M, Moreno Atanasio E. Definición. Epidemiología y fisiopatología del dolor pélvico crónico. Dolor. 2017;32:45–54.
2. López González PA, Tornero Ruiz JI, Cubillana PL, Iñiguez GD, Ruiz Morcillo JC, Albacete MP. Alternativa terapéutica para el dolor pélvico crónico de origen vesical. Actas Urol Esp. 2009;33:681–5, http://dx.doi.org/10.1016/s0210-4806(09)74207-x.
3. Reiter RC. A profile of women with chronic pelvic pain. Clin Obstet Gynecol. 1990;33:130–6.
4. Islam A, Hanif A, Ehsan A, Arif S, Niazi SK, Niazi AK. Morbidity from episiotomy. J Pak Med Assoc. 2013;63:696–701.
5. Schinkel N, Colbus L, Monrigal C, Granry JC. ATS14 - Prise en charge des douleurs périnéales postépisiotomies. Douleurs: Évaluation - Diagnostic - Traitement. 2006;7:63–4, http://dx.doi.org/10.1016/s1624-5687(06)77828-3.
6. Åhlund S, Rådestad I, Zwedberg S, Lindgren H. Perineal pain the first year after childbirth and uptake of post-partum check-up - A Swedish cohort study. Midwifery. 2019;78:85–90, http://dx.doi.org/10.1016/j.midw.2019.08.004.
7. Kainu JP, Halmesmäki E, Korttila KT, Sarvela PJ. Persistent pain after cesarean delivery and vaginal delivery: A prospective cohort study. Anesth Analg. 2016;123:1535–45, http://dx.doi.org/10.1213/ANE.0000000000001619.
8. Lavand'Homme P. Postoperative cesarean pain: Real but is it preventable? Curr Opin Anaesthesiol. 2018;31:262–7, http://dx.doi.org/10.1097/ACO.0000000000000585.
9. Vall-Toscas C, Sardá-Barea E, Martínez-Bueno C, Zaragoza-Marfá A. Dolor persistente posparto. Tratamiento con procaína subdérmica (terapia neural). Matronas Prof. 2016;17:143–8.
10. Herranz P, Santos Heredero X. Cicatrices, guía de valoración y tratamiento. Madrid: Meda Pharma; 2012. M-41381-2012.
11. Lucha Fernández V, Muñoz Mañez V, Fornes Pujalte B, García Garcerá M. La cicatrización de las heridas. Enfermería Dermatológica. 2008:8–15, http://dx.doi.org/10.1016/B978-84-9022-065-8/00007-6.
12. Rosenbaum TY, Owens A. The role of pelvic floor physical therapy in the treatment of pelvic and genital pain-related sexual dysfunction. J Sex Med. 2008;5:513–23, http://dx.doi.org/10.1111/j.1743-6109.2007.00761.x.
13. Itza F, Zarza D, Serra L, Gómez-Sancha F, Salinas J, Allona-Almagro A. Síndrome de dolor miofascial del suelo pélvico: una patología urológica muy frecuente. Actas Urol Esp. 2010;4:318–26, http://dx.doi.org/10.1016/j.acuro.2009.12.013.
14. Fernández Medina IM. Abordaje fisioterápico de las lesiones perineales en el posparto. Enfermería Docente. 2013;100:28–33, http://www.juntadeandalucia.es/servicioandaluzdesalud/huvvsites/default/files/revistas/ED-100-08.pdf.
15. Montes Posada I, Gutiérrez González J, Gil Fraguas ML, Romero Culleres G. Tratamiento del dolor pélvico crónico. Papel de las unidades de rehabilitación del suelo pélvico. Dolor. 2017;32:65–74.
16. Milani L. A new and refined injectable treatment for musculoskeletal disorders – bioscaffold properties of collagen and its clinical use and action. Physiol Regul Med. 2010:3–15.
17. Milani L. The collagen medical devices in the local treatment of the algic arthro-rheumopathies – Review of the clinical studies and clinical assessments 2010-2012. Physiol Regul Med. 2013:21–36.
18. Nitecka-Buchta A, Walczynska-Dragon K, Batko-Kapustecka J, Wieckiewicz M. Comparison between collagen and lidocaine intramuscular injections in terms of their efficiency in decreasing myofascial pain within masseter muscles: A randomized, single-blind controlled trial. Pain Res Manag. 2018;2018, http://dx.doi.org/10.1155/2018/8261090, 8261090.
19. Shah JP, Thaker N. Myofascial pain syndrome. En: Cheng J, Rosenquist RW, editores. Fundamental of pain medicine. Cham: Springer International Publishing; 2018. p. 177–84, http://dx.doi.org/10.1007/978-3-319-64922-1_19.
20. Martin Martin LS, Massafra U, Bizzi E, Migliore A. A double blind randomized active-controlled clinical trial on the intra-articular use of Md-Knee versus sodium hyaluronate in patients with knee osteoarthritis (''Joint''). BMC Musculoskelet Disord. 2016;17:94948, http://dx.doi.org/10.1186/s12891-016-0948-4.
21. Schulz KF, Altman DC, Moher D. CONSORT 2010 statement: Updated guidelines for reporting parallel group randomised trials. Ann Intern Med. 2010;152:726–32, http://dx.doi.org/10.7326/0003-4819-152-11-201006010-00232.
22. Huskisson EC. Measurement of pain. Lancet. 1974;9;2(7889):1127–31. https://doi.org/10.1016/s0140-6736(74)90884-8.
23. Ruiz-Lopez R, Ferrer I, Pagerols M. The Spanish pain questionnaire. Pain. 1990;41 Suppl 1:S304, http://dx.doi.org/10.1016/0304-3959(90)92723-4.
24. Lázaro C, Bosch F, Torrubia R, Baños JE. The development of a Spanish questionnaire for assessing pain: Preliminary data concerning reliability and validity. Eur J Psychol Assess. 1994;10:145–51.
25. Chae JK, Kim JH, Kim EJ, Park K. Values of a patient and observer scar assessment scale to evaluate the facial skin graft scar. Ann Dermatol. 2016;28:615–23, http://dx.doi.org/10.5021/ad.2016.28.5.615.
26. Draaijers LJ, Tempelman FRH, Botman YAM, Tuinebreijer WE, Middelkoop E, Kreis RW, et al. The patient and observer scar assessment scale: A reliable and feasible tool for scar evaluation. Plast Reconstr Surg. 2004;113:1960–5, http://dx.doi.org/10.1097/01.PRS.0000122207.28773.56.
27. Guy W, ed. ECDEU Assessment manual for psychopharmacology. Rockville, MD: US Department of Heath, Education, and Welfare Public Health Service Alcohol, Drug Abuse, and Mental Health Administration; 1976.
28. Romero Maroto J, Ortiz Gorraiz M, Prieto Chaparro L, Pacheco Bru JJ, Miralles Bueno JJ, Lopez Lopez C. Transvaginal adjustable tape: An adjustable mesh for surgical treatment of female stress urinary incontinence. Int Urogynecol J Pelvic Floor Dysfunct. 2008;19:1109–16, http://dx.doi.org/10.1007/s00192-008-0590-2.
29. Dunn DK, Jannetta PJ. Evaluation of chronic pain in children. Curr Probl Surg. 1973:64–72.
30. Serrano-Atero MS, Caballero J, Cañas A, García-Saura PL, Serrano-Álvarez C, Prieto J. Valoración del dolor (II). Rev Soc Esp Dolor. 2002;9:109–21.

Healthspan versus Lifespan
Il ruolo della Medicina Estetica

SIME 2025 | 46° CONGRESSO SIME Società Italiana di Medicina Estetica | 20° CONGRESSO AIMAA Accademia Italiana di Medicina Anti-Aging

16, 17, 18 MAGGIO
Roma Convention Center La Nuvola

COLLAGENE SUINO DI TIPO I AD USO INIETTIVO SOTTOCUTANEO NEL TRATTAMENTO DI CICATRICE CHIRURGICA MAMMARIA COMPLICATA

Dott.ssa Liliana Sgarbi, *Direttore UOC Riabilitazione Specialistica Presidio Fatebenefratelli Milano*

Ospedale Fatebenefratelli e Oftalmico
Sistema Socio Sanitario Regione Lombardia
ASST Fatebenefratelli Sacco

INTRODUZIONE:

Nelle ferite chirurgiche che guariscono per seconda intenzione, la risposta infiammatoria e la produzione di tessuto di granulazione sono più rilevanti rispetto alla guarigione per prima intenzione. La produzione di tessuto connettivo risulta più cospicua ma le fibre collageniche presentano scarso allineamento.
Una organizzazione disordinata del tessuto cicatriziale può essere causa di danni estetici e/o funzionali.
L'utilizzo di dispositivi medici a base di collagene di tipo I nel trattamento di cicatrici permette di fornire substrato, alla matrice extracellulare, di migliorare la capacità contrattile e quindi produttiva deifibroblasti e ottimizzare l'assetto delle fibre collagene prodotte.

CASO CLINICO:

Paziente di anni 44, affetta da carcinoma mammario. Sottoposta a quadrantectomia mammaria con dissezione ascellare. Intervento complicato da ascesso mammario sottocicatriziale, drenato con successiva guarigione per seconda intenzione.

ESAME OBIETTIVO:

Cicatrice chirurgica arrossata, discromica; adesa ai piani sottostanti; depressa nella porzione centrale con cordoncino ipertrofico longitudinale (punteggio 9 scala Vancuver).

MATERIALI E METODI:

Trattamento mesoterapico iniettivo sottocute con collagene MD-TISSUE GUNA eseguito ogni 7 giorni per complessivamente 5 sedute.
Follow up a 3 e 10 giorni dal termine del trattamento.
Somministrata la scala Vancuver prima del trattamento e nei follow up.

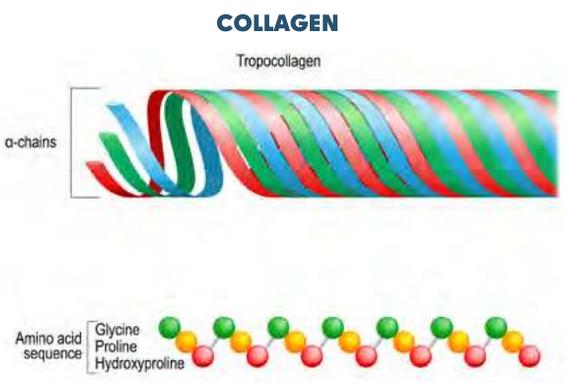

RISULTATI:

Esame obiettivo nei follow up: maggiore omogeneità della pigmentazione e una schiaritura della colorazione. Risoluzione dell'aderenza ai piani sottostanti nella porzione centrale della cicatrice (punteggio 4 scala Vancuver).

CONCLUSIONI:

L'utilizzo di questo dispositivo medico è una opzione terapeutica innovativa, scarsamente invasiva e con favorevole rapporto costo-beneficio. Tuttavia, servono ulteriori evidenze scientifiche a supporto.

REFERENZE:

1. Randelli F, Menon A, Giai Via A, et al, Effect of a Collagen-Based Compound on Morpho-Functional Properties of Cultured Human Tenocytes. Cells. 2018 Dec 6;7(12):246.
2. Randelli F, Sartori P, Carlomagno C, Bedoni M, Menon A, Vezzoli E, et al. The Collagen-Based Medical Device MD-Tissue Acts as a Mechanical Scaffold Influencing Morpho-Functional Properties of Cultured Human Tenocytes. Cells. 2020 Dec 8;9(12):264
3. Cotran RS, Kumar V, Collins T (2000) Robbins. Le basi patologiche delle malattie. Piccin editore
4. Lin-Hui L, Yuan-Yuan Z, Ming-Yu L, Xu-Dong H, Yin-Jia D, Yue Z, Yang-Hong-Hong F, Ai-Fen C, Xu-Dong Z, Zheng-Li C, Jian J. Recombinant Human Collagen Type III Improves Hypertrophic Scarring by Regulating the Ratio of Type I/III Collagen. J Burn Care Res. 2024 Sep 6;45(5):1269-1273
5. Gardeazabal L, Izeta A. Elastin and collagen fibres in cutaneous wound healing. Exp Dermatol. 2024 Mar;33(3):e15052.

TRATTAMENTO CON COLLAGENE INFILTRATIVO SUINO IN ESITI CICATRIZIALI POST ACNE ADOLESCENZIALE

D.ssa Arianna Squillante, *Centro Medico Eden Siracusa*

OBIETTIVI:

L'acne è una dermatosi cronica prevalente durante l'adolescenza con una buona percentuale significativa di casi che evolvono in cicatrici permanenti. Le cicatrici atrofiche derivano da una inadeguata produzione di collagene durante i processi di guarigione e rispondono bene a trattamenti di tipo rigenerativo come collagene, microneedling, PRP, Laser.
Le cicatrici post-acne nei giovani hanno un impatto significativo sull'autostima e qualità della vita.
Il collagene permette di ottenere un effetto di rimodellamento del tessuto fibrotico, andando a stimolare i fibroblasti e una neocollagenesi (collagene di tipo I va a sostituire il collagene di tipo III che conduce ad esiti cicatriziali).
In questo case series si è voluto valutare l'efficacia e la tollerabilità del collagene infiltrativo suino nel miglioramento degli esiti cicatriziali post-acne in soggetti adolescenti.
L'utilizzo del dispositivo medico MD-TISSUE a base di collagene suino rappresenta una opzione terapeutica innovativa ed efficace nel trattare queste cicatrici che possono lasciare aree profonde e depresse se non adeguatamente gestite.

MATERIALI E METODI:

5 pazienti (2 di 15 aa, 1 di 16 aa 2 di 17 aa) presentatavano cicatrici post-acne e sono stati sottoposti a ciclo infiltrativo in corrispondenza delle lesioni cicatriziali con tecnica mesoterapica a ventaglio sotto la cicatrice e puntiforme al centro della cicatrice.
E' stato eseguito un ciclo da 5 infiltrazioni, 1 a settimana per 5 settimane, utilizzando ago 13 mm e 30 G, 2 vials, (4 ml) di collagene suino.
E' stata effettuata valutazione clinica e fotografica includendo anche una scala di soddisfazione.
Si è associata terapia orale con Dermoguna compresse ed una terapia topica con Dermoguna siero per conferire maggiore levigatezza ed elasticità ai tessuti, oltre che prolungarne l'effetto.

RISULTATI:

I pazienti hanno mostrato un miglioramento significativo, documentato da immagini pre e post trattamento, sia nella profondità che nell'aspetto delle cicatrici. Si è ottenuto un buon risultato sulla distensione della cicatrice, grazie all'azione riparativa e biorigenerativa del collagene nel rispetto e uniformità della texture cutanea.
La valutazione dell'efficacia è stata effettuata mediante scale che misurano il grado di soddisfazione e miglioramento estetico dei pazienti (scala da 0 a 10; risultato 9) e anche da parte del medico e dei genitori si è apprezzato tale risultato.
Non si è riscontrata alcuna reazione allergica o fastidio durante e post trattamento.

PRE TRATTAMENTO

POST TRATTAMENTO

CONCLUSIONI:

L'infiltrazione del dispositivo medico classe III, a base di collagene suino ed eccipienti a base di vitamine C, B1, B2, B6 e gluconato di magnesio ad azione anti ossidante, rappresenta una terapia efficace e sicura per il trattamento delle cicatrici post-acne in adolescenti.
Questo dispositivo si è rivelato essere un'opzione terapeutica bioristrutturante e biorivivitalizzaante capace di stimolare il rimodellamento dermico grazie alla neocollagenesi e al supporto strutturale.

BIBLIOGRAFIA:

1. Randelli F, Sartori P, Carlomagno C, Bedoni M, Menon A, Vezzoli E, et al. The Collagen-Based Medical Device MD-Tissue Acts as a Mechanical Scaffold Influencing Morpho-Functional Properties of Cultured Human Tenocytes. Cells. 2020 Dec 8;9(12):2641.
2. Randelli F, Menon A, Giai Via A, et al, Effect of a Collagen-Based Compound on Morpho-Functional Properties of Cultured Human Tenocytes. Cells. 2018 Dec 6;7(12):246.
3. Vasam M, Korutla S, Bohara RA. Acne vulgaris: A review of the pathophysiology, treatment, and recent nanotechnology based advances. Biochem Biophys Rep. 2023 Nov 23;36:101578.

TRATTAMENTO DELLE OCCHIAIE CON COLLAGENE INFILTRATIVO SUINO: APPROCCIO RIGENERATIVO PER UNA ZONA PERIORBITALE PIÙ GIOVANE E LUMINOSA

D.ssa Arianna Squillante, *Centro Medico Eden Siracusa*

OBIETTIVI:

Le occhiaie (iperpigmentazione infraorbitale o dark circles) rappresentano un inestetismo comune della regione periorbitale inferiore, presente sia in soggetti giovani che adulti. Clinicamente si distinguono diverse tipologie di occhiaie: pigmentate, vascolari, strutturali e miste con eziopatogenesi multifattoriale. Il trattamento delle occhiaie è complesso e richiede approcci personalizzati e multifunzionali.
In questo case series abbiamo valutato un protocollo rigenerativo non invasivo (con dispositivo medico a base di collagene suino ed eccipienti come acido citrico e nicotinamide) infiltrato su una serie di pazienti con tecnica a ventaglio.
Il collagene grazie al suo effetto rigenerativo e biostimolante, sulla zona periorbitale, promuove dei buoni risultati per una pelle più luminosa ed elastica.

MATERIALI E METODI:

10 pazienti (4 paz di 40 aa, 2 di 35 aa, 3 paz di 25 aa, 1 paz di 60 aa) , sono stati sottoposti ad un ciclo di 5 infiltrazioni con 2 vials (4 ml) di collagene suino + acido citrico e nicotinamide, mediante tecnica sia ventaglio che a caduta (seguendo il profilo del canto osseo), a cadenza settimanale, utilizzando ago 13 mm e 30 gauche.
Si associa terapia topica con Dermoguna siero e Arnica durante e dopo il trattamento.
La valutazione dei risultati era stata fatta mediante immagine fotografica prima e dopo il trattamento; scala soggettiva di soddisfazione del paziente e del medico prima e dopo trattamento.

PRE TRATTAMENTO

POST TRATTAMENTO

POST TRATTAMENTO

RISULTATI:

Il trattamento delle occhiaie, mediante questa metodica infiltrativa e grazie alle proprietà del collagene come biostimolante, ha permesso di avere un miglioramento tissutale a fine trattamento.
Questo soprattutto nei casi di occhiaie strutturali associate a svuotamento del solco lacrimale, con un effetto coprente sulle occhiaie pigmentate e alta tollerabilità da parte dei pazienti.
Lievi arrossamenti o gonfiori post-trattamento sono stati solo transitori.

CONCLUSIONI:

L'utilizzo infiltrativo del dispositivo medico in classe III a base di collagene suino ed eccipienti come acido citrico e nicotinamide rappresenta un'opzione terapeutica promettente e sicura nel trattamento di occhiaie dovute a perdita di volume e la terapia topica associata con siero è stata utile a supportare anche le forme pigmentarie.

BIBLIOGRAFIA:

1. Randelli F, Menon A, Giai Via A, et al, Effect of a Collagen-Based Compound on Morpho-Functional Properties of Cultured Human Tenocytes. Cells. 2018 Dec 6;7(12):246.
2. Zhao R, Qiu H, Liu S, Cao L, Yu D, Wang H. Quantifiable clinical efficacy of injectable porcine collagen for the treatment of structural dark circles. J Cosmet Dermatol. 2021 May;20(5):1520-1528.
3. Michelle, Lauren BA*,†; Pouldar Foulad, Delila MD*; Ekelem, Chloe MD*; Saedi, Nazanin MD‡; Mesinkovska, Natasha Atanaskova MD, PhD*. Treatments of Periorbital Hyperpigmentation: A Systematic Review. Dermatologic Surgery 47(1):p 70-74, January 2021.

BIOSTIMOLAZIONE E BIORISTRUTTURAZIONE DERMICA CON COLLAGENE PORCINO NELL'INVECCHIAMENTO CUTANEO

Dott. Andrea Turchi, *Medico Estetico*

DOTT. ANDREA TURCHI
MEDICINA ESTETICA FUNZIONALE

OBIETTIVI:

L'invecchiamento cutaneo è un fenomeno biologico involutivo complesso che interessa la cute e principalmente la Matrice Extra Cellulare (ECM).
L'ECM è una rete dinamica tridimensionale di macromolecole che fornisce supporto strutturale alle cellule e ai tessuti. Le evidenze scientifiche dell'ultimo decennio hanno chiaramente dimostrato che l'ECM svolge ruoli regolatori importanti poiché permette la comunicazione tra cellule, le loro funzioni, proprietà e morfologia.
L'invecchiamento cutaneo crono e foto indotto ha inizio con una riduzione e naturale degradazione del collagene a partire dai 35 anni in su. Il collagene perde il suo allineamento e non supporta più l'adesione dei fibroblasti, che si trasformano in cellule senescenti. Motivo per cui un approccio infiltrativo a base di collagene suino può rivelarsi una terapia efficace.
Al fine di valutare l'effetto della biostimolazione del collagene porcino nei pazienti over 35 anni arrivati alla mia attenzione, sono stati selezionate 10 pz di età tra i 35 e i 55 aa.

MATERIALI E METODI:

10 pazienti sono state sottoposte ad infiltrazione di collagene suino 2 ml (MD-TISSUE), a livello intradermico, nel viso, collo e nella zona perioculare inferiore, per complessivi 4 trattamenti a cadenza bisettimanale. Il 70% delle pazienti ha avuto un netto miglioramento funzionale dell'area trattata.

Il grado di soddisfazione delle pazienti è stato valutato da scale di miglioramento estetico e immagine fotografica prima e dopo trattamento.

RISULTATI:

La bioristrutturazione dermica attraverso l'uso del collagene MD-TISSUE ha migliorato l'aspetto esteriore della pelle e la plasticità della matrice extracellulare.

Nei pazienti con presenza di rughe si è avuto un miglioramento dell'aspetto della ruga con visibile distensione del tessuto che ne ha migliorato tono ed elasticità.

PRE TRATTAMENTO | POST TRATTAMENTO

CONCLUSIONI:

L'uso del dispositivo medico a base di collagene suino permette di raggiungere aspetti naturali andando ad agire sulla biostimolazione, neosintesi di nuovo collagene, miglioramento del tono ed elasticità dei tessuti, che dai 30 anni in avanti perdono lucentezza, tono e volume soprattutto in aree del viso collo.

BIBLIOGRAFIA:

1. Salvatore L, Natali ML, Brunetti C, Sannino A, Gallo N. An Update on the Clinical Efficacy and Safety of Collagen Injectables for Aesthetic and Regenerative MedicineApplications. Polymers. 2023; 15(4):1020.

2. Randelli F, Menon A, Giai Via A, et al, Effect of a Collagen-Based Compound on Morpho-Functional Properties of Cultured Human Tenocytes. Cells. 2018 Dec 6;7(12):246.

EFFICACIA DELLA BIOSTIMOLAZIONE CON COLLAGENE INIETTIVO SUINO NEL TRATTAMENTO DELLE OCCHIAIE PERIOCULARI

Dott. Andrea Turchi, *Medico Estetico*

OBIETTIVI:

Le occhiaie possono avere cause genetiche, vascolari o esser determinate da stress ossidativo o foto esposizione. Sono caratterizzate da un'area scura, infossata e, talvolta, gonfia sotto gli occhi.
Le occhiaie sono classificate in pigmentarie (di colore marrone, date da accumulo di melanina), vascolari (di colore blu-violaceo date da visibilità dei vasi sanguigni sottocutanei) o strutturali (da svuotamento, appare ombreggiata, con perdita di volume del grasso periorbitale) e miste (pigmentazione, componente vascolare, svuotamento).
La richiesta di trattamenti sicuri, efficaci, minimamente invasivi ha consentito un trattamento a base di sostanze naturali, biorivitalizzanti e bioristrutturanti, come il dispositivo medico iniettivo di classe III a base di collagene suino che abbiamo utilizzato sulle nostre pazienti sia giovani che meno giovani.
La sintesi di nuovo collagene indotta dall'utilizzo del collagene esogeno restituisce tono ed elasticità ai tessuti, agendo anche nelle aree ipercromiche con cute assotigliata e spesso iperpigmentata.
L'utilizzo di un trattamento con collagene infiltrativo per via sottocutanea nella regione perioculare migliora la texture e l'aspetto estetico.

MATERIALI E METODI:

Sono state trattate 6 pz donne di età dai 30 ai 50 anni mediante iniezioni intradermiche che presentavano occhiaie connesse a stasi vascolare e in due casi dipendenti anche da ipermelanizzazione.
E' stato effettuato un ciclo di 5 infiltrazioni a cadenza settimanale utilizzando collagene suino.
Le prime 2 infiltrazioni sono state effettuate con MD- MATRIX (contenente acido citrico e nicotinamide) 1 vials 2ml per preparare la matrice. Le successive 3 infiltrazioni sono state effettuate con MD-TISSUE (contenente vitamine C, B1, B2,B6) 1 vials da 2 ml per agire sulla cute spesso iperpigmentata.
Il dispositivo MD- MATRIX è a base di collagene suino ed eccipienti come acido citrico (esfoliante con funzione di rinnovamento cellulare che va a contrastare le imperfezioni della pelle) e nicotinamide (antiossidante che influisce positivamente sull'afflusso di sangue al derma e sul microcircolo, migliora l'aspetto della pelle schiarendo e contrastando le macchie cutanee).
Il dispositivo MD-TISSUE è a base di collagene suino ed eccipienti come vit C (per la biosintesi di aminoacidi e collagene) gluconato di magnesio (acceleratore del metabolismo proteico), vit B1 (attivatore delle funzioni metaboliche delle cellule), vit B2(protettore del tessuto cellulare da danno ossidativo), vit B6 (per il bilancio energetico e per il metabolismo degli aminoacidi).

Il protocollo combinato dei 2 tipi di dispositivi permette di sfruttare l'azione del MD-MATRIX nel preparare la matrice extracellulare (ECM) ottimizzandone la sua struttura e successivamente con MD-TISSUE per intervenire sui tessuti, potenziandone la risposta rigenerativa e biostimolante.

La scala di miglioramento estetico ha visto un' evoluzione notevole con una soddisfazione della paziente in una scala da 0 a 10, pari a 8 e una soddisfazione dell'operatore medico pari a 10.

RISULTATI:

Nelle 6 pazienti si è ottenuto un risultato efficace nell'aspetto per evidente aumento di spessore dermico epidermico con minore evidenza dell'area venosa superficiale e riduzione dell'area ipercromica.

CONCLUSIONI:

Il dispositivo medico infiltrativo a base di collagene porcino rappresenta una promettente terapia per la biostimolazione perioculare in presenza di occhiaie. La sua azione su tono, compattezza e luminosità cutanea permettono di utilizzarlo da solo o anche in associazione ad altre terapie come peeling, filler, carbossiterapia, laser nelle zone in cui la quantità di collagene inizia la sua naturale degradazione.

BIBLIOGRAFIA:

1. Cheong S, Yang H, Hao C, Lu F, He Y. Correction of Infraorbital Dark Circles Using Autologous Adipose-Derived Collagen Filler: A Novel Regenerative Option. Aesthetic Plast Surg. 2024 Nov;48(22):4693-4701.

2. Chuang AD, Lin ET, Wu BQ, Lu ME, Chiang HM, Chu PN, Lin BS, Chang CC. Quantitative Assessment of New Frontiers in Dermatochalasis and Periorbital Hyperpigmentation Treatment: The Role of Cross-Linked Porcine Collagen. Aesthetic Plast Surg. 2025 Apr;49(8):2191-2201.

3. Randelli F, Menon A, Giai Via A, et al, Effect of a Collagen-Based Compound on Morpho-Functional Properties of Cultured Human Tenocytes. Cells. 2018 Dec 6;7(12):246.

TRATTAMENTO RIGENERATIVO CON COLLAGENE SUINO INIETTIVO PER IL RILASSAMENTO CUTANEO

Dott.ssa Michela Zazzaron, *Medico Estetico - Treviso*

OBIETTIVI:

La lassità cutanea di viso e corpo (braccia, ginocchia) è una condizione frequente, spesso correlata a chronoaging, photoaging, dimagrimenti importanti e variazioni ormonali. In tali aree la perdita di tono, volume, compattezza ed elasticità porta a questa condizione di invecchiamento cellulare della pelle. Il trattamento con dispositivo medico di classe III a base di collagene suino è stato proposto alle pazienti giunte alla mia attenzione come terapia biostimolante e rigenerativa utile a migliorare la qualità tissutale, considerando la naturale degradazione di collagene a partire dai 30/35 anni.

MATERIALI E METODI:

Sono state trattate 10 pazienti con lassità cutanea nella regione brachiale, ginocchia, collo, addome. Sono state trattate con un ciclo di 5 infiltrazioni a cadenza settimanale con totale di 6 ml per ciascuna infiltrazione:

- 4 ml MD-MATRIX (contenente collagene, acido citrico, nicotinamide) per creare una barriera di difesa contro i radicali liberi, contrastare il fisiologico invecchiamento del tessuto connettivo e agevolare il rassodamento del layer sottocutaneo.
- 2 ml MD-TISSUE (contenente collagene e vit C, B1, B2, B6 e gluconato di magnesio) con azione antiossidante e metabolica sulle cellule. Sono state valutate scala di valutazione della tonicità e analisi fotografica comparativa pre e post trattamento.

PRE TRATTAMENTO

POST TRATTAMENTO

RISULTATI:

Si sono ottenuti risultati soddisfacenti in termini di recupero della tonicità, miglioramento della struttura istologica della pelle, con un effetto volumizzante e di compattezza dermica. Questo risultato è stato determinato dall'azione rigenerativa del collagene e dalla sua capacità di adesione e migrazione cellulare. Il collagene nelle aree indicate contrasta il fisiologico invecchiamento cutaneo.

CONCLUSIONI:

Il trattamento con collagene suino infiltrativo si è dimostrato ben tollerato, costo-efficace rispetto ad altre terapie. È stato verificato un miglioramento clinico significativo e percepibile sia dal paziente che dal medico in termini di riparazione e rigenerazione dei tessuti.

BIBLIOGRAFIA:

1. Ni H, Liu C, Kong L, Zhai L, Chen J, Liu Q, Chen Z, Wu M, Chen J, Guo Y, Bai W, Zhang D, Xia K, Huang G, Pan S, Liao B, Ma K, Zhang LK, Cheng J, Guan YQ. Preparation of injectable porcine skin-derived collagen and its application in delaying skin aging by promoting the adhesion and chemotaxis of skin fibroblasts. Int J Biol Macromol. 2023 Dec 31;253(Pt 2):126718
2. Salvatore L, Natali ML, Brunetti C, Sannino A, Gallo N. An Update on the Clinical Efficacy and Safety of Collagen Injectables for Aesthetic and Regenerative MedicineApplications. Polymers. 2023; 15(4):1020.
3. Randelli F, Menon A, Giai Via A, et al, Effect of a Collagen-Based Compound on Morpho-Functional Properties of Cultured Human Tenocytes. Cells. 2018 Dec 6;7(12):246.

cells

MDPI

Article

Effect of a Collagen-Based Compound on Morpho-Functional Properties of Cultured Human Tenocytes

Filippo Randelli [1], Alessandra Menon [2], Alessio Giai Via [1], Manuel Giovanni Mazzoleni [1], Fabio Sciancalepore [2], Marco Brioschi [1] and Nicoletta Gagliano [3,*]

1 Centro di Chirurgia dell'Anca e Traumatologia, I.R.C.C.S Policlinico San Donato, 20097 San Donato Milanese, Italy; filippo.randelli@fastwebnet.it (F.R.); alessiogiaivia@hotmail.it (A.G.V.); manuelmazzoleni4@gmail.com (M.G.M.); marco.brioschi@unimi.it (M.B.)

2 Azienda Socio Sanitaria Territoriale Centro Specialistico Ortopedico Traumatologico Gaetano Pini-CTO, 1^ Clinica Ortopedica, 20122 Milan, Italy; ale.menon@me.com (A.M.); fabio.sciancalepore@unimi.it (F.S.)

3 Department of Biomedical Sciences for Health, Università degli Studi di Milano, 20133 Milan, Italy

* Correspondence: nicoletta.gagliano@unimi.it; Tel.: +39-02-50315374; Fax: +39-02-50315387

Received: 28 November 2018; Accepted: 4 December 2018; Published: 6 December 2018

Abstract: Background: Greater Trochanter Pain Syndrome (GTPS) is the main reason for recalcitrant lateral hip pain. Gluteus medius and minimus tendinopathy plays a key role in this setting. An injectable medical compound containing collagen type I (MD-Tissue, Guna) has been produced with the aim to counteract the physiological and pathological degeneration of tendons. In this study we aimed at characterizing the effect of this medical compound on cultured human gluteal tenocytes, focusing on the collagen turnover pathways, in order to understand how this medical compound could influence tendon biology and healing. Methods: Tenocytes were obtained from gluteal tendon fragments collected in eight patients without any gluteal tendon pathology undergoing total hip replacement through an anterior approach. Cell proliferation and migration were investigated by growth curves and wound healing assay, respectively. The expression of genes and proteins involved in collagen turnover were analysed by real-time PCR, Slot blot and SDS-zymography. Results: Our data show that tenocytes cultured on MD-Tissue, compared to controls, have increased proliferation rate and migration potential. MD-Tissue induced collagen type I (COL-I) secretion and mRNA levels of tissue inhibitor of matrix metalloproteinases (MMP)-1 (TIMP-1). Meanwhile, lysyl hydroxylase 2b and matrix metalloproteinases (MMP)-1 and -2, involved, respectively, in collagen maturation and degradation, were not affected. Conclusions: Considered as a whole, our results suggest that MD-Tissue could induce in tenocytes an anabolic phenotype by stimulating tenocyte proliferation and migration and COL-I synthesis, maturation, and secretion, thus favouring tendon repair. In particular, based on its effect on gluteal tenocytes, MD-Tissue could be effective in the discouraging treatment of GTPS. From now a rigorous clinical investigation is desirable to understand the real clinical potentials of this compound.

Keywords: tendinopathy; Greater Trochanter Pain Syndrome; tendon; collagen turnover; matrix metalloproteinases; cytoskeleton; focal adhesion

1. Introduction

Tendinopathy is a chronic, painful condition affecting tendons, characterized by histological modifications such as collagen fibril disorganization, increased proteoglycan and glycosaminoglycan content, and increased non-collagen extracellular matrix components, hypercellularity, and neovascularization [1]. Pain associated with tendinopathy is a very common cause of disability.

Pain around the greater trochanter was in the past attributed to trochanteric bursitis, but different studies ([2,3] and references therein) have suggested that this condition is mainly determined by a tendinopathy of the gluteus medius or minimus tendons, known as Greater Trochanter Pain Syndrome (GTPS). GTPS is a clinical condition characterized by pain and tenderness at or around the greater trochanter, pain with activities such as walking and stair climbing, and lying on the affected side at night [4]. Even if it is a common condition, few effective treatments are available in the clinical practice, and are often empirical [5]. Therefore, the interest in biological and regenerative therapies aiming to improve tendon healing, such as platelet-rich plasma (PRP) or hyaluronic acid [6], has grown during the last decade.

Treatment of tendinopathy, including Greater Trochanter Pain Syndrome and others, remains a big problem for clinicians, because its pathogenesis is still largely misunderstood, and many treatments have no real evidence. The management of GTPS is traditionally first conservative, including rest, ice-packs, non-steroidal anti-inflammatory drugs (NSAIDs), physiotherapy, and local corticosteroids injections. However, recent studies found little evidence to support physical therapy or exercise programs for gluteal tendinopathy [7]. Corticosteroid injections are widely used despite controversies regarding the use of glucocorticoid injections for the treatment of tendinopathy. A recent systematic review of literature showed that they provide short-term pain relief, but no long-term benefits [5,8]. No statistically significant differences have been reported after 1 year compared to oral NSAIDs. Some authors reported about the use of Extracorporeal Shock Wave Therapy (ESWT) with good results [9], but the evidence of most of these studies is low, and no level I studies are published in literature. Therefore, biological therapies aiming to improve tendon healing become very attractive. The only level I study on the PRP showed an improvement of pain and mHHS at 12 weeks after a single injection of PRP, compared to a single injection of corticosteroids [10]. In a recent case series, promising results have been reported with autologous tenocyte injection [11]. However, there is still little evidence to support the use of biological therapies for treatment of GTPS [12].

Tendons play key functions in musculoskeletal system in transferring forces generated by muscle contraction to the skeleton. Their mechanical properties are based on the underlying extracellular matrix (ECM) structure and composition, mainly consisting of type I collagen (COL-I) [13–15]. Tenocytes are tendon specialized fibroblasts interspersed between collagen fibers, responsible for the metabolic activity and structure of tendon. They are involved in collagen turnover pathways and act as mechanosensors playing key roles in modifying gene expression for ECM components in response to mechanical forces acting on tendons [14,16,17].

The aim of this study was to investigate in vitro the effect of MD-Tissue®, an injectable collagen-based medical compound with therapeutic potential (registered as a medical device in different countries) containing swine collagen as main component, on human tenocytes, with particular attention on collagen turnover pathways, in order to understand the molecular mechanisms triggered by this medical compound and, therefore, how it could act in favoring tendon homeostasis and repair. We were particularly interested in clinical situations such as GTPS; for this purpose we analyzed gluteal tenocytes.

The production process of MD-Tissue by the manufacturer allows to obtain a pure product with a standardized molecular weight, having the chemical-physical characteristics to guarantee safety in clinical use. No side effects, allergic reactions, nor drug interactions have been observed. Clinical data reported that treatment with MD-Knee, a collagen-based medical compound similar to MD-Tissue, for up to 6 months was generally well tolerated, and no systemic adverse events or septic complications were observed [18,19].

The characterization in vitro of the molecular mechanisms triggered by MD-Tissue will be pivotal to plan specific clinical trials.

2. Materials and Methods

All subjects gave their informed consent for inclusion before they participated in the study. The study was conducted in accordance with the Declaration of Helsinki, and the protocol was approved by the Local Ethics Committee (San Raffaele Hospital Ethical Committee, Milan, Italy) of the coordinating Institution (IRCCS Policlinico San Donato, Milan, Italy) (63/INT/2017) Inclusion and exclusion criteria are listed in Table 1.

Table 1. Eligibility Criteria.

Inclusion Criteria	Exclusion Criteria
Age ranging 18–70 years.	Patients diagnosed of great trochanter tendinopathy
Indication for total hip arthroplasty.	Patients affected by genetic collagen disorders.
Patients who signed written informed consent for the surgery.	Patients diagnosed of spondyloarthritis with involvement of the affected hip.
Patients able to understand the study conditions and willing to participate for its entire duration.	Patients affected by psoriatic arthritis.
	Drug-addicted Alcohol-addicted Psychiatric disorders Clinical conditions which could compromise the results of the surgical procedure or of the follow-up.
	Informed consent not accepted.
	Pregnant or breastfeeding women.
	Patients affected by diabetes mellitus.
	Patients who had taken fluoroquinolones within 30 days before the surgery.

2.1. Samples

Fragments from human gluteal tendon were obtained from 8 patients (mean age 64.8 ± 7.2 years, 4 males and 4 females) without any gluteal tendon pathology and undergoing total hip replacement through an anterior approach. For each sample we analyzed the mid-substance of the collected tendon, representing the region with the typical structure of the dense regular connective tissue.

2.2. Cell Cultures

Tendon fragments were immediately washed in sterile PBS and plated in T25 flasks, incubated in Dulbecco's Modified Eagle Medium (DMEM) supplemented with 10% heat-inactivated fetal bovine serum (FBS), antibiotics (100 U/mL penicillin, 0.1 mg/mL streptomycin), and ascorbic acid (200 µM) at 37 °C in a humidified atmosphere containing 5% CO_2. When tenocytes grew out from the explant, they were trypsinized (0.025% trypsin-0.02% EDTA) for secondary cultures and plated in T75 flasks. Viability was assessed by the Trypan blue exclusion method. For evaluations, confluent human tenocytes were used between the fourth and fifth passage. For SDS-zymography cells were cultured in serum-free DMEM. Tenocytes derived from each patients and cell supernatants were prepared in duplicate and were analyzed after 24, 48, and 72 h.

2.3. Coating with MD-Tissue

MD-Tissue®, kindly provided by Guna (Milan, Italy), is an injectable medical compound based on swine collagen (100 µg/2 mL ampoules). It contains ascorbic acid, magnesium gluconate, pyridoxin hydrochloride, riboflavin, thiamine hydrochloride, NaCl and water as excipients. Swine collagen is similar to human collagen and due to the high biocompatibility with humans and very low risk of adverse effects, it has been used in various clinical fields. MD-Tissue is an injectable compound

but we hypothesized that it could act as a mechanical scaffold to influence tenocyte metabolism. Thus, MD-Tissue was used as a substrate for cell cultures. However, as previously demonstrated [20], some of the collagen used for the coating in cell cultures comes out contributing to the mechanical stimulation of tenocytes.

To obtain a thin coating, MD-Tissue (50 µg/mL) was added to multi-wells or T25 flasks (3 mL per T25 flask and 6-well multi-well plates, ad 500 µL per 24-well multi-well plates). After an incubation of at least 3–4 h at room temperature to ensure that collagen has adhered to the plastic, excess fluid was removed from the coated surface that was dried for at least 2 h under the laminar flux hood. Coated plastic was used immediately or stored at 4 °C.

Cells cultured on uncoated cell culture plastic (NC) were used as untreated controls.

2.4. Growth Curves

Cell growth was assessed by growth curves. Tenocytes were plated in triplicate samples in 6-well multi-well plates at the same cell density (100,000 cells/well). Cell number was determined using a Neubauer chamber after 24, 48, and 72 h in tenocytes in the proliferative phase.

2.5. Immunofluorescence Analysis

For fluorescence microscopy, tenocytes were cultured on uncoated (NC) or MD-Tissue coated 12-mm diameter round coverslips put into 24-well culture plates, as previously described [21]. Briefly, for actin cytoskeleton analysis, cells were incubated with 50 µM rhodamine-phalloidin (Sigma-Aldrich, St. Louis, MO, USA) and for vinculin detection, cells were incubated for 1 h at room temperature with the rabbit polyclonal antibody anti-vinculin (1:600 in PBS, Sigma-Aldrich, St. Louis, MO, USA). The secondary antibody was an anti-rabbit/Alexa488 (1:500, Life Technologies, Carlsbad, CA, USA). Cells were photographed by a digital camera connected to a Nikon Eclipse 80i microscope.

2.6. Real-Time PCR

Gene expression was analyzed by real-time RT-PCR as previously reported in samples run in triplicate [22]. GAPDH was used as endogenous control to normalize the differences in the amount of total RNA in each sample. The primers sequences were the following: Glyceraldehyde 3-phosphate dehydrogenase (GAPDH): sense CCCTTCATTGACCTCAACTACATG, antisense TGGGATTTCCATTGATGACAAGC; Long lysyl hydroxylase 2 (LH2b): sense CCGGAAACATTCCAAATGCTCAG, antisense GCCAGAGGTCATTGTTATAATGGG; Tissue inhibitor of matrix metalloproteinase 1 (TIMP-1): sense GGCTTCTGGCATCCTGTTGTTG, antisense AAGGTGGTCTGGTTGACTTCTGG; vinculin: sense GGAGGTGATTAACCAGCCAAT, antisense AATGATGTCATTGCCCTTGC; Focal adhesion kinase (FAK): sense GTCTGCCTTCGCTTCACG, antisense GAATTTGTAACTGGAAGATGCAAG; Nanog sense CCCCAGCCTTTACTCTTCCTA, antisense CCAGGTTGAATTGTTCCAGGTC. Each sample was analyzed in triplicate in a Bioer LineGene 9600 thermal cycler (Bioer, hangzhou, China) after 40 cycles. The cycle threshold (Ct) was determined and gene expression levels relative to that of GAPDH were calculated. To confirm the reliability of gene expression results, mRNA levels of target genes were normalized on a second housekeeping gene, the 18s ribosomal RNA. The expression pattern obtained was similar (data not shown).

2.7. Slot Blot

Collagen type I and III (COL-I, COL-III), matrix metalloproteinase (MMP)-1 protein levels secreted by tenocytes were assessed in duplicate samples by Slot blot in serum free cell culture medium, as previously detailed [21]. Membranes were incubated for 1 h at room temperature in monoclonal antibody to COL-I (1:1000 in TBST) (Sigma-Aldrich, Milan, Italy), COL-III (1:2000 in TBST) (Sigma-Aldrich, Milan, Italy), MMP-1 (1 µg/mL in TBST) (Millipore, Milan, Italy). Immunoreactive

bands, revealed by the Amplified Opti-4CN substrate (Amplified Opti-4CN, Bio Rad, Italy), were scanned densitometrically (UVBand, Eppendorf, Italy).

2.8. SDS-Zymography

SDS-zymography was used to analyze MMP-2 activity of secreted protein in cell culture medium, as previously described [21]. MMP gelatinolytic activity, detected after staining the gels with Coomassie brilliant blue R250 as clear bands on a blue background, were quantified by densitometric scanning (UVBand, Eppendorf, Italy).

2.9. Wound Healing Assay

Cell migration in adult and aging tenocytes was analyzed by wound healing assay in uncoated (NC) and MD-Tissue coated 6-wells multi-well plates [22]. The "scratch" was created in confluent tenocytes using a p 200 pipet tip. After cell debris removal by DMEM washing, multi-well plates were incubated at 37 °C and observed under an inverted microscope at different time points. Digital images were captured by a digital camera after 0 and 24 h, and the size of the "scratch" was measured to obtain the migration potential.

2.10. Statistical Analysis

Statistical analysis was performed using GraphPad Prism v 6.0 software (GraphPad Software Inc., San Diego, CA 92108, USA). Data were obtained from two replicate experiments for each of the patients-derived cell lines cultured in duplicate and were expressed as mean ± standard deviation (SD). Comparison of groups was calculated using independent samples two-tailed t test. Differences associated with p-values lower than 5%, at a confidence level of 95%, were to be considered significant.

3. Results

3.1. Cell Growth

Cell proliferation evaluated by growth curves showed that tenocytes cultured on uncoated (NC) or MD-Tissue coated 6-well multi-well plates had the same proliferation rate after 24 and 48 h. By contrast, cell proliferation significantly increased in tenocytes grown on MD-Tissue after 72 h ($p < 0.05$ vs. 72 h NC) (Figure 1).

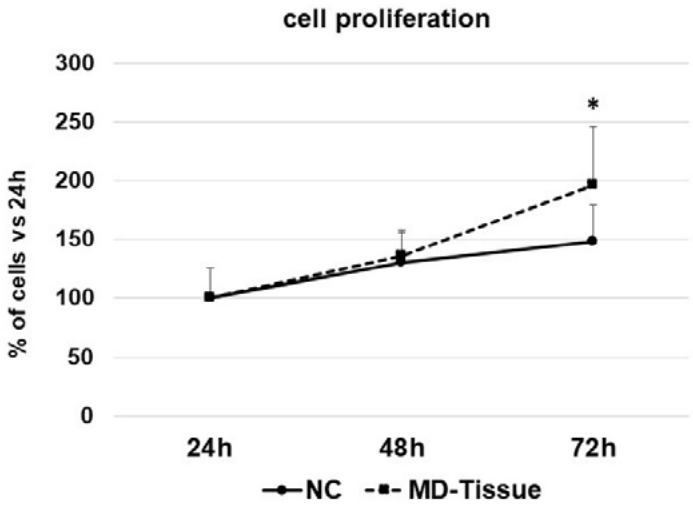

Figure 1. Growth curves of tenocytes grown without (NC) or on MD-Tissue at the indicated time points. Data are expressed as percentages vs. the time point T24 and are mean + SD. * $p < 0.05$ vs. 72 h NC.

3.2. Expression of Genes and Proteins Related to Collagen Turnover

Since it was demonstrated that, using different methods to isolate tenocytes from tendon fragments, the obtained cell population can be a mixed population of terminally differentiated tenocytes and progenitor cells [23], we first characterized our cells determining the expression of Nanog, one of the main mesenchymal stem cell markers [24]. Adipose tissue-derived stem cells (ASCs) (kindly provided by Dr. Anna Brini, University of Milan) were used as positive control. We found that Nanog is almost undetectable in all the considered cell cultures obtained from tendon fragments, while it is highly expressed in ASCs (Figure 2), showing that cells used in this study are mostly differentiated tenocytes.

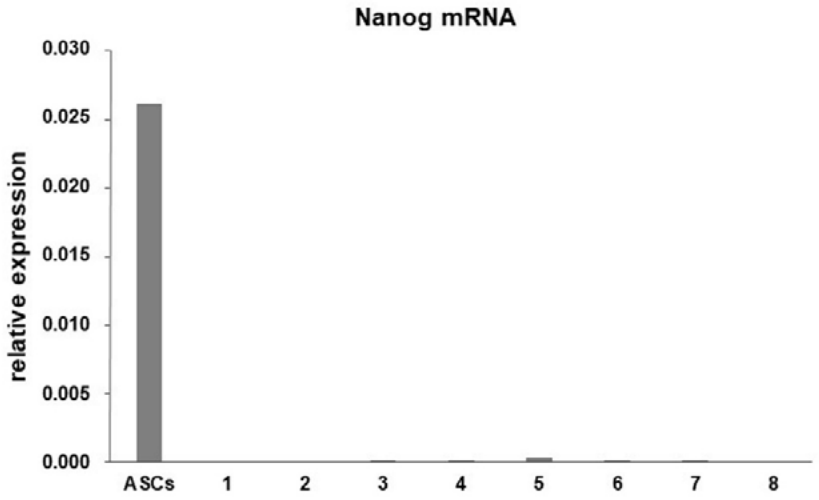

Figure 2. Bar graphs showing mRNA levels for Nanog in adipose tissue-derived stem cells (ASCs) and the eight cell cultures of tenocytes assessed by real-time PCR. Data were normalized on Glyceraldehyde 3-phosphate dehydrogenase (GAPDH) gene expression.

Collagen maturation was assessed by analyzing LH2b gene expression by real time PCR, involved in cross-linking of newly synthetized collagen. LH2b mRNA levels were unaffected by MD-Tissue at all the considered time points (Figure 3). Slot blot analysis revealed that COL-I protein levels secreted in cell culture medium by tenocytes cultured on MD-Tissue were increased (+25%, +19% and +18%, respectively, for COL vs. NC after 24, 48 and 72 h). This increase was statistically significant in cells cultured on COL, compared to NC, at all the considered time points ($p < 0.005$, $p < 0.05$ and $p < 0.05$ for MD-Tissue vs. CT, respectively, at 24, 48 and 72 h) **(**Figure 4A,B). To demonstrate that collagen expression detected by Slot blot originates from tenocytes and not from the coating, we prepared a Slot blot to analyze COL-I expression in the same volume (100 µL) of tenocyte culture medium, DMEM from a MD-Tissue coated well, DMEM only and TBS buffer. The result shows that an immunoreactive band is detected only for tenocytes, demonstrating that collagen originates only from cells and not from the coating (Figure 3C). By contrast, COL-III protein levels were similarly secreted by NC and MD-Tissue tenocytes (data not shown).

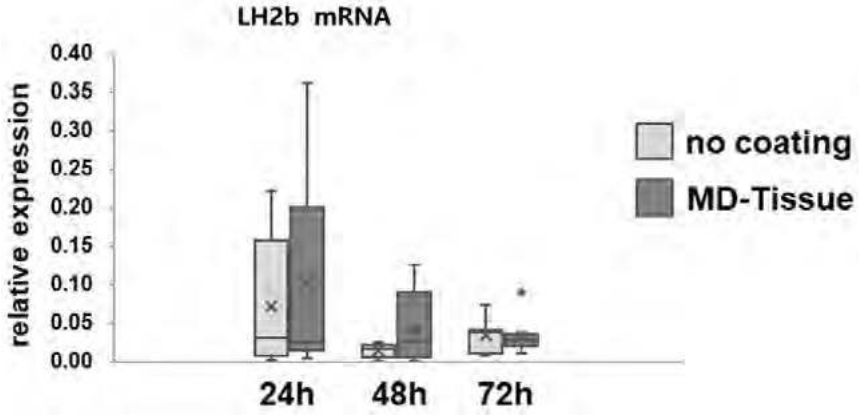

Figure 3. Bar graphs showing mRNA levels for Long lysyl hydroxylase 2 (LH2b) in NC and MD-Tissue tenocytes (COL) assessed by real-time PCR. Data were normalized on GAPDH gene expression and are expressed as mean ± SD for at least two independent experiments for the eight samples run in duplicate. ×: mean; •: outlier sample.

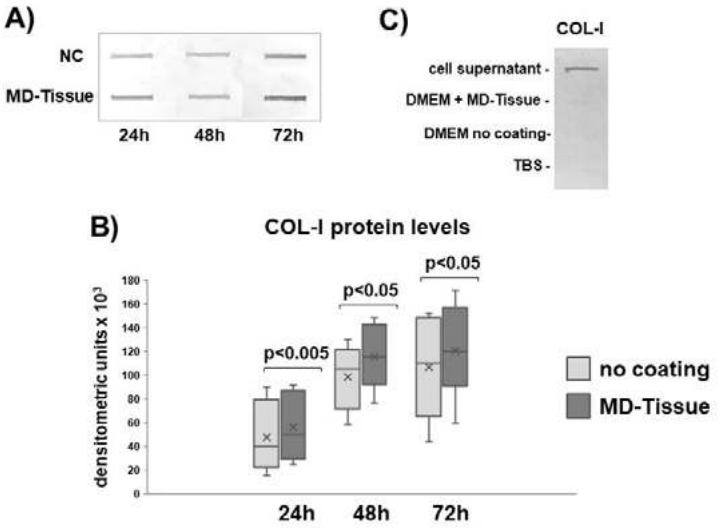

Figure 4. Representative slot blot analysis for collagen type I (COL-I) expression (**A**) expression in cell-culture medium of tenocytes cultured without coating (NC) or on MD-Tissue. Bar graphs displaying COL-I (**B**) protein levels analyzed densitometric scanning of immunoreactive bands in panel A. Data are expressed as mean ± SD for the 8 samples. (**C**) Slot blot analysis for COL-I showing that COL-I expression originates from tenocytes. ×: mean.

Collagen degradation analysis revealed that MMP-1 levels (Figure 5A,B), and MMP-2 activity (Figure 5C,D) were similar in tenocytes cultured without coating (NC) or on MD-Tissue. By contrast, gene expression for TIMP-1, the main inhibitor of MMP-1, was strongly affected by MD-Tissue. In fact, gene expression was significantly up-regulated after 24 h ($p < 0.05$) and tended to a significant up-regulation after 72 h ($p = 0.056$) (Figure 6). Some interindividual differences in MMPs expression and TIMP-1 mRNA levels were observed, showing unchanged, increased or decreased levels. However, a strong correlation ($p = 0.056$) was observed between MMP-1 protein levels and TIMP-1 gene expression for tenocytes cultured on MD-Tissue at 72 h.

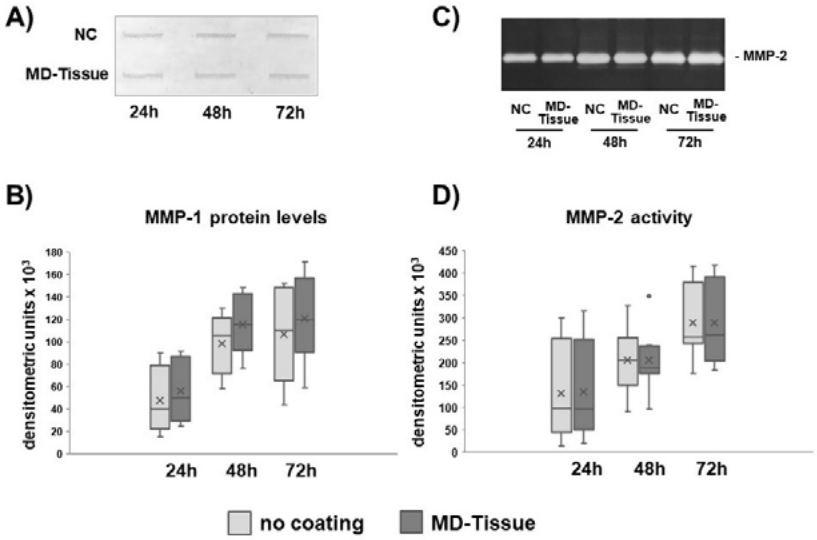

Figure 5. Representative slot blot for matrix metalloproteinase-1 (MMP-1) levels (**A**) and representative SDS-zymography showing MMP-2 activity in serum-free cell supernatants of NC and MD-Tissue tenocytes. Bar graphs showing MMP-1 protein levels (**C**) and MMP-2 activity (**D**) after densitometric analysis of immunoreactive and lytic bands, respectively. Data obtained from the eight samples are expressed as a % of densitometric units vs NC and are ± SD. NC: no coating. ×: mean; •: outlier sample.

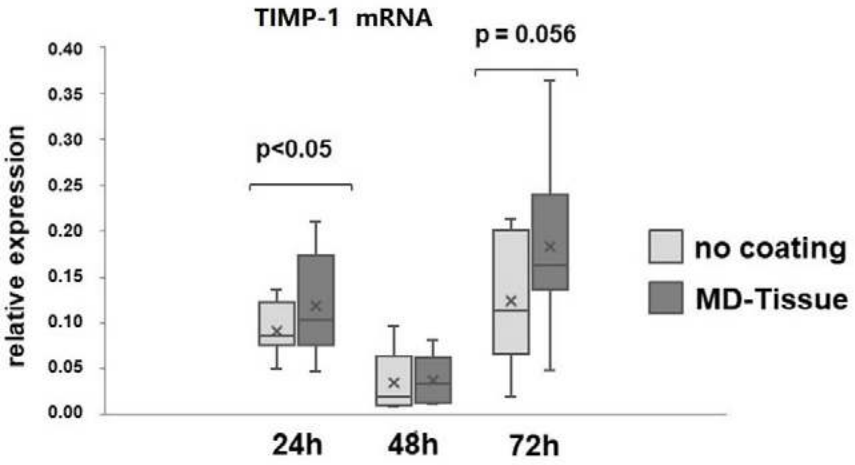

Figure 6. Bar graphs showing tissue inhibitor of matrix metalloproteinase-1 (TIMP-1) gene expression after normalization on GAPDH mRNA levels. Data obtained from the eight samples are expressed as mean ± SD. ×: mean.

3.3. Cytoskeleton Arrangement and Focal Adhesion

Fluorescent microscopy analysis for F-actin (Figure 7A,B) revealed that actin filaments seem unaffected by MD-Tissue. In both experimental conditions, they are long and mostly longitudinally oriented in the cytoplasm.

In order to investigate whether MD-Tissue influences the ability of tenocytes to form focal adhesions needed for cell migration, we analyzed the gene expression for vinculin (VCN) and Focal adhesion kinase (FAK), key proteins involved in the formation of the adhesion plaque. VCN and FAK mRNA levels, although with some interindividual differences, were unaffected by MD-Tissue (Figure 7C,D). Immunofluorescence analysis for VCN shows that the protein is co-localized with actin in correspondence of focal adhesion formation on the substrate, and many focal adhesions were detectable in tenocytes cultured on either NC or MD-Tissue. Very frequently, the region corresponding

to the presence of the focal adhesion seem bigger in tenocytes cultured on MD-Tissue compared to NC tenocytes (see arrows in Figure 7B).

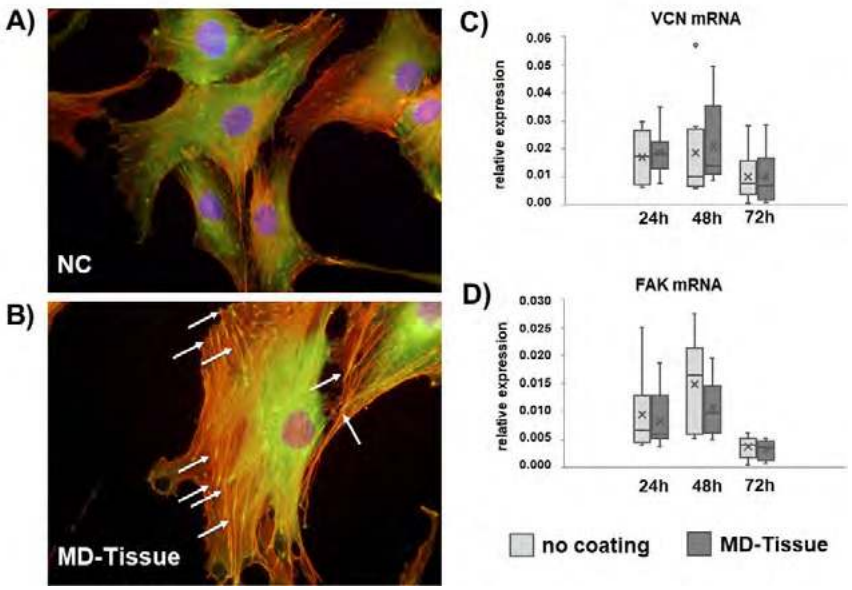

Figure 7. Immunofluorescence analysis for vinculin (green) in control tenocytes (NC) (**A**) and tenocytes cultured on MD-Tissue (**B**). Actin filaments are stained using rhodamine-phalloidin labeling. Nuclei are stained in blue by DAPI. Original magnification: 60×. Bar graphs showing VCN (**C**) and FAK (**D**) gene expression relative to GAPDH mRNA levels in NC and MD-Tissue tenocytes (COL). Data obtained from the eight samples are expressed as mean ± SD. ×: mean; ●: outlier sample.

3.4. Wound Healing Assay

Wound healing assay was used to analyze tenocyte migration of tenocytes cultured on MD-Tissue. The comparison of the scratch size revealed that cell migration is significantly increased by MD-Tissue ($p < 0.05$ vs. NC) (Figure 8).

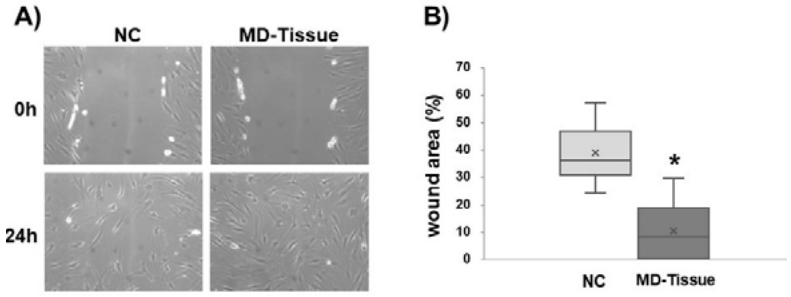

Figure 8. (**A**) Representative micrographs showing wound healing assay in control tenocytes (NC) and tenocytes grown on MD-Tissue at 0 and 24 h after the scratch. Original magnification: 10×. (**B**) Bar graphs showing the area of wound closure, expressed as a % of the area at 0 h, in cultured tenocytes in both experimental conditions 24 h after the scratch. * $p < 0.005$ vs. NC. ×: mean.

4. Discussion

Treatment of tendinopathy, including Greater Trochanter Pain Syndrome and others, remain a big problem for clinicians, because its pathogenesis is still largely misunderstood, and many treatments have no real evidence. We aimed at characterizing in vitro the molecular mechanisms triggered in human tenocytes by MD-Tissue®, and the main findings of this study reveal that this collagen-based

injectable medical compound could favor tendon repair by inducing tenocyte proliferation and migration, and stimulating COL-I synthesis, secretion and maturation.

Tendons play key functions in musculoskeletal system serving to transfer forces generated by muscle contraction to the skeleton. Tendon mechanical properties are based on the underlying extracellular matrix (ECM) structure and composition, mainly consisting of type I collagen (COL-I), which constitutes about 60–85% of the dry mass of the tendon and about 95% of the total collagen, and elastin, accounting for 1–2% [13–15]. Collagen and elastin are embedded in a ground substance rich in proteoglycans, glycosaminoglycans, structural glycoproteins, and a wide variety of other small molecules, having water-binding capacity and contributing to the stabilization of the whole tendon structure. The unique structure and composition of tendons provide them the characteristic mechanical stability, and COL-I represents the most important factor for tendon mechanical strength.

Tenocytes are tendon specialized fibroblasts interspersed between collagen fiber bundles and aligned along the long axis of tendon, responsible for the synthesis and degradation of collagen and all components of the ECM. Tenocytes act as mechanosensors playing key roles for the tendon's adaptive response and change their metabolic activities in response to mechanical forces acting on tendons, modifying gene expression for ECM components and, as a consequence, affecting tendon's mechanical properties [14,16,17].

Tendon mechanical properties are based on its structure and composition, allowing tissue mechanical adaptation in response to mechanical forces. Tenocytes are responsible for tendon mechanical adaptation converting mechanical stimuli into biochemical signals that ultimately lead to tendon adaptive physiological or pathological changes. Mechanical loads at physiological levels are usually beneficial to tendons in terms of enhancing their mechanical properties [25–27], and increase collagen synthesis [28]. Therefore, appropriate mechanical loads induce tendon adaptation and have anabolic effects, improving their strength and healing quality after injury.

Collagen is the major component of tendon ECM; its turnover is controlled by tenocytes acting at the level of collagen synthesis, maturation and degradation, thus determining the tendon ability to resist mechanical forces and repair in response to injury [14]. Our data show that COL-I secretion is significantly induced by MD-Tissue® at all considered time points, suggesting that this medical compound is able to stimulate an anabolic phenotype of tenocytes. Newly synthesized collagen undergoes cross-linking, that is an important requirement for collagen maturation providing tendon strength, collagen fibril stabilization and increased tendon tensile strength [29,30]. Furthermore, our data show that this particular medical compound is not able to affect gene expression for LH2b, needed to provide cross-linking during collagen maturation, suggesting that collagen stability is not affected.

Since collagen content is the result of a finely regulated dynamic balance between its synthesis and degradation driven by MMPs, tendon strength is strongly dependent on degradation pathways. COL breakdown is played by MMP-1, able to cleave the intact collagen triple helix, followed by other proteases [31,32]. The role of MMP-1 is boosted by the previously demonstrated inverse correlation between MMP-1 gene/protein expression and the amplitude of tensile mechanical load on tendons, suggesting that low levels of MMP-1 lead to a more stable and less susceptible to damage tendon structure [33]. MMPs activation and activity are regulated by TIMPs [34,35], and TIMP-1 is the main inhibitor of MMP-1. In this study, we show that MMP-1 and MMP-2 were unaffected by MD-Tissue®, but, interestingly, we observed a significant increase in TIMP-1 gene expression induced by the medical compound after 24 h, and a tendency to an up-regulation after 72 h. This result leads to the hypothesis that MD-Tissue is able to stimulate COL secretion by tenocytes, increasing COL content in tendons, and that COL increase is favored by inhibition of its degradation.

Some interindividual differences in fibroblast cell lines were observed, especially in LH2b mRNA, MMPs and TIMP-1 mRNA. In fact, in some tenocytes the expression resulted unchanged, increased or decreased. Interindividual differences were previously described in gingival fibroblasts, suggesting the "cell subpopulation theory" [36] that described that the gingival fibroblast population is composed of different subsets of fibroblasts that respond to external or endogenous stimuli in different way.

Fibroblast heterogeneity was described also recently [37]. According to this theory, we can hypothesize it is valid also for fibroblasts derived from different tissues, such as tenocytes.

ECM homeostasis is influenced by mechanical forces acting on tendons, and tenocytes are key effectors in tendon ECM remodeling and adaptation to the experienced mechanical loading. They are mechanoresponsive cells able to convert mechanical signals into biological events such as gene expression and cell proliferation [38,39]. Tenocytes are able to sense changes in their mechanical environment using a mechanotransduction system based on the actin cytoskeleton, and to respond by modifying their activity [33]. Since actin cytoskeleton arrangement and integrity are the key mechanotransduction apparatus influencing the tensional homeostasis and mechanoresponsiveness needed to maintain ECM balance [40,41], we investigated whether MD-Tissue® affected actin cytoskeleton. Our data show that actin filaments are brightly labelled and longitudinally running in tenocytes cultured on plastic (NC) or on MD-Tissue®, and their arrangement is similar in both experimental conditions, suggesting that this component of the mechanoresponsive apparatus is not modified by the medical compound.

The actin cytoskeleton is also actively involved in cell migration, a dynamic process mediated by a repeated cycle of attachment to the ECM, generation of cytoskeletal forces of propulsion, and subsequent detachment of the cell from the matrix. The attachment of cells to the ECM is mediated by integrins, transmembrane proteins that provide a bridge though which forces can be transmitted between inside and outside of the cells. In fact, the extracellular domain of the integrin binds to ECM components, whereas its cytoplasmic domain links various intracellular proteins interposed between actin filaments and the integrin, forming focal adhesion complexes at the leading edge of the cell [42]. Focal adhesions are not only involved in transmitting the mechanical signals from the ECM into cells to modulate ECM remodeling; they are also necessary to generate the traction required for cell migration [42]. We used a wound healing assay to investigate if tenocyte motility is affected by MD-Tissue® since this test is particularly suitable to investigate the effects of cell–matrix interactions on cell migration, mimicking in vivo cell migration [21], and we found that this medical compound significantly increased cell migration. Interestingly, no difference in actin cytoskeleton between NC and MD-Tissue tenocytes was detected, and also gene expression for FAK and VCN, two main components of the focal adhesion complex, was similar in both experimental conditions, supporting the hypothesis of a similar ability to form focal adhesions. However, interestingly, immunofluorescence analysis of VCN expression revealed that focal adhesions containing VCN seem more evident in tenocytes plated on MD-Tissue, leading to the hypothesis that MD-Tissue® could act as a mechanical scaffold improving tenocyte focal adhesion, allowing a more efficient mechanoresponsiveness and migration ability. This could make tenocytes more efficient in maintaining ECM homeostasis in response to different mechanical load and in generating the traction necessary for cell migration [42]. Since the process of tendon repair and regeneration is reliant on tenocyte migration [43], MD-Tissue® could be effective in favoring tendon healing in tendinopathies, but clinical trials are needed to confirm this suggestion.

A limit of this study is represented by the lacking of studies aimed at characterizing the permanence and rheological and visco-elastic properties of MD-Tissue, however clinical studies are available demonstrating that the collagen-based medical compound is effective in osteoarticular pathologies [18,19].

MD-Tissue could offer some advantages compared to other biological agents since it can be administered singularly or in association with other therapeutic agents and the reduced cost compared to low or high MW HA could allow wider use, resulting in a NSAIDs intake reduction.

5. Conclusions

Considered as a whole, these in vitro findings suggest a mechanism for MD-Tissue likely acting as a mechanical scaffold able to induce an anabolic phenotype in tenocytes, favoring tendon homeostasis and repair. Interestingly, it was demonstrated [20] that the addition of acid-soluble type I collagen to

fibroblasts cultured on plastic also affected collagen turnover mechanisms since some of the collagen comes out of solution and precipitates on cell surfaces, still eliciting some effect nonmediated by a cell-substrate interaction. This suggests that little mechanical resistance is sufficient to activate cell receptors, influencing collagen turnover mechanisms and, very likely, other biological activities played by tenocytes. We can hypothesize that MD-Tissue effect could be also mediated by this alternative mechanism. Our results suggest that MD-Tissue® could represent a novel therapeutic approach, and stimulate new clinical trials to investigate the effects of this medical compound to treat difficult tendon pathologies. Based on our in vitro findings obtained on gluteal tenocytes, we will perform in future a clinical trial to prove its utility on GTPS.

Author Contributions: Conceptualization, N.G.; F.R; Methodology, N.G; Investigation, N.G., F.R, A.G.V., A.M, M.G.M., M.B., and F.S; Data Curation, N.G.; Writing—Original Draft Preparation, N.G.; Writing—Review and Editing, N.G., F.R, A.G.V., A.M, M.G.M., M.B., and F.S.

Funding: This study was partially supported by Guna S.p.a. The funder had no role in the design or conduct of the study, in analysis and interpretation of data, or in the preparation of the manuscript.

Acknowledgments: We thank Anna Brini (Department of Biomedical, Surgical and Dental Sciences, University of Milan) for providing ASCs cells, and Lorenzo Castagnoli (Fondazione IRCCS Istituto Nazionale dei Tumori, Milan) for providing primers for Nanog analysis.

Conflicts of Interest: The authors declare that the manuscript is free of conflict of interest. This study was partially supported by Guna S.p.a. The sponsor had no role in the design or conduct of the study, in analysis and interpretation of data, or in preparation of the manuscript.

References

1. Giai Via, A.; Papa, G.; Oliva, F.; Maffulli, N. Tendinopathy. *Curr. Phys. Med. Rehabil. Rep.* **2016**, *4*, 50–55. [CrossRef]
2. Ejnisman, L.; Safran, M.R. Biologics in hip preservation. *Ann. Joint* **2018**, *3*, 50. [CrossRef]
3. Karpinski, M.R.; Piggott, H. Greater trochanteric pain syndrome. A. report of 15 cases. *J. Bone Joint Surg. Br.* **1985**, *67*, 762–763. [CrossRef] [PubMed]
4. Fearon, A.M.; Scarvell, J.M.; Neeman, T.; Cook, J.L.; Cormick, W.; Smith, P.N. Greater trochanteric pain syndrome: Defining the clinical syndrome. *Br. J. Sports Med.* **2013**, *47*, 649–653. [CrossRef]
5. Frizziero, A.; Vittadini, F.; Pignataro, A.; Gasparre, G.; Biz, C.; Ruggieri, P.; Masiero, S. Conservative management of tendinopathies around hip. *Muscles, Ligaments Tendons J.* **2016**, *6*, 281–292. [CrossRef] [PubMed]
6. Reid, D. The management of greater trochanteric pain syndrome: A systematic literature review. *J. Orthop.* **2016**, *13*, 15–28. [CrossRef] [PubMed]
7. Grimaldi, A.; Mellor, R.; Hodges, P.; Bennell, K.; Wajswelner, H.; Vicenzino, B. Gluteal tendinopathy: A review of mechanisms, assessment and management. *Sports Med.* **2015**, *45*, 1107–1119. [CrossRef]
8. Seo, K.H.; Lee, J.Y.; Yoon, K.; Do, J.G.; Park, H.J.; Lee, S.Y.; Park, Y.S.; Lee, Y.T. Long-term outcome of low-energy extracorporeal shockwave therapy on gluteal tendinopathy documented by magnetic resonance imaging. *PLoS ONE* **2018**, *13*, e019746. [CrossRef]
9. Del Buono, A.; Papalia, R.; Khanduja, V.; Denaro, V.; Maffulli, N. Management of the greater trochanteric pain syndrome: A. systematic review. *Br. Med. Bull.* **2012**, *102*, 115–131. [CrossRef]
10. Fitzpatrick, J.; Bulsara, M.K.; O'Donnell, J.; McCrory, P.R.; Zheng, M.H. The effectiveness of platelet-rich plasma injections in gluteal tendinopathy a randomized, double-blind controlled trial comparing a single platelet-rich plasma injection with a single corticosteroid injection. *Am. J. Sports Med.* **2018**, *46*, 933–939. [CrossRef]
11. Thomas, A.; Bucher, T.A.; Ebert, J.R.; Smith, A.; Breidahl, W.; Fallon, M.; Wang, T.; Zheng, M.H.; Janes, G.C. Autologous tenocyte injection for the treatment of chronic recalcitrant gluteal tendinopathy a prospective pilot study. *Orthopaedic J. Sports Med.* **2017**, *5*, 1–10. [CrossRef]
12. Andia, I.; Maffulli, N. How far have biological therapies come in regenerative sports medicine? *Expert Opin. Biol. Ther.* **2018**, *18*, 785–793. [CrossRef]
13. Kannus, P. Structure of the tendon connective tissue. *Scand J. Med. Sci Sports* **2000**, *10*, 312–320. [CrossRef]

14. Kjaer, M. Role of extracellular matrix in adaptation of tendon and skeletal muscle to mechanical loading. *Physiol. Rev.* **2004**, *84*, 649–698. [CrossRef] [PubMed]
15. Riley, G.P.; Harrall, R.L.; Constant, C.R.; Chard, M.D.; Cawston, T.E.; Hazleman, B.L. Glycosaminoglycans of human rotator cuff tendons: Changes with age and in chronic rotator cuff tendinitis. *Ann. Rheum. Dis.* **1994**, *53*, 367–376. [CrossRef] [PubMed]
16. Banes, A.J.; Horesovsky, G.; Larson, C.; Tsuzaki, M.; Judex, S.; Archambault, J.; Zernicke, R.; Herzog, W.; Kelley, S.; Miller, L. Mechanical load stimulates expression of novel genes in vivo and in vitro in avian flexor tendon cells. *Osteoarthritis Cartilage* **1999**, *7*, 141–153. [CrossRef] [PubMed]
17. Benjamin, M.; Ralphs, J.R. The cell and developmental biology of tendons and ligaments. *Int. Rev. Cytol.* **2000**, *196*, 85–130.
18. Martin, L.S.; Massafra, U.; Bizzi, E.; Migliore, A. A double blind randomized active-controlled clinical trial on the intra-articular use of Md-Knee versus sodium hyaluronate in patients with knee osteoarthritis ("Joint"). *BMC Musculoskelet Disord* **2016**, *17*, 94. [CrossRef]
19. Pavelka, K.; Jarosova, H.; Sleglova, O.; Svobodova, R.; Votavova, M.; Milani, L.; Prochazka, Z.; Kotlarova, L.; Kostiuk, P.; Sliva, J.; et al. Chronic Low Back Pain: Current Pharmacotherapeutic Therapies and a New Biological Approach. *Curr. Med. Chem.* **2018**, *25*, 1–8. [CrossRef]
20. Ritty, T.M.; Herzog, J. Tendon cells produce gelatinases in response to type I collagen attachment. *J. Orthop. Res.* **2003**, *21*, 442–450. [CrossRef]
21. Menon, A.; Pettinari, L.; Martinelli, C.; Colombo, G.; Portinaro, N.; Dalle-Donne, I.; d'Agostino, M.C.; Gagliano, N. New insights in extracellular matrix remodeling and collagen turnover related pathways in cultured human tenocytes after ciprofloxacin administration. *Muscles Ligaments Tendons J.* **2013**, *113*, 122–131.
22. Liang, C.C.; Park, A.Y.; Guan, J.L. In vitro scratch assay: A convenient and inexpensive method for analysis of cell migration in vitro. *Nat. Protoc.* **2007**, *2*, 329–333. [CrossRef] [PubMed]
23. Viganò, M.; Perucca Orfei, C.; de Girolamo, L.; Pearson, J.R.; Ragni, E.; De Luca, P.; Colombini, A. Housekeeping Gene Stability in Human Mesenchymal Stem and Tendon Cells Exposed to Tenogenic Factors. *Tissue Eng. Part. C Methods* **2018**, *24*, 360–367. [CrossRef] [PubMed]
24. Calloni, R.; Cordero, E.A.; Henriques, J.A.; Bonatto, D. Reviewing and updating the major molecular markers for stem cells. *Stem Cells Dev.* **2013**, *22*, 1455–1476. [CrossRef] [PubMed]
25. Viidik, A. The effect of training on the tensile strength of isolated rabbit tendons. *Scand J. Plast Reconstr. Surg.* **1967**, *1*, 141–147. [CrossRef] [PubMed]
26. Woo, S.L.; Ritter, M.A.; Amiel, D.; Sanders, T.M.; Gomez, M.A.; Kuei, S.C.; Garfin, S.R.; Akeson, W.H. The biomechanical and biochemical properties of swine tendons–long term effects of exercise on the digital extensors. *Connect. Tissue Res.* **1980**, *7*, 177–183. [CrossRef]
27. Woo, S.L.; Gomez, M.A.; Amiel, D.; Ritter, M.A.; Gelberman, R.H.; Akeson, W.H. The effects of exercise on the biomechanical and biochemical properties of swine digital flexor tendons. *J. Biomech. Eng.* **1981**, *103*, 51–56. [CrossRef]
28. Langberg, H.; Rosendal, L.; Kjaer, M. Training-induced changes in peritendinous type I collagen turnover determined by microdialysis in humans. *J. Physiol.* **2001**, *534*, 297–302. [CrossRef]
29. Silver, F.H.; Christiansen, D.; Snowhill, P.B.; Chen, Y.; Landis, W.J. The role of mineral in the storage of elastic energy in turkey tendons. *Biomacromolecules* **2000**, *1*, 180–185. [CrossRef]
30. Walker, L.C.; Overstreet, M.A.; Yeowell, H.N. Tissue-specific expression and regulation of the alternatively-spliced forms of lysyl hydroxylase 2 (LH2) in human kidney cells and skin fibroblasts. *Matrix. Biol.* **2005**, *23*, 515–523. [CrossRef]
31. Sakai, T.; Gross, J. Some properties of the products of reaction of tadpole collagenase with collagen. *Biochemistry* **1967**, *6*, 518–528. [CrossRef] [PubMed]
32. Woessner, F.J. Matrix metalloproteinases and their inhibitors in connective tissue remodelling. *FASEB J.* **1991**, *5*, 2145–2154. [CrossRef] [PubMed]
33. Arnoczky, S.P.; Tian, T.; Lavagnino, M.; Gardner, K. Ex vivo static tensile loading inhibits MMP-1 expression in rat tail tendon cells through a cytoskeletally based mechanotransduction mechanism. *J. Orthop. Res.* **2004**, *22*, 328–333. [CrossRef]
34. Brew, K.; Dinakarpandian, D.; Nagase, H. Tissue inhibitors of metalloproteinases: Evolution, structure and function. *Biochim. Biophys. Acta* **2001**, *1477*, 267–283. [CrossRef]

35. Murphy, G.; Willenbrock, F.; Crabbe, T.; O'Shea, M.; Ward, R.; Atkinson, S.; O'Connell, J.; Docherty, A. Regulation of matrix metalloproteinase activity. *Ann. N Y Acad. Sci.* **1994**, *732*, 31–41. [CrossRef] [PubMed]
36. Phipps, R.P.; Borrello, M.A.; Blieden, T.M. Fibroblast heterogeneity in the periodontium and other tissues. *J. Periodontal Res.* **1997**, *32*, 159–165. [CrossRef] [PubMed]
37. Archana, A.; Srikanth, V.; Sasireka; Kurien, B.; Ebenezer. Fibroblast Heterogeneity in Periodontium. *Int. J. Dental Sci. Res.* **2014**, *2*, 50–54. [CrossRef]
38. Burridge, K.; Guilluy, C. Focal adhesions, stress fibers and mechanical tension. *Exp. Cell. Res.* **2016**, *343*, 14–20. [CrossRef]
39. Wang, J.H.; Guo, Q.; Li, B. Tendon Biomechanics and Mechanobiology-A Minireview of Basic Concepts and Recent Advancements. *J. Hand Ther.* **2012**, *25*, 133–140. [CrossRef]
40. Docking, S.; Samiric, T.; Scase, E.; Purdam, C.; Cook, J. Relationship between compressive loading and ECM changes in tendons. *Muscle Ligaments Tendons J.* **2013**, *3*, 7–11. [CrossRef]
41. Heinemeier, K.M.; Olesen, J.L.; Haddad, F.; Schjerling, P.; Baldwin, K.M.; Kjaer, M. Effect of unloading followed by reloading on expression of collagen and related growth factors in rat tendon and muscle. *J. Appl. Physiol.* **2009**, *106*, 178–186. [CrossRef] [PubMed]
42. Reed, M.J.; Ferara, N.S.; Vernon, R.B. Impaired migration, integrin function, and actin cytoskeletal organization in dermal fibroblasts from a subset of aged human donors. *Mech. Ageing Dev.* **2001**, *122*, 1203–1220. [CrossRef]
43. Jones, M.E.; Mudera, V.; Brown, R.A.; Cambrey, A.D.; Grobbelaar, A.O.; McGrouther, D.A. The early surface cell response to flexor tendon injury. *J. Hand Surg. Am.* **2003**, *28*, 221–230. [CrossRef] [PubMed]

© 2018 by the authors. Licensee MDPI, Basel, Switzerland. This article is an open access article distributed under the terms and conditions of the Creative Commons Attribution (CC BY) license (http://creativecommons.org/licenses/by/4.0/).

cells

MDPI

Article

The Collagen-Based Medical Device MD-Tissue Acts as a Mechanical Scaffold Influencing Morpho-Functional Properties of Cultured Human Tenocytes

Filippo Randelli [1], Patrizia Sartori [2], Cristiano Carlomagno [3], Marzia Bedoni [3], Alessandra Menon [2,4], Elena Vezzoli [2], Michele Sommariva [2] and Nicoletta Gagliano [2,*]

1 Hip Department (CAD) Gaetano Pini—CTO Orthopedic Institute, Università degli Studi di Milano, Piazza Cardinal Ferrari 1, 20122 Milan, Italy; filippo.randelli@fastwebnet.it
2 Department of Biomedical Sciences for Health, Università degli Studi di Milano, via Mangiagalli 31, 20133 Milan, Italy; patrizia.sartori@unimi.it (P.S.); ale.menon@me.com (A.M.); elena.vezzoli@unimi.it (E.V.); michele.sommariva@unimi.it (M.S.)
3 IRCCS Fondazione Don Carlo Gnocchi ONLUS, via Capecelatro 66, 20148 Milan, Italy; ccarlomagno@DONGNOCCHI.IT (C.C.); mbedoni@DONGNOCCHI.IT (M.B.)
4 U.O.C. 1° Clinica Ortopedica, ASST Centro Specialistico Ortopedico Traumatologico Gaetano Pini-CTO, Piazza Cardinal Ferrari 1, 20122 Milan, Italy
* Correspondence: nicoletta.gagliano@unimi.it; Tel.: +39-02-50315374

Received: 26 October 2020; Accepted: 7 December 2020; Published: 8 December 2020

Abstract: Mechanotransduction is the ability of cells to translate mechanical stimuli into biochemical signals that can ultimately influence gene expression, cell morphology and cell fate. Tenocytes are responsible for tendon mechanical adaptation converting mechanical stimuli imposed during mechanical loading, thus affecting extracellular matrix homeostasis. Since we previously demonstrated that MD-Tissue, an injectable collagen-based medical compound containing swine-derived collagen as the main component, is able to affect tenocyte properties, the aim of this study was to analyze whether the effects triggered by MD-Tissue were based on mechanotransduction-related mechanisms. For this purpose, MD-Tissue was used to coat Petri dishes and cytochalasin B was used to deprive tenocytes of mechanical stimulation mediated by the actin cytoskeleton. Cell morphology, migration, collagen turnover pathways and the expression of key mechanosensors were analyzed by morphological and molecular methods. Our findings confirm that MD-Tissue affects collagen turnover pathways and favors cell migration and show that the MD-Tissue-induced effect represents a mechanical input involving the mechanotransduction machinery. Overall, MD-Tissue, acting as a mechanical scaffold, could represent an effective medical device for a novel therapeutic, regenerative and rehabilitative approach to favor tendon healing in tendinopathies.

Keywords: tendon; tenocytes; tendinopathy; collagen turnover; mechanotransduction; actin cytoskeleton; YAP/TAZ; medical device

1. Introduction

Tendinopathy is a chronic and painful condition affecting tendons, characterized by histological modifications such as hypercellularity, neovascularization, loss of collagen fibril organization, increased proteoglycan and glycosaminoglycan contents and increased non-collagen extracellular matrix components [1,2]. The therapeutic approach for tendinopathy includes rest, ice-packs, non-steroidal anti-inflammatory drugs (NSAIDs), physiotherapy, local corticosteroid injections or biological and regenerative therapies using platelet-rich plasma (PRP) or hyaluronic acid [3]. However,

treatment of tendinopathy remains a clinical unmet need, since the available treatments did not show to have a strong efficacy and no long-term benefits were reported [2,4,5]. Therapeutic strategies are also needed in veterinary medicine to especially treat equine tendon lesions and musculoskeletal disorders [6–8]. MD-Tissue (MD) is an injectable collagen-based medical compound containing swine-derived collagen as the main component. Swine collagen has high biocompatibility with human collagen, with a very low risk of adverse effects when used in different medical applications, and it was also used to prepare collagen-based skin-like scaffolds [9]. Indeed, clinical studies reported that MD-Knee, a collagen-based medical compound very similar in terms of composition to MD, is well tolerated, and no systemic adverse events or septic complications were observed when utilized on patients [10,11]. Therefore, MD may have the potential to be used to treat tendinopathy. Moreover, since it can be utilized alone or in association with other therapeutic agents, and the lower cost compared to hyaluronic acid could favor its wider use, it may offer some advantages compared to other biological agents.

Tenocytes are specialized fibroblasts in tendon connective tissue, responsible for tendon extracellular matrix (ECM) remodeling by influencing the turnover pathways of type I collagen (COL-I), the main component of tendon ECM [12–14]. Tendons are interposed between muscles and bones and transfer forces generated by muscle contraction to the skeleton. Mechanical forces acting on tendons influence their metabolic activity and the expression of genes and proteins involved in ECM remodeling of tenocytes that play key roles acting as mechanosensors [13,15,16].

Mechanotransduction is the ability of cells to translate mechanical stimuli into biochemical signals that can ultimately influence gene expression, cell morphology and cell fate. Mechanotransduction allows cells to respond to external forces and to interpret the mechanical characteristics of the ECM. In this way, tenocytes can timely adapt to the continuous dynamic modifications of the ECM by remodeling it [17,18]. Recently, we analyzed the in vitro effect of MD on human tenocytes [19]. We focused our attention on collagen turnover pathways, in order to describe the molecular mechanisms triggered by this medical compound and to understand how it can affect tenocytes' biological properties to favor tendon homeostasis and repair [19]. In fact, in that study, we reported that MD was able to stimulate COL-I biosynthesis, secretion and maturation and to induce tenocyte proliferation and migration. Since tenocytes act as mechanosensors and it was demonstrated that MD is able to affect collagen turnover pathways and cell migration, the aim of this study was to analyze whether the effects triggered by MD were based on mechanotransduction-related mechanisms.

2. Materials and Methods

2.1. Samples

Fragments from the human Gluteus Minimus tendon were obtained from 4 patients (mean age 62.25 ± 4.57 years, 2 males and 2 females) undergoing total hip replacement through an anterior approach but without any gluteal tendon pathology (Figure 1). Patients diagnosed with great trochanter tendinopathy, affected by genetic collagen disorders, or patients diagnosed with spondyloarthritis with involvement of the affected hip or affected by psoriatic arthritis were excluded from the study, as well as drug- and alcohol-addicted patients, pregnant or breastfeeding women and patients affected by diabetes mellitus or who had taken fluoroquinolones within 30 days before the surgery.

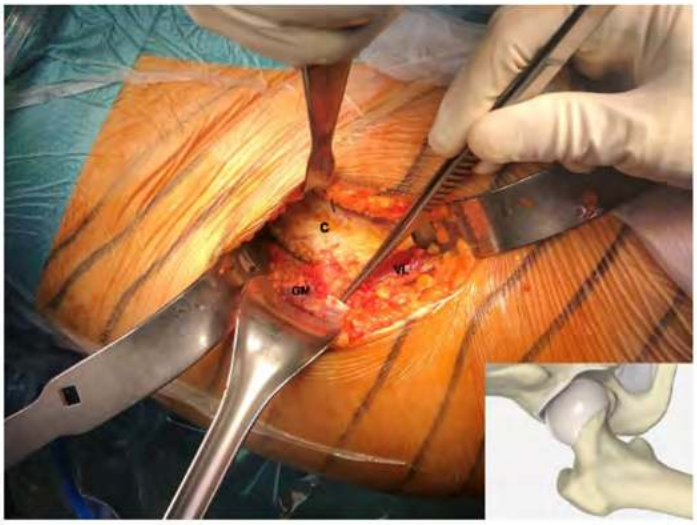

Figure 1. Harvesting a small fragment from the Gluteus Minimus (GM) tendon, indicated by the surgical forceps, during a total hip replacement through an anterior approach. The small fragment is collected at the mid-tendon substance, the white region with the typical structure of the dense regular connective tissue. The hip capsule (C) has been isolated and the Vastus Lateralis (VS) is visible at the bottom of the surgical field.

For each collected tendon, the mid-substance, the region with the typical structure of the dense regular connective tissue, was isolated and analyzed.

All subjects gave their informed consent for inclusion in the study. The study was conducted in accordance with the Declaration of Helsinki, and the protocol was approved by the local ethics committee (San Raffaele Hospital Ethical Committee, Milan, Italy) of the coordinating institution (IRCCS Policlinico San Donato, Milan, Italy) (63/INT/2017).

2.2. Cell Cultures

Tendon fragments were collected and immediately washed in sterile PBS. They were plated in T25 flasks and incubated in Dulbecco's Modified Eagle Medium (DMEM) (Euroclone, Pero, Milan, Italy) supplemented with 10% heat-inactivated fetal bovine serum (FBS) (Gibco, Life Technologies, Monza, Italy) and antibiotics (100 U/mL penicillin, 0.1 mg/mL streptomycin) (Euroclone), at 37 °C in a humidified atmosphere containing 5% CO_2. When tenocytes grew out from the explant, they were harvested and subcultured in T75 flasks. Human tenocytes derived for each subject were cultured in duplicate. For morphological, functional and molecular evaluations, confluent tenocytes were cultured in 6-well multi-well plates at the fifth passage, adding ascorbic acid (200 μM) to DMEM to preserve collagen synthesis, and harvested after 48 h. A diagram summarizing the experimental design of the study is shown in Figure 2.

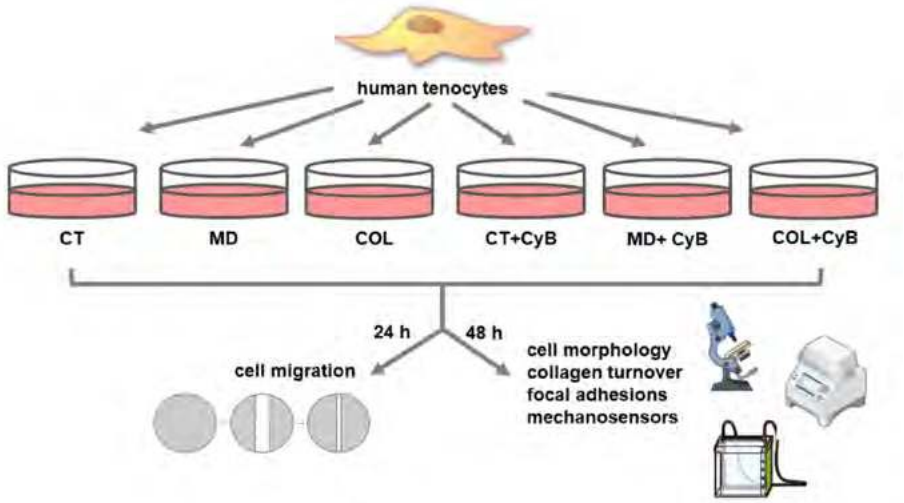

Figure 2. Diagram summarizing the experimental groups and the experimental design used in this study.

2.3. Coating with MD-Tissue or Collagen

MD (100 µg/2 mL ampoules) and collagen (COL) were kindly provided by Guna (Milan, Italy). COL is the collagen of swine origin, the principal constituent of MD, that also contains ascorbic acid, magnesium gluconate, pyridoxin hydrochloride, riboflavin, thiamine hydrochloride, NaCl and water as excipients. MD or COL (50 µg/mL) were used to obtain a thin coating on 6-well multi-well plates as previously described [19]. After an incubation of at least 3–4 h at room temperature to obtain collagen adhesion to the plastic, excess fluid was removed from the coated surface and the multi-well plate was dried under the laminar flux hood. Coated plastic was immediately used or stored at 4 °C. Cells cultured on MD-Tissue or COL were compared with cells grown on uncoated cell culture plastic, used as untreated controls (CT).

2.4. Cytochalasin Administration

To understand if MD exerts its effect on tenocytes by a mechanical stimulation, cells were treated with 10 µM cytochalasin B (CyB) (Santa Cruz Biotechnology, Heidelberg, Germany) which inhibits actin filaments polymerization. The dose of CyB used to treat tenocytes was chosen according to the literature [20]. Moreover, different doses were tested to evaluate the possible microfilament modifications leading to cytoskeleton injury.

2.5. Scanning Electron Microscopy

The coating containing MD and COL was observed with a scanning electron microscope (SEM) to detect the presence of collagen fibrils/fibers and their alignment. For this purpose, the samples were fixed with 2% glutaraldehyde and 2% paraformaldehyde buffered with 0.1 M sodium cacodylate (pH 7.3) for 1 h at room temperature. After fixation, they were rinsed three times with 0.2 M sodium cacodylate buffer (pH 7.3) for 10 min and post-fixed with 1% osmium tetroxide (OsO4) in the same buffer for 1 h on ice. Samples were rinsed twice with bi-distilled water and gradually dehydrated by consecutive 10-min incubations in 20%, 30%, 40%, 50%, 70%, 80%, 90% and 100% ethanol, followed by chemical drying with 50% (*v*/*v*) ethanol-hexamethyldisilazane (HMDS) and 100% HMDS that was air-dried overnight at room temperature. All the reagents were purchased from Electron Microscopy Sciences (Hatfield, PA, USA). Before SEM imaging, samples were mounted on 12-mm specimen stubs using double-sided carbon tape and gold coated with a 20 nm-thick film using a Polaron E5100 sputter coater. The SEM imaging was performed by a JEOL JSM-840A (Tokyo, Japan), operating at 15 kV and acquiring the secondary electron signal by an Everhart-Thornley (ET) in-chamber detector.

2.6. Raman Spectroscopy

Raman spectroscopy was used to analyze the coating containing MD or COL. Raman spectra were acquired using an Aramis Raman microscope (Horiba Jobin Yvon, France) equipped with a laser source operating at 532 nm. All the materials were analyzed in the 400–1800 cm^{-1} range, with a spectral resolution of 0.8 cm^{-1} and accumulation time of 30 s repeated on the same point for 2 accumulations. The acquisition delay time was maintained at 2 s in order to prevent the formation of artifact spectra. Before each analysis, the instrument was calibrated on the reference band of silicon at 520.7 cm^{-1}. All the samples were analyzed using a line-focused map (at least 25 points) centered using 10x, 50x and 100x objectives (Olympus, Tokyo, Japan). A laser grating of 1800, with hole at 400 and slit at 200, was used. Sample preparation was conducted depositing a 5 µL drop on a Calcium Fluoride ($CaFl_2$) disk, dried overnight at room temperature. The data processing procedure was performed following and adapting the protocol reported by Carlomagno et al. [21]. Briefly, all the spectra were fit with a third-degree polynomial baseline, considering 68 baseline points, and consecutively normalized by a unit vector. A second-degree Savitzky–Golay smoothing was applied in order to reduce noise and non-informative spikes present in the resultant spectra. All the procedures described were performed using the Raman integrated software LabSpec6 (Horiba Jobin Yvon, France) and Origin2018 (OriginLab, Northampton, MA, USA).

2.7. Immunofluorescence Analysis

For fluorescence microscopy, tenocytes were cultured on 12-mm diameter round coverslips uncoated or coated with MD or COL into 24-well culture plates, with or without CyB, as previously described [22]. For vinculin detection, cells were incubated for 1 h at room temperature with the mouse monoclonal antibody anti-vinculin (1:500 in PBS, clone VIN-11-5, Biotechne, Milan, Italy) and with the secondary antibody anti-mouse/Alexa488 (1:500, Life Technologies, Carlsbad, CA, USA). In order to analyze the actin cytoskeleton, cells were incubated with 50 µM rhodamine-phalloidin (Sigma-Aldrich, St. Louis, MO, USA).

To assess YAP/TAZ nuclear or cytoplasmic localization, cells were incubated with a rabbit anti-YAP/TAZ antibody (D24E4, 1:400, Cell Signaling, Danvers, MA, USA) and an anti-rabbit/Alexa488 (1:500, Cell Signaling, Danvers, MA, USA).

Finally, cells on coverslips were incubated with DAPI (1:100.000, Sigma Aldrich) for 15 min and mounted onto glass slides using Mowiol. Cells were analyzed and imaged by a WD THUNDER Imager Tissue 3D (Leica Microsystems CMS GmbH, Wetzlar, Germany).

2.8. Real-Time PCR

Cells were harvested and total RNA was isolated (Tri-Reagent, Sigma, Italy). One µg of total RNA was reverse-transcribed in 20 µL final volume of reaction mix (Biorad, Segrate, Milan, Italy). Gene expression for long lysyl hydroxylase 2 (LH2b), tissue inhibitor of matrix metalloproteinase 1 (TIMP-1), focal adhesion kinase (FAK) and paxillin (PAX) was analyzed by real-time RT-PCR in samples run in triplicate. Glyceraldehyde 3-phosphate dehydrogenase (GAPDH) was used as endogenous control to normalize the differences in the amount of total RNA in each sample. The primers sequences were the following: GAPDH: sense CCCTTCATTGACCTCAACTACATG, antisense TGGGATTTCCATTGATGACAAGC; LH2b: sense CCGGAAACATTCCAAATGCTCAG, antisense GCCAGAGGTCATTGTTATAATGGG; TIMP-1: sense GGCTTCTGGCATCCTGTTGTTG, antisense AAGGTGGTCTGGTTGACTTCTGG; FAK: sense GTCTGCCTTCGCTTCACG, antisense GAATTTGTAACTGGAAGATGCAAG; and PAX: sense CAGCAGACACGCATCTCG, antisense GAGCTGCTCCCTGTCTTCC. Each sample was analyzed in triplicate in a Bioer LineGene 9600 thermal cycler (Bioer, Hangzhou, China). The cycle threshold (Ct) was determined and gene expression levels relative to that of GAPDH were calculated using the ΔC_T method.

2.9. Slot Blot

Collagen type I (COL-I) and matrix metalloproteinase (MMP)-1 protein levels secreted by tenocytes in serum-free cell supernatants were analyzed by slot blot analysis, as previously detailed [18]. Membranes were incubated for 1 h at room temperature with primary monoclonal antibodies to COL-I (1:1000 in TBST) (Sigma-Aldrich, Milan, Italy) or MMP-1 (1 µg/mL in TBST) (Millipore, Milan, Italy). Immunoreactive bands were revealed by the Amplified Opti-4CN substrate (Amplified Opti-4CN, Bio Rad, Segrate, Milan, Italy) and quantification was obtained after densitometric scanning of immunoreactive bands (UVBand, Eppendorf, Italy).

2.10. Western Blot

Cells were harvested and lysed in Tris-HCl 50 mM pH 7.6, 150 mM NaCl, 1% Triton X-100, 5 mM EDTA, 1% Sodium Dodecyl Sulphate (SDS), proteases inhibitors and 1 mM sodium orthovanadate. After a 30-min incubation in ice, lysates were centrifuged at 14,000× *g* for 10 min at 4 °C. Cell lysates (15 µg of total proteins) were run on 10% SDS–polyacrylamide gel, separated under reducing and denaturing conditions at 80 V according to Laemmli and transferred at 90 V for 90 min to a nitrocellulose membrane in 0.025 M Tris, 192 mM glycine and 20% methanol, pH 8.3. For VNC analysis, membranes were incubated for 1 h at room temperature with the monoclonal antibody anti-VNC (1:2000) (clone VIN-11-5, Biotechne, Milan, Italy) and, after washing, in horseradish peroxidase (HRP)-conjugated rabbit anti-mouse antibody (1:6000 dilution, Sigma Aldrich). Immunoreactive bands were revealed using the Opti-4CN substrate (Bio Rad).

For YAP/TAZ evaluation, membranes were incubated with the following antibodies (Cell Signaling Technology, USA): YAP (D8H1X) XP® Rabbit mAb, p-YAP (S109) Rabbit Ab, TAZ (D3I6D) Rabbit mAb and p-TAZ (S89) (E1X9C) Rabbit mAb. After the incubation with a horseradish peroxidase (HRP)-conjugated goat anti-rabbit antibody (1:20000 dilution, Cell Signaling), immunoreactive bands were revealed using the Amplified Opti-4CN (Bio Rad).

To confirm equal loading, membranes were reprobed by a monoclonal antibody to α-tubulin (1:2000 dilution, Sigma Aldrich).

2.11. SDS-Zymography

MMP-2 levels and activity were analyzed in serum-free culture supernatants (5 µg of total protein per sample) in tenocytes cultured for 48 h by SDS-zymography on 10% polyacrylamide gels co-polymerized with 1 mg/mL type I gelatin. The gels were run at 4 °C and, after SDS-PAGE, they were washed twice in 2.5% Triton X-100 for 30 min each and incubated overnight in a substrate buffer at 37 °C (Tris-HCl 50 mM, $CaCl_2$ 5 mM, NaN_3 0.02%, pH 7.5). After staining and destaining the gels, MMP gelatinolytic activity was detected as clear bands on a blue background after staining the gels with Coomassie brilliant blue R250. Clear bands were quantified by densitometric scanning (UVBand, Eppendorf, Italy).

2.12. Wound Healing Assay

Cell migration of tenocytes was analyzed by a wound healing assay [23] in CT-, MD- or COL-coated 6-well multi-well plates. The "scratch" was obtained in confluent tenocytes using a p 200 pipet tip. After washing with DMEM to remove cell debris, multi-well plates were incubated in serum-free DMEM at 37 °C and observed under an inverted microscope. Migration was evaluated by measuring the closure of the wound at 0 and 24 h.

Digital images were captured by a digital camera at different time points (0 and 24 h), and the size of the "scratch" was measured to assess the migration potential, expressed as a % compared with the 0 h time point.

2.13. Statistical Analysis

Data were obtained from two replicate experiments for each of the subjects-derived cell lines cultured in duplicate and were expressed as mean ± standard deviation (SD). Statistical analysis was performed by *t*-test to compare untreated vs. CyB-treated samples cultured on the same substrate and ANOVA followed by Tukey's multiple comparisons test using GraphPad Prism v 5.0 software (GraphPad Software Inc., San Diego, CA 92108, USA). Differences associated with *p* values lower than 5% were considered statistically significant.

3. Results

3.1. Analysis and Characterization of the Coating

The presence and the characteristics of the coating obtained using MD or COL were analyzed by scanning electron microscopy (SEM). We did not detect collagen fibrils in Petri dishes coated with MD or COL (Figure 3), compared to CT. As a control, we compared MD- and COL-coated Petri dishes with a commercially available Petri dish coated with Type I collagen (CELLCOAT Type I Collagen—Greiner bio-one cod.628950), in which the presence of the coating resulted undetectable at SEM as well (Figure 3).

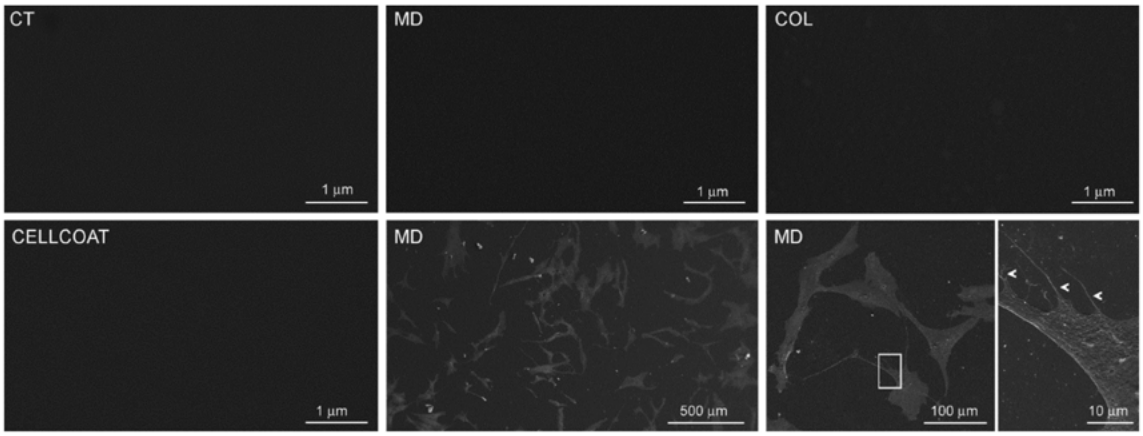

Figure 3. Scanning electron microscopy (SEM) images of Petri dish uncoated (CT) or coated with MD-Tissue (MD) or collagen (COL) solution. An SEM image of a commercial Petri dish coated with Type I collagen (CELLCOAT Type I Collagen—Greiner bio-one cod.628950) is also shown. SEM images of human tenocytes cultured on an MD Tissue-coated Petri dish at low (left) and high magnification (right); in the inset at higher magnification, the thin flattened processes extending from the cell body (arrowheads) are visible. The scale bar is shown in the bottom right corner of each image.

To understand if the coating influences cell alignment, cells were grown on 12-mm diameter coverslips coated with MD: SEM analysis confirmed that collagen fibrils are undetectable and that the coating does not induce cell alignment. Indeed, cells were arranged without any preferential direction (Figure 3).

Since the morphological analysis was not able to reveal the presence of the coating, we analyzed coated specimens by Raman spectroscopy. As described in the Materials and Methods section, MD and COL were deposited on a calcium fluoride slide and dried overnight [24]. The microscopic analysis revealed two separated regions in MD, characterized by a crystal formation and a fibrillary dispersion (Figure 4a–c). The Raman analysis was focused on these two regions (Figure 4d,e).

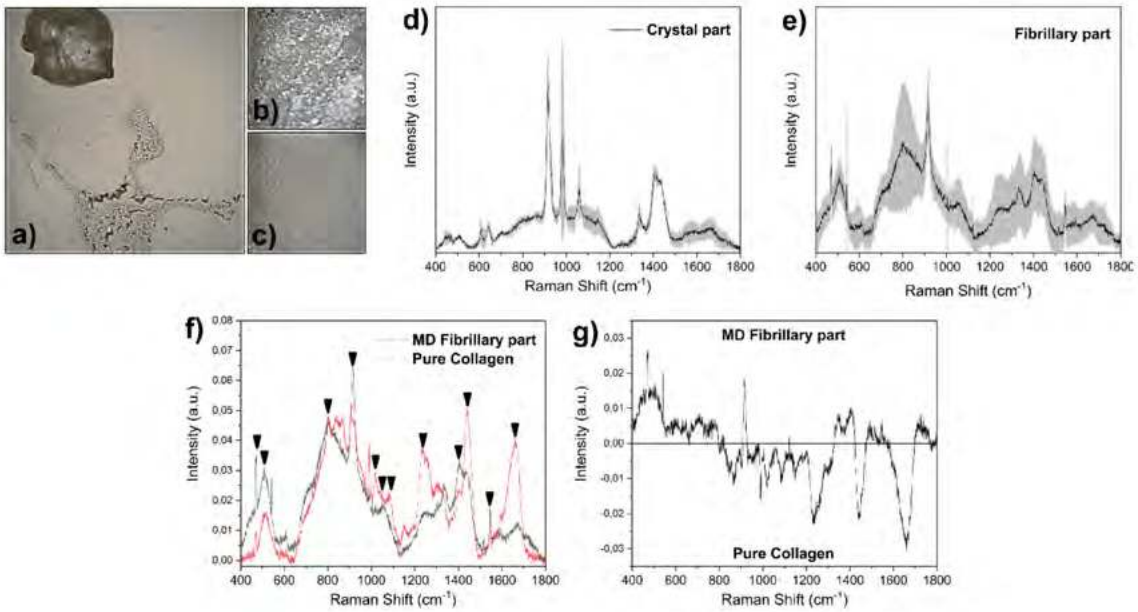

Figure 4. (**a**) Light microscopy micrograph of MD on calcium fluoride (original magnification 50×). In the insets, the crystal (**b**) and fibrillary parts (**c**) at higher magnification (100×) are shown. Raman signals collected from the (**d**) crystal and (**e**) fibrillary parts. The gray bands represent the associated standard deviation. (**f**) Comparison between pure collagen and MD fibrillary part, with peaks of interest highlighted by the black arrows. (**g**) Subtraction spectrum of MD fibrillary part and pure collagen obtained with the error propagation.

The crystal part presents the typical sharp peaks of crystal structures, with peaks attributable to the characteristic signals of riboflavin (750, 1345, 1410 cm^{-1}) and ascorbic acid (605 and 632 cm^{-1}) (Figure 4d), both present in the MD product [25,26]. The fibrillary part was mainly composed of collagen due to the presence of characteristic peaks at 536, 858, 919, 1065, 1343, 1454 and 1674 cm^{-1} (Figure 4e) [27].

The comparison between COL and the MD fibrillary part (Figure 4f) reveals common peaks at 500, 580, 829, 1248, 1430 and 1650 cm^{-1} with a partial difference in the global spectral shape. A potential explanation can be found in the presence of MD in dissolved salts in the product solution that can alter and modify the conformation, interaction with the environment and structure of the protein. As a consequence, the detected Raman signal is altered, but still consistent with the presence of collagen. The potential attribution of the main peaks (Figure 4f) is reported in Table 1. The main differences between COL and the MD fibrillary part are highlighted by the subtraction spectrum in Figure 4g. The alteration of peaks at 1235 and 1665 cm^{-1} due to the Amide I and III bands and at 1443 cm^{-1} due to the CH3 skeletal deformation indicates a change in the collagen fundamental structure of MD.

Table 1. Potential peaks attribution, based according to Carcamo et al. [23].

Raman Shift (cm^{-1})	Attribution
475	Skeletal deformations
508	Skeletal deformations
800	Skeletal C-C vibrations
920	C-COO^{-} vibrations
992	Phenylalanine
1015	Vibration of Proline C-N
1055	Distortion of Proline N-C-H
1235	Amide III

Table 1. *Cont.*

Raman Shift (cm^{-1})	Attribution
1403	Deformation of CH_3
1443	Deformation of CH_3
1544	Deformation of NH_3^+
1665	Amide I

3.2. Cell Morphology

Before analyzing the effect of MD and COL on tenocytes, we first observed the actin cytoskeleton in cells treated with different doses of CyB. Tenocytes possess long microfilaments mostly arranged in longitudinal arrays parallel to the long axis of the cells. At the concentration of 10 µM, CyB is able to block the dynamic instability of the actin cytoskeleton in order to deprive tenocytes of the mechanical stimulation mediated by actin microfilaments. At this concentration, filaments preserved their integrity and their distribution, without any evident morphological modification and without significantly damaging the mechanosensory apparatus. Higher doses strongly induce actin filaments loss, becoming progressively more evident when increasing the dose (Figure 5a). Phase contrast microscopy analysis revealed that cell morphology was unaffected in cells grown on MD and COL, compared to CT. However, when cells are treated with CyB, tenocytes cultured on MD and COL do not change their morphology, while CT cells become less flattened and more rounded (Figure 5b), suggesting that they are less attached to the substrate.

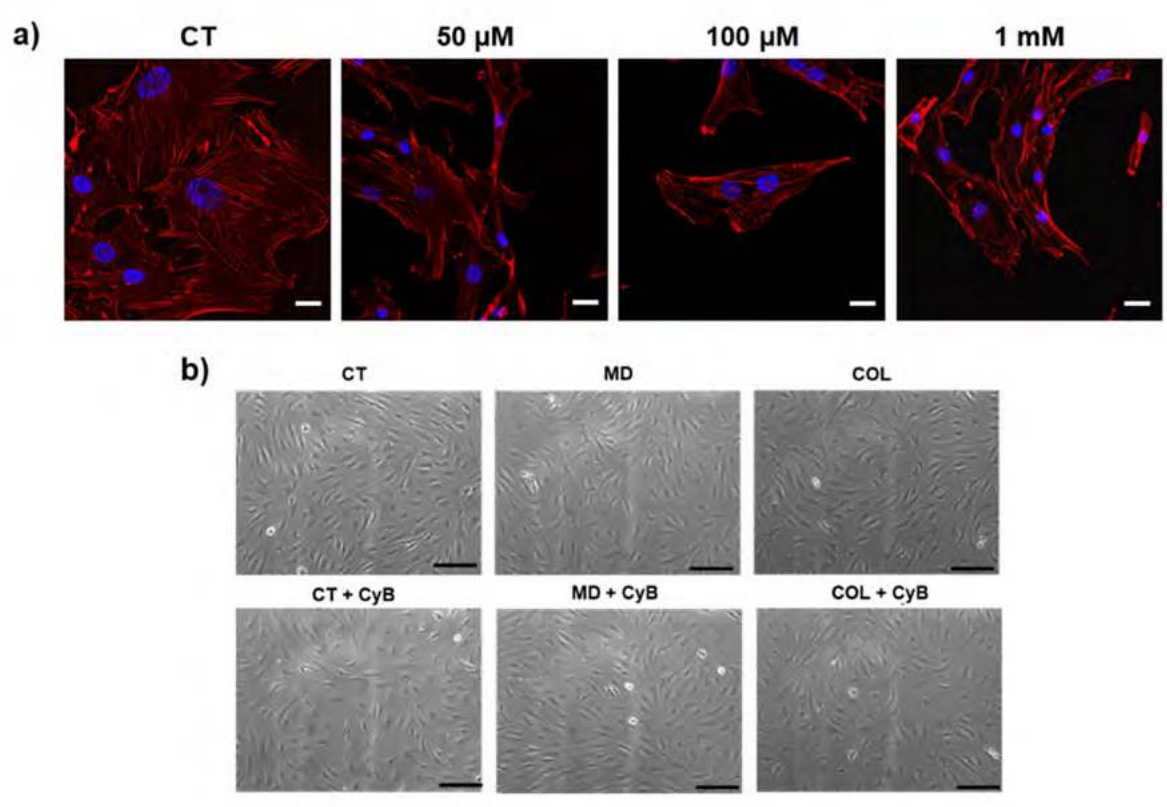

Figure 5. (**a**) Micrographs showing actin filaments detected by rodhamine-phalloidin by THUNDER in control cells (CT) and after administration of CyB at the indicated doses. After 50 µM CyB, actin filaments become shorter and more evident, indicating that the cytoskeleton is not preserved after CyB. (**b**) Representative phase contrast microscopy micrographs showing cell morphology of cells grown on MD and COL, compared to CT. After CyB, CT cells become less flattened and more rounded (Figure 4b). Scale bar 200 µm (**a**) and 20 µm (**b**).

3.3. Expression of Genes and Proteins Related to Collagen Turnover

COL-I protein levels secreted by tenocytes in cell supernatants were analyzed by slot blot. The statistical analysis using the t-test revealed a significantly increased COL-I secretion in cells cultured on MD ($p = 0.033$) and a trend of increase in cells cultured on COL ($p = 0.08$), compared to CT. CyB administration did not influence COL-I secretion by tenocytes (Figure 6a). The AVOVA p-value was statistically significant ($p = 0.0056$) and the post-test showed a significant increase in COL-I in COL vs. CT ($p = 0.041$), in COL vs. CT+CyB ($p = 0.011$) and in COL+CyB vs. CT+CyB ($p = 0.022$).

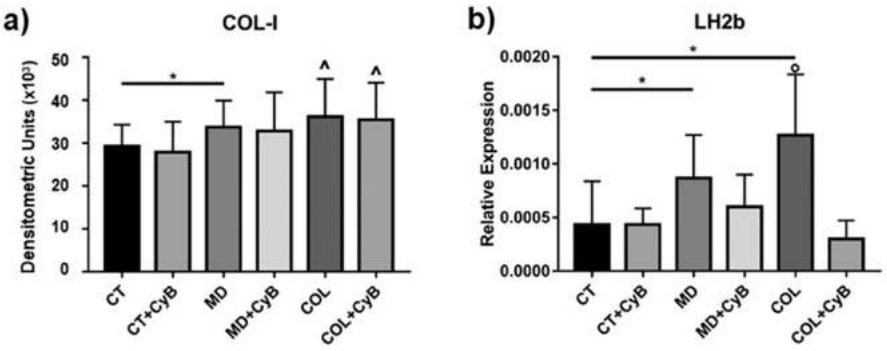

Figure 6. (**a**) Bar graphs showing COL-I protein levels obtained using slot blot after densitometric scanning of immunoreactive bands in the considered experimental conditions. Data are expressed as mean ± SD. (**b**) mRNA levels for Long lysyl hydroxylase 2 (LH2b) in CT and tenocytes cultured on MD and COL with or without CyB treatment assessed by real-time PCR. Data were normalized on GAPDH gene expression and are expressed as mean ± SD for at least two independent experiments. * $p < 0.05$ using t-test. ^ $p < 0.05$ vs. CT, CT+CyB, COL+CyB vs. CT+CyB; ° $p < 0.05$ vs. CT and COL+CyB using ANOVA.

Collagen maturation was analyzed by assessing the mRNA levels for LH2b, involved in the cross-linking of newly synthetized collagen, by real-time PCR. LH2b mRNA levels were significantly higher in tenocytes cultured on MD and COL ($p = 0.039$ and 0.020, respectively), compared to CT. CyB administration reduced LH2b gene expression in cells cultured on MD and COL ($p = 0.053$ for COL vs. COL+CyB), but not in CT (Figure 6b): this finding suggests that LH2b up-regulation induced by the coating is triggered by a mechanical stimulation mediated by the actin cytoskeleton. The ANOVA p value was 0.0095 and the post-test confirmed the induction of LH2b in COL compared with CT ($p = 0.025$) and revealed a significant decrease in COL+CyB vs. COL (p=0.025).

Interstitial collagen degradation is driven by MMP-1. Slot blot analysis of MMP-1 levels in cell culture supernatants revealed that this collagenase remained unaffected in tenocytes cultured on MD and COL, compared to CT, as well as after CyB administration (Figure 7a,c). A similar pattern of expression was observed for MMP-2 gelatinolytic activity, assessed by SDS-zymography (Figure 7b,d). A similar pattern was also observed for TIMP-1, the main inhibitor of MMP-1, analyzed at the gene expression level by real-time PCR. TIMP-1 mRNA levels revealed wide interindividual differences and were similarly modified by CyB in all the experimental groups (Figure 7e).

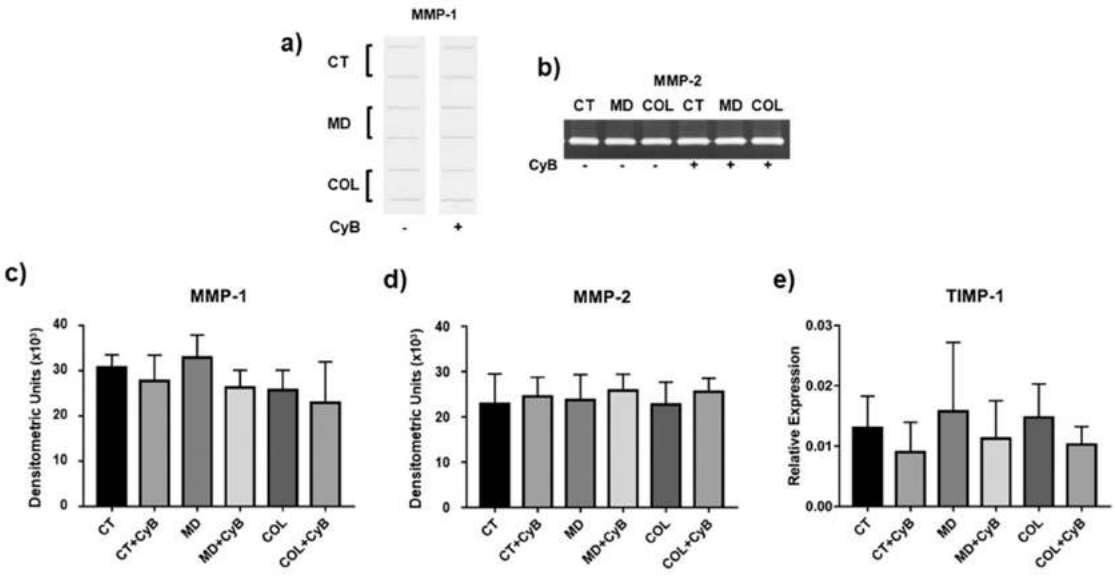

Figure 7. Representative slot blot for matrix metalloproteinase-1 (MMP-1) levels (**a**) and representative SDS-zymography showing MMP-2 activity (**b**) assayed in serum-free cell supernatants of tenocytes cultured in the considered experimental settings. Bar graphs showing MMP-1 protein levels (**c**) and MMP-2 activity (**d**) after densitometric analysis of immunoreactive and lytic bands, respectively. Data are expressed as means ± SD for at least two independent experiments. (**c**,**e**) Bar graphs showing TIMP-1 gene expression after normalization on GAPDH mRNA levels. Data are expressed as mean ± SD for at least two independent experiments.

3.4. Cytoskeleton Arrangement and Vinculin Expression in Focal Adhesions

In order to understand whether MD or COL may represent a mechanical stimulation able to influence the ability of tenocytes to form focal adhesions, we analyzed the expression of VNC, a key protein involved in the formation of the adhesion plaque, by morphological and molecular methods. Western blot analysis showed that VNC protein levels were significantly up-regulated in cells grown on MD (MD vs. CT, $p = 0.033$) and tended to increase also in cells cultured on COL. In this experimental group, VNC was significantly decreased by CyB treatment (COL vs. COL+CyB, $p = 0.040$) (Figure 8a,b). The effects of the presence of the scaffold and of CyB administration were more evident using morphological analysis by immunofluorescence. Indeed, VNC immunoreactivity, localized at the extremities of actin filaments in correspondence with focal adhesion formation on the substrate, was found to be stronger and wider in tenocytes grown on MD and COL, compared to CT (Figure 8c). After CyB administration, the VNC immunofluorescence signal and the regions corresponding to the presence of the focal adhesion seemed less evident and smaller only in cells grown on MD and COL, but not in CT, becoming similar to CT (Figure 8c, arrows).

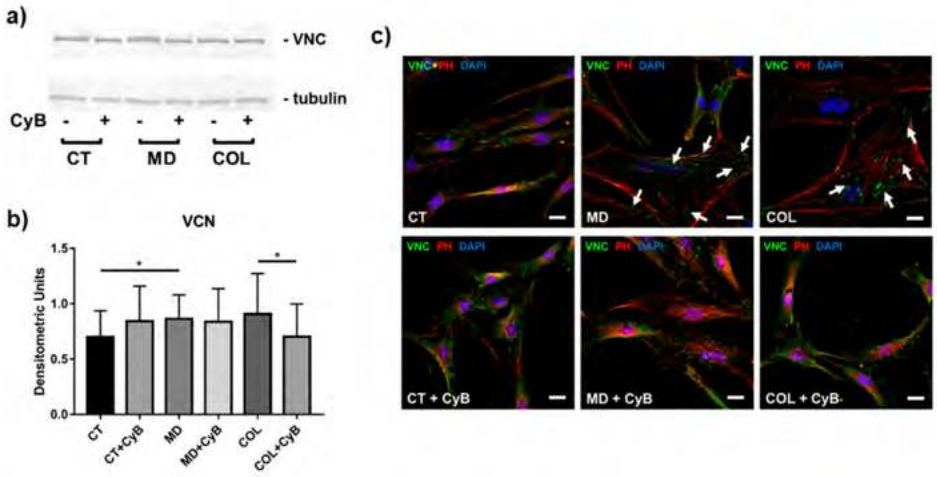

Figure 8. (**a**) Representative Western blot for VNC quantification in cell lysates obtained from tenocytes cultured on MD and COL, compared to CT, with or without CyB treatment. VNC expression was normalized on tubulin. (**b**) Bar graphs showing VCN expression after densitometric analysis of immunoreactive bands. Data are mean ± SD for at least two independent experiments. (**c**). Immunofluorescence analysis for VNC (green) in tenocytes cultured on MD and COL, compared to CT, before and after CyB treatment. Actin filaments are stained using rhodamine-phalloidin labeling. Nuclei are stained in blue by DAPI. Original magnification: 60×. White arrows point to larger and more evident VNC-containing focal adhesions observed in MD and COL samples, compared to the same samples treated with CyB. CyB modified the size of VCN-containing focal adhesions similarly to CT. VNC: vinculin; PH: phalloidin. Scale bar: 20 μm. * $p < 0.05$ using *t*-test.

3.5. Wound Healing Assay

Cell migration, playing a key role during tendon healing, was assessed by a wound healing assay in tenocytes grown on CT, MD and COL with or without CyB administration. The quantification of the scratch size revealed that cell migration is significantly increased in tenocytes cultured on MD and COL, compared to CT ($p = 0.023$ and $p = 0.032$, respectively). Conversely, cell migration remained unaffected by CyB treatment in CT, but was strongly reduced in MD (MD vs. MD+CyB, $p = 0.040$) and, although not statistically significant, in COL tenocytes (COL vs. COL+CyB, $p = 0.07$) (Figure 9a,b). The ANOVA *p* value was 0.001 and the post-test confirmed the increased migration induced by COL compared to CT ($p = 0.015$) and revealed a significant increase in the migration of cells cultured on MD or COL compared to CT+CyB ($p = 0.009$ and $p = 0.001$, respectively).

3.6. Expression of FAK, PAX and YAP/TAZ as Mechanosensors

To understand if the scaffold containing MD and COL affects tenocytes biology by a mechanical stimulation, the expression of key proteins playing a role as mechanosensors was analyzed.

FAK and PAX are proteins in the adhesion plaque that also act as mechanosensors. Their mRNA levels tended to be up-regulated in tenocytes cultured on MD and COL compared to CT, although not reaching the statistical significance ($p = 0.09$). CyB treatment did not affect FAK in CT but had an impact on its expression in cells cultured on MD ($p = 0.09$) and COL, determining its reduction (Figure 10a). The ANOVA revealed that FAK mRNA levels are up-regulated in MD vs. CT ($p = 0.017$) and vs. CT+CyB ($p = 0.020$) and that they are decreased in MD vs. MD+CyB ($p = 0.013$) and COL+CyB ($p = 0.018$). A similar pattern was observed for PAX: its expression was higher in MD ($p = 0.075$) and COL, compared with CT, and was reduced by CyB only in cells cultured on the scaffold ($p = 0.07$ for MD vs. MD+CyB and $p < 0.05$ for COL vs. COL+CyB), whilst it remained unchanged in CT (Figure 10b). The analysis of PAX gene expression by ANOVA showed that its expression was significantly increased in MD vs. CT and vs. CT+CyB ($p = 0.0059$ and $p = 0.052$, respectively), while it was reduced in MD+CyB ($p = 0.003$) and COL+CyB ($p = 0.007$) compared to MD.

Yes-associated protein (YAP) and transcriptional co-activator with PDZ-binding motif (TAZ) are mechanosensors whose activity is regulated by phosphorylation, leading to protein inactivation and cytoplasmic translocation. YAP/TAZ were first analyzed by Western blot using antibodies to detect both the unphosphorylated (active) and phosphorylated (inactive) proteins. YAP and p-YAP resulted in being similarly expressed in cell lysates obtained from CT, MD and COL tenocytes, although a significant down-regulation was observed after CyB administration in cells cultured on MD ($p = 0.044$) (Figure 10c). p-YAP resulted in being similar in all the experimental conditions (Figure 10d) as well as the YAP/p-YAP ratio (Figure 10e). A similar pattern was observed for TAZ and p-TAZ (data not shown).

In order to understand whether MD or COL were able to trigger a mechanical stimulation in tenocytes, YAP/TAZ activation induced by the scaffold was investigated by analyzing their localization by immunofluorescence analysis. YAP/TAZ were expressed both in nuclei and the cytoplasm. We observed a stronger nuclear immunoreactivity in tenocytes cultured on MD and COL, compared to CT. In CT, CyB did not significantly modify this pattern of expression, whilst in tenocytes cultured on MD and COL, CyB strongly increased the number of nuclei having a less intense YAP/TAZ labeling (Figure 11): this finding suggests that mechanical stimulus deprivation following CyB administration inactivated YAP/TAZ and induced their translocation from the nucleus to the cytoplasm.

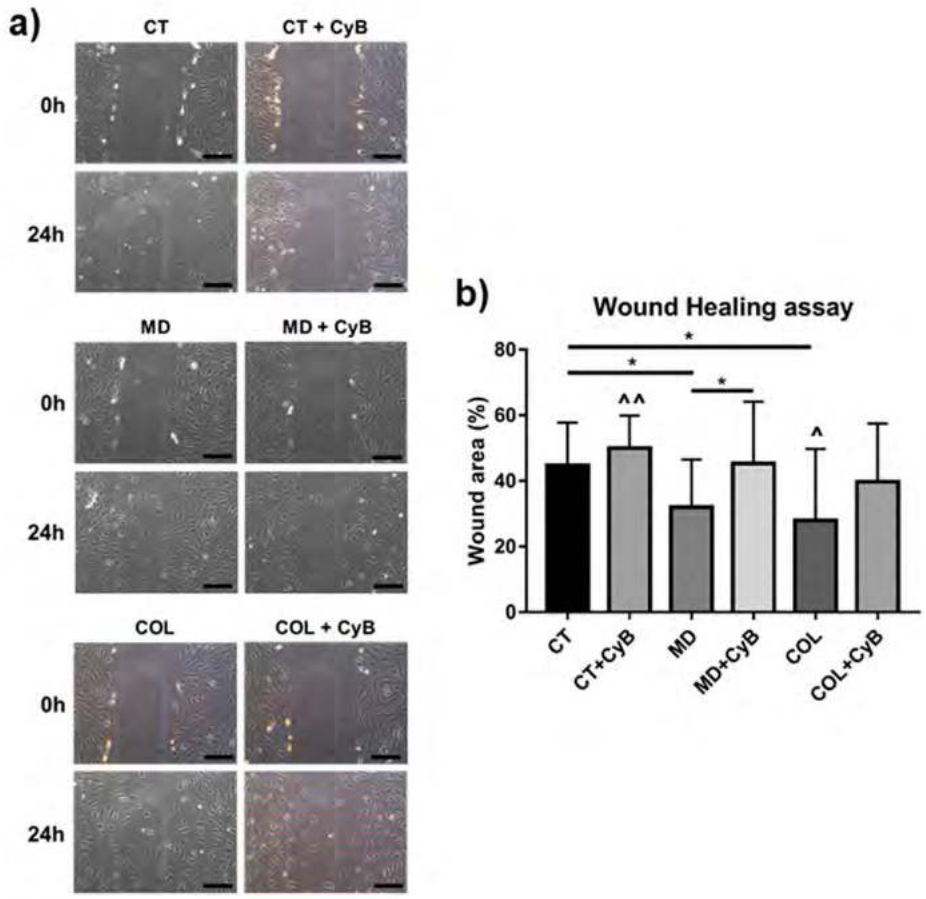

Figure 9. (**a**) Representative phase contrast micrographs showing the results of the wound healing assay in control tenocytes (CT) and tenocytes grown on MD and COL at 0 and 24 h after the scratch, with or without CyB administration. Original magnification: 10×. (**b**) Bar graphs showing the area of wound closure after 24 h, expressed as a % of the area at 0 h, in cultured tenocytes in the different experimental conditions. Data are mean ± SD for at least two independent experiments. * $p < 0.05$ for *t*-test; ^ $p < 0.05$ vs. CT; ^^ $p < 0.01$ vs. MD and COL using ANOVA.

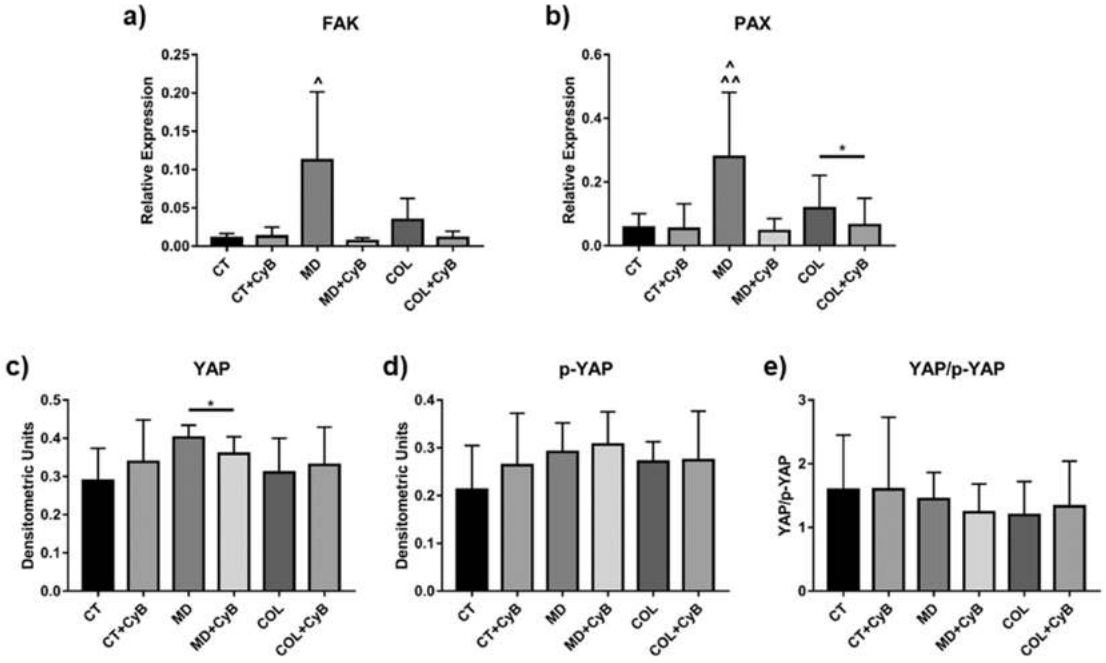

Figure 10. Bar graphs showing FAK (**a**) and PAX (**b**) mRNA levels after normalization on GAPDH gene expression. Data are means ± SD for at least two independent experiments. For YAP expression, the active-form YAP (**c**), the inactive phosphorylated form (**d**) and the YAP/p-YAP ratio (**e**) were assessed by Western blot and represented by the histograms showing mean ± SD for at least two independent experiments for the considered experimental groups. * $p < 0.05$ for *t*-test; ^ $p < 0.05$ vs. CT, CT+CyB, MD+CyB, COL+CyB; ^^ $p < 0.01$ vs. MD+CyB and COL+CyB using ANOVA.

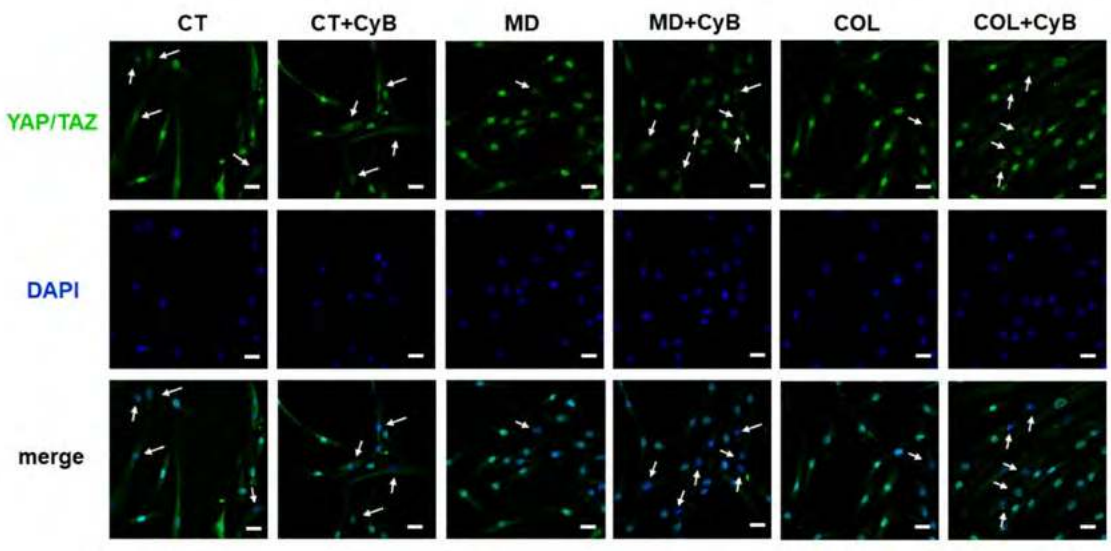

Figure 11. Immunofluorescence analysis for YAP/TAZ (green) in tenocytes cultured on MD and COL, compared to CT, before and after CyB treatment. The merged micrographs show that in tenocytes cultured on MD and COL, immunoreactivity is more evident in the nucleus, while, after CyB treatment and in CT, immunoreactivity is mostly in the cytoplasm and nuclei are more blue, suggesting that the presence of MD and COL induces YAP/TAZ activation, while mechanical stress deprivation induces a phenotype more similar to CT cells. Original magnification: 60×. Scale bar: 20 µm.

4. Discussion

The mechanobiology of tenocytes is vital to preserve tendon homeostasis [28–31]. Tenocytes are able to sense mechanical stimuli imposed on tendons during mechanical loading and can adapt their metabolism in an anabolic or catabolic manner in order to remodel the ECM according to the applied loads [32–34]. Therefore, tenocytes are responsible for tendon mechanical adaptation: they convert mechanical stimuli into biochemical signals that ultimately influence tendon adaptive physiological or pathological changes, thus affecting its biomechanical properties [13,15,16]. In fact, it was reported that physiological mechanical loading increases collagen synthesis [14,35], while reduced loading leads to MMP-1 up-regulation [36].

Tensile loading acting on tendons is transduced into intracellular biochemical responses by various sensors and pathways, and the propagation of extracellular-generated forces rely on the actin cytoskeleton [37]. Actin filaments mediate the modification and deformation of the ECM and contribute to the propagation of mechanical stimulation to the nucleus, where gene expression for ECM components can be accordingly affected [38]. It has been demonstrated that the deprivation of mechanical stimulation on tendons mediated by the actin cytoskeleton can be obtained by CyB treatment [36]. Therefore, in order to understand if MD acts as a mechanical scaffold, we utilized CyB to analyze if the effects elicited by MD or COL on tenocytes behavior are affected by mechanical loading deprivation.

For this purpose, we first analyzed the scaffold containing MD and COL at SEM to evaluate if the substrate arrangement could influence cell alignment. The observation at SEM of Petri dishes coated with MD or COL did not reveal the presence of collagen fibrils, possibly due to a fragmentation into small fragments of the collagen contained in the device. As a consequence, when cultured on the scaffold, cells were not influenced in their arrangement and grew without any specific distribution. To support our findings, a further SEM analysis conducted on a commercial Petri dish coated with type I collagen confirmed that collagen fibrils are undetectable. Since, in our previous study, we showed that MD was able to modify some biological activities of tenocytes [19], we tried to demonstrate the presence of the scaffold using a different approach such as Raman spectroscopy. Using this technique, we were able to assess the presence of mainly type I collagen in MD prepared to culture tenocytes.

After demonstrating the presence of the scaffold, we investigated collagen turnover, since COL-I is the main component of the tendon ECM. Its content is regulated by a finely balanced turnover controlled by tenocytes acting at the level of collagen synthesis, maturation and degradation. Collagen turnover, therefore, plays a key role in determining the tendon ability to resist mechanical forces and repair in response to injury [9]. We previously demonstrated that MD favors COL-I secretion [19], suggesting that this medical compound is able to trigger the anabolic phenotype of tenocytes. In the present study, our results confirm the increase in COL-I protein levels in the supernatant of tenocytes cultured on MD and COL, compared to CT. Since CyB administration had no effect on collagen expression in all experimental groups, there is not a clear demonstration that the effect of the scaffold on COL-I expression is mechanically induced and mediated by the actin cytoskeleton.

Maturation of newly synthesized collagen is needed to provide collagen fibril stabilization and tendon tensile strength and is obtained by the cross-linking of newly secreted collagen by enzymes such as LH2b [39,40]. Our results show that LH2b is up-regulated by MD, and also by COL, in tenocytes cultured for 48 h, as previously demonstrated [19]. Interestingly, this effect was lost after CyB administration only in tenocytes cultured on MD and COL, but not in CT, pointing to a mechanical mechanism exerted by MD to trigger collagen maturation to improve collagen stability.

Collagen turnover pathways include collagen breakdown played by MMP-1, which cleaves the intact collagen triple helix, followed by other proteases such as MMP-2 [41,42]. The key role of MMP-1 in tendon ECM homeostasis is based on the previously demonstrated inverse correlation between MMP-1 expression at the gene and protein levels and the amplitude of tensile mechanical load acting on tendons. In fact, low levels of MMP-1 induced by mechanical loading are related to a more stable tendon structure [36]. Here, we show that MMP-1 and MMP-2 levels are not affected by MD and

COL, and they remain unchanged by CyB administration. When investigating collagen degradation, TIMPs expression should be also analyzed. TIMP-1 is the main inhibitor of MMP-1, binding MMP-1 in a 1:1 stoichiometric ratio and inhibiting its activation and activity [43,44]. TIMP-1 mRNA levels slightly increased in tenocytes cultured for 48 h on MD and COL, compared to CT, as previously reported [19], and were reduced after CyB administration in all the considered experimental groups. This finding suggests that, in our experimental conditions, TIMP-1 levels are not under specific mechanical control mediated by the actin cytoskeleton. Overall, collagen turnover mechanisms involving the activity of MMP-1, MMP-2 and TIMP-1 seem to be unaffected by CyB.

ECM remodeling and homeostasis are influenced by mechanical stimuli acting on tendons and tenocytes are mechanoresponsive cells: they play a key role as the effectors since they are able to sense mechanical signals and convert them into biological responses [45,46]. This activity of tenocytes is based on their actin microfilaments that represent a mechanotransduction system allowing to adapt tenocyte metabolism in response to different mechanical forces acting on tendons [36]. CyB is known to modify the dynamic instability of actin filaments. However, as shown in Figure 8, the dose of CyB used in this study did not injure microfilaments and tenocytes preserved their structural integrity.

The actin cytoskeleton also plays a key role during cell migration. Since tenocytes migration is needed during tendon healing [47], we investigated, by a wound healing assay, if MD and COL affect cell migration and if their effect relies on a mechanoresponsive mechanism influenced by CyB treatment. We found that MD favors cell migration, as previously reported [19], as well as COL, confirming that the therapeutic activity of this medical device could be related to this effect. To demonstrate that MD-induced cell migration is triggered by a mechanotransduction system, the wound area was measured after CyB administration. Interestingly, CyB was able to decrease cell migration in tenocytes cultured on MD and COL, but not in CT, strongly suggesting that the stimulation of cell migration induced by MD is mediated by a mechanical effect.

During the dynamic process of cell migration, cells undergo a repeated cycle of attachment to the ECM and subsequent detachment of the cell from the matrix. Transmembrane proteins, the integrins, mediate the attachment of tenocytes to the ECM and bridge the inside and outside of the cells. To do this, they link their cytoplasmic domain to the focal adhesion complexes at the leading edge of the cell, including many different proteins such as VNC, a cytoplasmic actin-binding protein enriched in focal adhesions [48–50]. Interestingly, the presence of VNC at adhesion complexes is force-dependent [50]. Western blot analysis of VNC revealed some significant modifications induced by the medical device before and after CyB treatment. However, more interesting findings were obtained by morphological analysis using immunofluorescence, which revealed some qualitative differences in cells cultured on MD and COL, compared to CT. In fact, VNC immunoreactivity detectable at the extremity of microfilaments and the size of focal adhesions containing VNC seem more evident and larger in cells grown on the medical device, compared to CT. This observation suggests the hypothesis that VNC expression can be affected by MD and COL, and that the medical devices could improve the attachment of tenocytes to ECM components and, therefore, their ability to form more efficient focal adhesions to favor cell migration. This hypothesis is supported by the observation that, after CyB administration, focal adhesions of cells cultured on MD and COL are similar to those observed in CT. Accordingly, it was reported that VNC recruitment is enhanced when tension increases, while, when tension decreases, focal adhesions are disassembled in response to decreased tension [50]. Moreover, the analysis with the phase contrast microscope revealed that cell morphology was similar in tenocytes grown on CT, MD and COL. By contrast, CyB induced a less flattened morphology in CT, confirming the hypothesis that the medical device is able to favor cell adhesion and thus cell migration.

To finally demonstrate that MD affects tenocyte behavior representing a mechanical stimulus acting on mechanotransduction mechanisms, we analyzed the effect of the medical device on the expression of key mechanosensors such as FAK, PAX and YAP/TAZ. FAK and PAX are components of the adhesion plaque complex. They are involved in the formation of focal adhesions needed for cell migration but they also play a key role acting as mechanosensors [51–53]. Our data show that FAK

and PAX gene expression is strongly influenced by MD as well as by COL, compared to CT. When CyB is added to the cell culture medium for 48 h, FAK and PAX mRNA levels are down-regulated only in tenocytes grown on MD and COL, and not in CT. This finding suggests that their induction is dependent on the mechanical stimulus exerted by the medical device used as a scaffold. Moreover, this effect is lost when the transmission of the mechanical stimulus on tenocytes is blocked when cells are deprived of their mechanotransduction apparatus. To strengthen this hypothesis, we analyzed the expression of the transcriptional regulators YAP/TAZ, which are regulated by mechanical inputs in a variety of cellular settings, thus impacting many different cell activities [51]. YAP and TAZ act as mechanosensors primarily regulated by the substrate on which cells adhere, which, in turn, influences YAP/TAZ activity stimulating the actin cytoskeleton. The integrity of microfilaments is pivotal on YAP/TAZ activity. In fact, treatment of cells with Latrunculin A, an inhibitor of actin polymerization, results in phosphorylation of YAP and cytosolic localization of YAP/TAZ [51]. In this study, we used CyB to inhibit actin polymerization and to block its dynamic instability in order to analyze YAP/TAZ expression in tenocytes cultured on MD and COL, compared to CT, to demonstrate that the medical device represents a mechanical stimulus to affect cell behavior.

Western blot analysis of YAP/TAZ did not reveal important differences as well as in the YAP/p-YAP ratio. However, our data suggest that MD and COL represent a mechanical input for tenocytes since immunofluorescence analysis demonstrated that YAP/TAZ expression is more nuclear in cells cultured on MD and COL, compared to CT. This suggestion is further supported by the observation that after CyB administration, depriving cells of the mechanical input mediated by the cytoskeleton, YAP/TAZ immunoreactivity becomes less nuclear and more cytoplasmic only in cells grown on MD and COL, and not in CT. This suggestion is consistent with previous studies demonstrating that, since YAP/TAZ serve as mechanotransducers and mechanosensors, their subcellular localization and activity are tightly regulated by cell substrate rigidity and tensile inputs from the ECM [53–55], and that cytoskeletal tension is required for YAP/TAZ nuclear localization [53].

5. Conclusions

Considered as a whole, these in vitro findings suggest that MD and COL trigger similar responses in tenocytes and that their effect on tenocytes behavior represents a mechanical input involving the mechanotransduction machinery. In particular, we showed that MD-Tissue influences some tenocytes activity involved in ECM homeostasis and improves focal adhesion formation and migration ability. Overall, we confirm that MD-Tissue, acting as a mechanical scaffold, could be an effective medical device used as a novel therapeutic, regenerative and rehabilitative approach to favor tendon healing in tendinopathies.

Author Contributions: Conceptualization, N.G.; methodology, N.G., P.S., C.C., E.V.; investigation, F.R., P.S., C.C., M.B., A.M., E.V., M.S., N.G.; data curation, N.G.; writing—original draft preparation, N.G..; writing—review and editing, F.R., P.S., C.C., M.B., A.M., E.V., M.S., N.G; funding acquisition, N.G. and F.R. All authors have read and agreed to the published version of the manuscript.

Funding: This study was partially supported by Guna S.p.a. The funder had no role in the design or conduct of the study, in analysis and interpretation of data or in the preparation of the manuscript.

Acknowledgments: We would like to thank Vincenzo Conte (Department of Biomedical Sciences for Health, Università degli Studi di Milano) for his help in electron microscopy analysis.

Conflicts of Interest: The authors declare that the manuscript is free of conflict of interest. This study was partially supported by Guna S.p.a. The sponsor had no role in the design or conduct of the study, in analysis and interpretation of data, in preparation of the manuscript or in the decision to publish the results of the study.

References

1. Via, A.G.; Papa, G.; Oliva, F.; Maffulli, N. Tendinopathy. *Curr. Phys. Med. Rehabil. Rep.* **2016**, *4*, 50–55. [CrossRef]
2. Steinmann, S.; Pfeifer, C.G.; Brochhausen, C.; Docheva, D. Spectrum of tendon pathologies: Triggers, trails and end-state. *Int. J. Mol. Sci.* **2020**, *21*, 844. [CrossRef] [PubMed]
3. Reid, D. The management of greater trochanteric pain syndrome: A systematic literature review. *J. Orthop.* **2016**, *13*, 15–28. [CrossRef] [PubMed]
4. Frizziero, A.; Vittadini, F.; Pignataro, A.; Gasparre, G.; Biz, C.; Ruggieri, P.; Masiero, S. Conservative management of tendinopathies around hip. *Muscles Ligaments Tendons J.* **2016**, *6*, 281–292. [CrossRef] [PubMed]
5. Seo, K.H.; Lee, J.Y.; Yoon, K.; Do, J.G.; Park, H.J.; Lee, S.Y.; Park, Y.S.; Lee, Y.T. Long-term outcome of low-energy extracorporeal shockwave therapy on gluteal tendinopathy documented by magnetic resonance imaging. *PLoS ONE* **2018**, *13*, e019746. [CrossRef] [PubMed]
6. Patruno, M.; Martinello, T. Treatments of the injured tendon in Veterinary Medicine: From scaffolds to adult stem cells. *Histol. Histopathol.* **2014**, *29*, 417–422. [CrossRef]
7. Haltmayer, E.; Ribitsch, I.; Gabner, S.; Rosser, J.; Gueltekin, S.; Peham, J.; Giese, U.; Dolezal, M.; Egerbacher, M.; Jenner, F. Co-culture of osteochondral explants and synovial membrane as in vitro model for osteoarthritis. *PLoS ONE* **2019**, *14*, e0214709. [CrossRef]
8. O'Brien, C.; Marr, N.; Thorpe, C. Microdamage in the equine superficial digital flexor tendon. *Equine Vet. J.* **2020**, 1–14. [CrossRef]
9. Ferrario, C.; Rusconi, F.; Pulaj, A.; Macchi, R.; Landini, P.; Paroni, M.; Colombo, G.; Martinello, T.; Melotti, L.; Gomiero, C.; et al. from food waste to innovative biomaterial: Sea urchin-derived collagen for applications in skin regenerative medicine. *Mar. Drugs* **2020**, *18*, 414. [CrossRef]
10. Martin, L.S.; Massafra, U.; Bizzi, E.; Migliore, A. A double blind randomized active-controlled clinical trial on the intra-articular use of Md-Knee versus sodium hyaluronate in patients with knee osteoarthritis ("Joint"). *BMC Musculoskelet. Disord.* **2016**, *17*, 94. [CrossRef]
11. Pavelka, K.; Jarosova, H.; Sleglova, O.; Svobodova, R.; Votavova, M.; Milani, L.; Prochazka, Z.; Kotlarova, L.; Kostiuk, P.; Sliva, J.; et al. Chronic low back pain: Current pharmacotherapeutic therapies and a new biological approach. *Curr. Med. Chem.* **2018**, *25*, 1–8. [CrossRef]
12. Kannus, P. Structure of the tendon connective tissue. *Scand. J. Med. Sci. Sports* **2000**, *10*, 312–320. [CrossRef]
13. Kjaer, M. Role of extracellular matrix in adaptation of tendon and skeletal muscle to mechanical loading. *Physiol. Rev.* **2004**, *84*, 649–698. [CrossRef]
14. Riley, G.P.; Harrall, R.L.; Constant, C.R.; Chard, M.D.; Cawston, T.E.; Hazleman, B.L. Glycosaminoglycans of human rotator cuff tendons: Changes with age and in chronic rotator cuff tendinitis. *Ann. Rheum. Dis.* **1994**, *53*, 367–376. [CrossRef] [PubMed]
15. Banes, A.J.; Horesovsky, G.; Larson, C.; Tsuzaki, M.; Judex, S.; Archambault, J.; Zernicke, R.; Herzog, W.; Kelley, S.; Miller, L. Mechanical load stimulates expression of novel genes in vivo and in vitro in avian flexor tendon cells. *Osteoarthr. Cartil.* **1999**, *7*, 141–153. [CrossRef] [PubMed]
16. Benjamin, M.; Ralphs, J.R. The cell and developmental biology of tendons and ligaments. *Int. Rev. Cytol.* **2000**, *196*, 85–130. [CrossRef]
17. Jansen, K.A.; Donato, D.M.; Balcioglu, H.E.; Schmidt, T.; Danen, E.H.; Koenderink, G.H. A guide to mechanobiology: Where biology and physics meet. *Biochim. Biophys. Acta* **2015**, *1853*, 3043–3052. [CrossRef] [PubMed]
18. Lavagnino, M.; Wall, M.E.; Little, D.; Banes, A.J.; Guilak, F.; Arnoczky, S.P. Tendon mechanobiology: Current knowledge and future research opportunities. *J. Orthop. Res.* **2015**, *33*, 813–822. [CrossRef]
19. Randelli, F.; Menon, A.; Via, A.G.; Mazzoleni, M.G.; Sciancalepore, F.; Brioschi, M.; Gagliano, N. Effect of a collagen-based compound on morpho-functional properties of cultured human tenocytes. *Cells* **2018**, *7*, 246. [CrossRef]
20. Canty, E.G.; Starborg, T.; Lu, Y.; Humphries, S.M.; Holmes, D.F.; Meadows, R.S.; Huffman, A.; O'Toole, E.T.; Kadler, K.E. Actin filaments are required for fibripositor-mediated collagen fibril alignment in tendon. *J. Biol. Chem.* **2006**, *281*, 38592–38598. [CrossRef]

21. Carlomagno, C.; Banfi, P.I.; Gualerzi, A.; Volpato, E.; Meloni, M.; Lax, A.; Colombo, E.; Ticozzi, N.; Verde, F.; Silani, V.; et al. Human salivary Raman fingerprint as biomarker for the diagnosis of Amyotrophic Lateral Sclerosis. *Sci. Rep.* **2020**, *10*, 10175. [CrossRef] [PubMed]
22. Menon, A.; Pettinari, L.; Martinelli, C.; Colombo, G.; Portinaro, N.; Dalle-Donne, I.; d'Agostino, M.C.; Gagliano, N. New insights in extracellular matrix remodeling and collagen turnover related pathways in cultured human tenocytes after ciprofloxacin administration. *Muscle Ligaments Tendons J.* **2013**, *113*, 122–131.
23. Liang, C.C.; Park, A.Y.; Guan, J.L. In vitro scratch assay: A convenient and inexpensive method for analysis of cell migration in vitro. *Nat. Protoc.* **2007**, *2*, 329–333. [CrossRef] [PubMed]
24. Gualerzi, A.; Niada, S.; Giannasi, C.; Picciolini, S.; Morasso, C.; Vanna, R.; Rossella, V.; Masserini, M.; Bedoni, M.; Ciceri, F.; et al. Raman spectroscopy uncovers biochemical tissue-related features of extracellular vesicles from mesenchymal stromal cells. *Sci. Rep.* **2017**, *7*, 9820. [CrossRef]
25. Cullum, B.M.; Boca, S.; Rugina, D.; Pintea, A.; Leopold, N.; Astilean, S. Designing gold nanoparticle-ensembles as surface enhanced raman scattering tags inside human retinal cells. *J. Nanotechnol.* **2012**, 961216. [CrossRef]
26. Bailey, M.R.; Schultz, Z.D. SERS speciation of the electrochemical oxidation–reduction of riboflavin. *Analyst* **2016**, *141*, 5078–5087. [CrossRef]
27. Cárcamo, J.J.; Aliaga, A.E.; Clavijo, R.E.; Brañes, M.R.; Campos-Vallette, M.M. Raman study of the shockwave effect on collagens. *Spectrochim. Acta Part A Mol. Biomol. Spectrosc.* **2012**, *86*, 360–365. [CrossRef]
28. Hannafin, J.A.; Arnoczky, S.P.; Hoonjan, A.; Torzilli, P.A. Effect of stress deprivation and cyclic tensile loading on the material and morphologic properties of canine flexor digitorum profundus tendon: An in vitro study. *J. Orthop. Res.* **1995**, *13*, 907–914. [CrossRef]
29. Galloway, M.T.; Lalley, A.L.; Shearn, J.T. The role of mechanical loading in tendon development, maintenance, injury, and repair. *J. Bone Jt. Surg. Am.* **2013**, *95*, 1620–1628. [CrossRef]
30. Magnusson, S.P.; Langberg, H.; Kjaer, M. The pathogenesis of tendinopathy: Balancing the response to loading. *Nat. Rev. Rheumatol.* **2010**, *6*, 262–268. [CrossRef]
31. Heinemeier, K.M.; Kjaer, M. In vivo investigation of tendon responses to mechanical loading. *J. Musculoskelet. Neuronal Interact.* **2011**, *11*, 115–123. [PubMed]
32. Banes, A.J.; Tsuzaki, M.; Yamamoto, J.; Brigman, B.; Fischer, T.; Brown, T.; Miller, L. Mechanoreception at the cellular level: The detection, interpretation and diversity of response to mechanical signals. *Biochem. Cell Biol.* **1995**, *73*, 349–365. [CrossRef] [PubMed]
33. Lavagnino, M.; Arnoczky, S.P.; Tian, T.; Vaupel, Z. Effect of amplitude and frequency of cyclic tensile strain on the inhibition of MMP-1 mRNA expression in tendon cells: An in vitro study. *Connect. Tissue Res.* **2003**, *44*, 181–187. [CrossRef] [PubMed]
34. Screen, H.R.; Shelton, J.C.; Bader, D.L.; Lee, D.A. Cyclic tensile strain upregulates collagen synthesis in isolated tendon fascicles. *Biochem. Biophys. Res. Commun.* **2005**, *336*, 424–429. [CrossRef]
35. Langberg, H.; Rosendal, L.; Kjaer, M. Training-induced changes in peritendinous type I collagen turnover determined by microdialysis in humans. *J. Physiol.* **2001**, *534*, 297–302. [CrossRef]
36. Arnoczky, S.P.; Tian, T.; Lavagnino, M.; Gardner, K. Ex vivo static tensile loading inhibits MMP-1 expression in rat tail tendon cells through a cytoskeletally based mechanotransduction mechanism. *J. Orthop. Res.* **2004**, *22*, 328–333. [CrossRef]
37. Discher, D.E. Tissue cells feel and respon to the stiffness of their substrate. *Science* **2005**, *310*, 1139–1143. [CrossRef]
38. Martino, F.; Perestrelo, A.R.; Vinarský, V.; Pagliari, S.; Forte, G. Cellular mechanotransduction: From tension to function. *Front. Physiol.* **2018**, *9*, 824. [CrossRef]
39. Silver, F.H.; Christiansen, D.; Snowhill, P.B.; Chen, Y.; Landis, W.J. The role of mineral in the storage of elastic energy in turkey tendons. *Biomacromolecules* **2000**, *1*, 180–185. [CrossRef]
40. Walker, L.C.; Overstreet, M.A.; Yeowell, H.N. Tissue-specific expression and regulation of the alternatively-spliced forms of lysyl hydroxylase 2 (LH2) in human kidney cells and skin fibroblasts. *Matrix. Biol.* **2005**, *23*, 515–523. [CrossRef]
41. Sakai, T.; Gross, J. Some properties of the products of reaction of tadpole collagenase with collagen. *Biochemistry* **1967**, *6*, 518–528. [CrossRef] [PubMed]
42. Woessner, F.J. Matrix metalloproteinases and their inhibitors in connective tissue remodelling. *FASEB J.* **1991**, *5*, 2145–2154. [CrossRef] [PubMed]

43. Brew, K.; Dinakarpandian, D.; Nagase, H. Tissue inhibitors of metalloproteinases: Evolution, structure and function. *Biochim. Biophys. Acta* **2001**, *1477*, 267–283. [CrossRef]
44. Murphy, G.; Willenbrock, F.; Crabbe, T.; O'Shea, M.; Ward, R.; Atkinson, S.; O'Connell, J.; Docherty, A. Regulation of matrix metalloproteinase activity. *Ann. N. Y. Acad. Sci.* **1994**, *732*, 31–41. [CrossRef] [PubMed]
45. Burridge, K.; Guilluy, C. Focal adhesions, stress fibers and mechanical tension. *Exp. Cell Res.* **2016**, *343*, 14–20. [CrossRef] [PubMed]
46. Wang, J.H.; Guo, Q.; Li, B. Tendon biomechanics and mechanobiology-a minireview of basic concepts and recent advancements. *J. Hand Ther.* **2012**, *25*, 133–140. [CrossRef]
47. Jones, M.E.; Mudera, V.; Brown, R.A.; Cambrey, A.D.; Grobbelaar, A.O.; McGrouther, D.A. The early surface cell response to flexor tendon injury. *J. Hand Surg. Am.* **2003**, *28*, 221–230. [CrossRef]
48. Reed, M.J.; Ferara, N.S.; Vernon, R.B. Impaired migration, integrin function, and actin cytoskeletal organization in dermal fibroblasts from a subset of aged human donors. *Mech. Ageing Dev.* **2001**, *122*, 1203–1220. [CrossRef]
49. Pesqueira, T.; Costa-Almeida, R.; Gomes, M.E. Uncovering the effect of low-frequency static magnetic field on tendon-derived cells: From mechanosensing to tenogenesis. *Sci. Rep.* **2017**, *7*, 10948. [CrossRef]
50. Spanjaard, E.; de Rooij, J. Mechanotransduction: Vinculin provides stability when tension rises. *Curr. Biol.* **2013**, *23*, R159–R161. [CrossRef] [PubMed]
51. Totaro, A.; Panciera, T.; Piccolo, S. YAP/TAZ upstream signals and downstream responses. *Nat. Cell Biol.* **2018**, *20*, 888–899. [CrossRef] [PubMed]
52. Low, B.C.; Qiurong Pan, C.; Shivashankar, G.V.; Bershadsky, A.; Sudol, M.; Sheetz, M. YAP/TAZ as mechanosensors and mechanotransducers in regulating organ size and tumor growth. *FEBS Lett.* **2014**, *588*, 2663–2670. [CrossRef] [PubMed]
53. Dupont, S.; Morsut, L.; Aragona, M.; Enzo, E.; Giulitti, S.; Cordenonsi, M.; Zanconato, F.; Le Digabel, J.; Forcato, M.; Bicciato, S.; et al. Role of YAP/TAZ in mechanotransduction. *Nature* **2011**, *474*, 179–183. [CrossRef] [PubMed]
54. Halder, G.; Dupont, S.; Piccolo, S. Transduction of mechanical and cytoskeletal cues by YAP and TAZ. *Nat. Rev. Mol. Cell Biol.* **2012**, *13*, 591–600. [CrossRef]
55. Schroeder, M.C.; Halder, G. Regulation of the Hippo pathway by cell architecture and mechanical signals. *Semin. Cell Dev. Biol.* **2012**, *23*, 803–811. [CrossRef]

Publisher's Note: MDPI stays neutral with regard to jurisdictional claims in published maps and institutional affiliations.

© 2020 by the authors. Licensee MDPI, Basel, Switzerland. This article is an open access article distributed under the terms and conditions of the Creative Commons Attribution (CC BY) license (http://creativecommons.org/licenses/by/4.0/).